



Effect of Tramadol on Reproductive Parameters in Male Wistar Rats

Oyedeji K. O.*

Department of Physiology, College of Medicine and Health Sciences, Afe Babalola University, Ado-Ekiti, Nigeria.

*Corresponding author's E-mail: sinaoyedeji@yahoo.com

Received: 01-03-2020; Revised: 20-05-2020; Accepted: 28-05-2020.

ABSTRACT

This study was designed to investigate the effect of tramadol on reproductive parameters in male Wistar rats. Twelve male Wistar rats (120 - 140 g) were divided into control (distilled water) and tramadol-treated (0.71 mg/kg) groups (6 per group) for hormonal assay, andrological and histopathological studies. The animals were orally treated on daily basis for 50 days. Plasma testosterone level was assayed using Enzyme-linked Immuno-sorbent Assay (ELISA) and semen analysis was done microscopically. Histology of testes was also done. Data were analyzed using descriptive statistics and student's t-test at $p=0.05$. Treatment of rats with tramadol (0.71 mg/kg) caused no significant ($p>0.05$) change in testosterone level relative to control. Treatment of rats with tramadol (0.71 mg/kg) caused significant ($p<0.05$) reductions in progressive sperm motility and sperm count relative to their respective controls. It can therefore be concluded that tramadol probably has deleterious effect on the reproductive function in male rats.

Keywords: Tramadol, Rats, Sperm count, Sperm motility, Testosterone.

INTRODUCTION

Tramadol is a synthetic opioid drug that has a dual mechanism of analgesic action as a serotonin and norepinephrine reuptake inhibitor and a mu-opioid receptor agonist.¹ It is widely used as an analgesic for the treatment of postoperative, cancer, or chronic neuropathic pain.² Nowadays, this opioid drug has become one of the most widely prescribed drugs in the world.³ However; studies have shown that long-term use of the opioids is associated with addiction physical and psychological dependence.⁴

Despite its therapeutic effects, tramadol also has harmful effects on various organs. This opioid drug has hepatotoxicity and nephrotoxicity effects and can cause liver and kidney damages.⁵ Tramadol is a lipophilic opioid which, due to freely crossing the placenta, causes withdrawal syndrome in neonatal.⁶ The effects of its neurotoxicity have been proven and continuous administration of tramadol resulted in weight loss of rats' brain.³ Some studies have also demonstrated that tramadol administration impairs memory function in rodent models by activation of μ -opioid receptors.^{7, 8} On the other hand, chronic administration of tramadol cause histological abnormalities such as increasing apoptosis in rat cerebral cortex associated with oxidative stress.⁴ It has been reported that tramadol can induce seizures in patients.⁹ Other studies have shown that tramadol leads to increasing oxidative stress in various tissues such as the brain.¹⁰ Tramadol has also been observed to decrease the expression of some genes in the hippocampus.¹¹

However, due to scanty information from literature on the effect of tramadol on reproductive parameters in male rats, this study therefore aims at investigating the

effect of this analgesic on these aforementioned parameters in male rats.

MATERIALS AND METHODS

Experimental Animals

Adult male rats weighing between 120 – 140 g bred in the Pre-Clinical Animal House of the College of Medicine and Health Sciences, Afe Babalola University were used. They were housed under standard laboratory conditions and had free access to feed and water; they were acclimatized for two weeks to laboratory conditions before the commencement of the experiments. All experiments were carried out in compliance with the recommendations of Afe Babalola University Ethics Committee on guiding principles on care and use of animals.

Drug

Tramadol tablets (Ecomed Pharma Ltd., Nigeria) were bought from Danax Pharmacy, Ibadan, Nigeria.

Tramadol (50 mg) was dissolved in 10 mL of distilled water to give a concentration of 5.0 mg/mL.

The dosage of tramadol used in this study was in accordance with that reported by the manufacturer.

Body Weight

Body weight was monitored on weekly basis throughout the duration of the experiment for each rat.

Experimental Design

Twelve male rats (120 – 140 g) were randomly divided into two groups, with each group consisting of six animals. The two groups were subjected to the following oral treatments once a day for fifty (50) days:



Group I: received 0.5 mL/100 g of distilled water as control group.

Group II: received 0.71 mg/kg of tramadol.

Collection of Blood Samples

Twenty four hours (day 51) after the last dosing of the groups, blood samples were collected from all the animals through the medial cantus for the determination of plasma testosterone levels. All the animals were later sacrificed by an overdose of diethyl ether and the testes were removed along with the epididymides for semen analysis.

Hormonal Assay

Plasma samples were assayed for testosterone using the enzyme-linked immunosorbent assay (ELISA) technique using the Fortress kit.

Semen Collection

The testes were removed along with the epididymides. The caudal epididymides were separated from the testes, blotted with filter papers and lacerated to collect the semen.

Semen Analysis

Progressive sperm motility

This was done immediately after the semen collection. Semen was squeezed from the caudal epididymis onto a pre-warmed microscope slide (27°C) and two drops of warm 2.9% sodium citrate was added, the slide was then covered with a warm cover slip and examined under the microscope using x400 magnification. Ten fields of the microscope were randomly selected and the sperm motility of 10 sperms was assessed on each field. Therefore, the motility of 100 sperms was assessed randomly. Sperms were labelled as motile, sluggish, or immotile. The percentage of motile sperms was defined as the number of motile sperms divided by the total number of counted sperms (i.e. 100).¹²

Sperm viability (Life/dead ratio)

This was done by adding two drops of warm Eosin/Nigrosin stain to the semen on a pre-warmed slide, a uniform smear was then made and dried with air; the stained slide was immediately examined under the microscope using x400 magnification. The live sperm cells were unstained while the dead sperm cells absorbed the stain. The stained and unstained sperm were counted and the percentage was calculated.¹³

Sperm morphology

This was done by adding two drops of warm Walls and Ewas stain (Eosin/ Nigrosin stain can also be used) to the semen on a pre-warmed slide, a uniform smear was then made and air-dried; the stained slide was immediately examined under the microscope using x400 magnification.¹³ Five fields of the microscope were randomly selected and the types and number of

abnormal spermatozoa were evaluated from the total number of spermatozoa in the five fields; the number of abnormal spermatozoa was expressed as a percentage of the total number of spermatozoa.

Sperm count

This was done by removing the caudal epididymis from the right testes and blotted with filter paper. The caudal epididymis was immersed in 5 mL formol-saline in a graduated test-tube and the volume of fluid displaced was taken as the volume of the epididymis. The caudal epididymis and the 5 mL formol-saline were then poured into a mortar and homogenized into a suspension from which the sperm count was carried out using the improved Neubauer haemocytometer under the microscope.

Testicular Histology

After removing the testes, they were immediately fixed in Bouin's fluid for 12 hours and the Bouin's fixative was washed from the samples with 70 % alcohol. The tissues were then cut in slabs of about 0.5cm transversely and were dehydrated by passing through different grades of alcohol: 70 % alcohol for 2 hours, 95 % alcohol for 2 hours, 100 % alcohol for 2 hours, 100 % alcohol for 2 hours and finally 100 % alcohol for 2 hours. The tissues were then cleared to remove the alcohol, the clearing was done for 6 hours using xylene. The tissues were then infiltrated in molten Paraffin wax for 2 hours in an oven at 57°C, thereafter the tissues were embedded. Serial sections were cut using rotary microtome at 5 microns (5µm). The satisfactory ribbons were picked up from a water bath (50°-55°C) with microscope slides that had been coated on one side with egg albumin as an adhesive and the slides were dried in an oven. Each section was deparaffinized in xylene for 1 minute before immersed in absolute alcohol for 1 minute and later in descending grades of alcohol for about 30 seconds each to hydrate it. The slides were then rinsed in water and immersed in alcoholic solution of hematoxylin for about 18 minutes. The slides were rinsed in water, then differentiated in 1% acid alcohol and then put inside a running tap water to blue and then counterstained in alcoholic eosin for 30 seconds and rinsed in water for a few seconds, before being immersed in 70 %, 90 % and twice in absolute alcohol for 30 seconds each to dehydrate the preparations. The preparations were cleared of alcohol by dipping them in xylene for 1 minute. Each slide was then cleaned, blotted and mounted with DPX and cover slip, and examined under the microscope. Photomicrographs were taken at x40, x100 and x400 magnifications

Statistical Analyses

The mean and standard error of mean (S.E.M.) were calculated for all values. Comparison between the control and the treated group was done using student's t-test. Differences were considered statistically significant at $p < 0.05$.



RESULTS

Effect on Body weight

Treatment of rats for fifty days with tramadol (0.71 mg/kg) produced significant ($p < 0.05$) reduction in body weight on the 45th day of treatment relative to the control (Figure1).

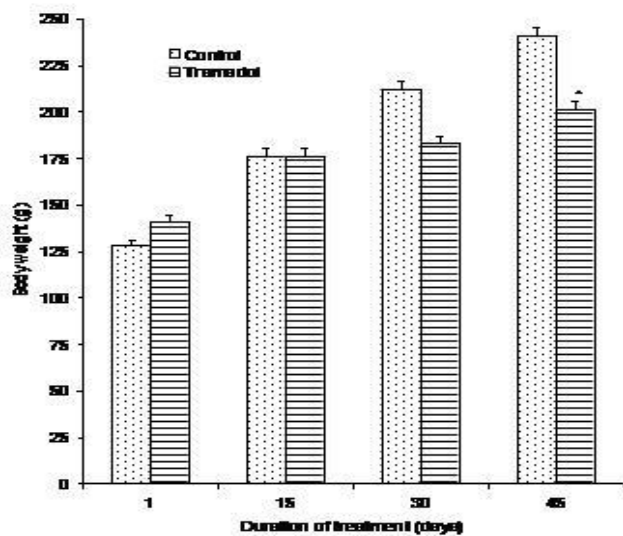


Figure 1: Body weight changes in control rats and rats treated with tramadol for 50 days ($n=6$, $*p < 0.05$)

Effect on Plasma Testosterone Level

Treatment of rats for fifty days with tramadol (0.71 mg/kg) produced no significant ($p > 0.05$) change in testosterone level relative to control (Figure 2).

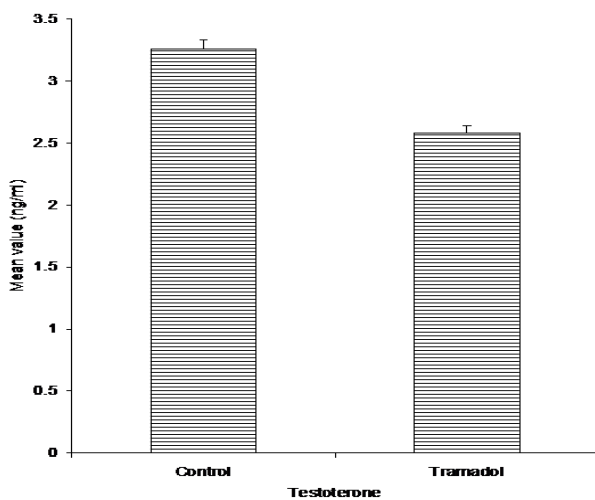


Figure 2: Effect of treatment of rats for 50 days with tramadol on plasma testosterone level ($n=6$, $*p < 0.5$)

Effect on Sperm Characteristics

The effect of 50 days treatment of rats with tramadol (0.71 mg/kg) on sperm characteristics are shown in Figures 3 and 4.

Treatment of rats with tramadol (0.71 mg/kg) for 50 days caused significant ($p < 0.05$) reduction in progressive

sperm motility as well as produced insignificant ($p > 0.05$) and significant ($p < 0.05$) reduction and increment respectively in the percentages of viable sperm cells and abnormal sperm cells relative to their respective controls. Tramadol (0.71 mg/kg) also caused significant ($p < 0.05$) reduction in sperm count relative to the control.

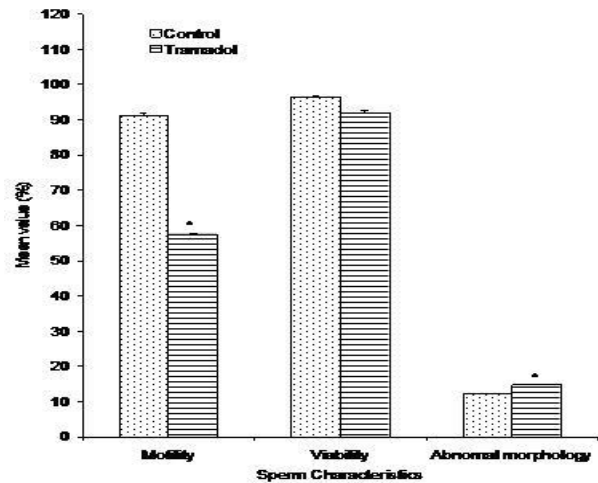


Figure 3: Spermogram showing the effect of 50 days treatment of rats with tramadol on sperm characteristics ($n=6$, $*p < 0.05$)

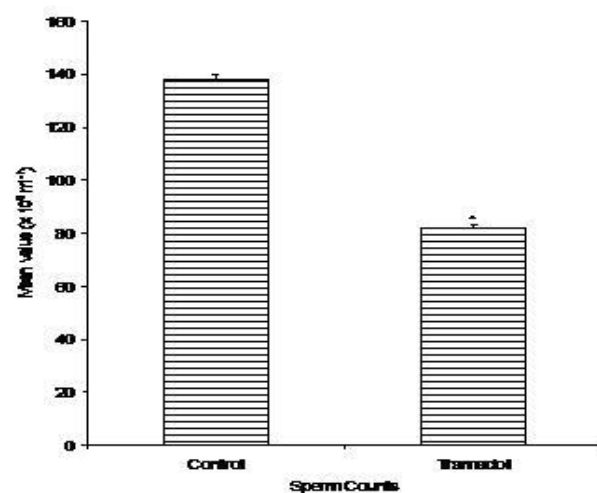


Figure 4: Spermogram showing the effect of 50 days treatment of rats with tramadol on sperm count ($n=6$, $*p < 0.05$)

Histopathological Effect

Figures 5 and 6 respectively show the transverse sections through the testes of control rat and rat treated with tramadol (0.71 mg/kg) for fifty days.

Treatment of rats with tramadol (0.71 mg/kg) caused no visible lesion in the testes of rats, which is similar to what was observed in the control rats.

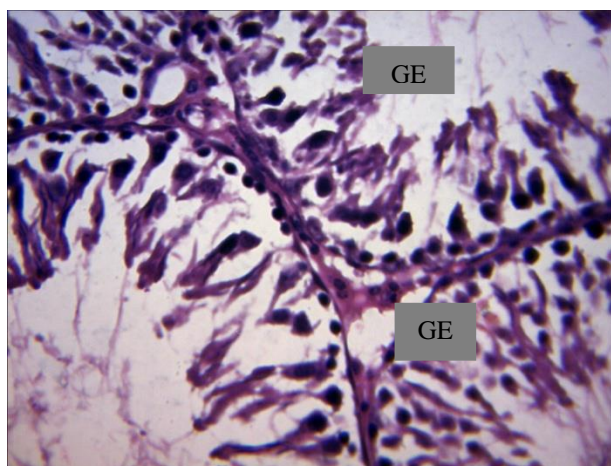


Figure 5: Effect of 50 days treatment of rat with distilled water (control) on rat's testis (x400).

Photomicrograph showing normal viable germinal epithelium (GE) with no visible lesion seen.

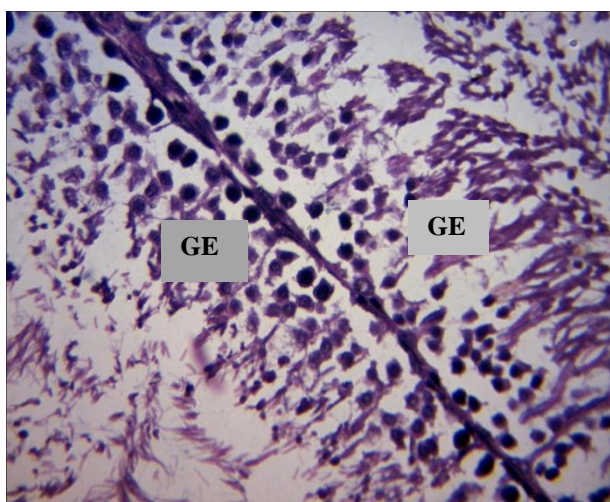


Figure 6: Effect of 50 days treatment of rat with tramadol (0.71 mg/kg) on rat's testis (x400).

Photomicrograph showing normal viable germinal epithelium (GE) with no visible lesion seen.

DISCUSSION

This study has shown that the treatment of rats with tramadol caused significant reduction in body weight of rats at a later stage during the treatment period. This suggests that tramadol increases the catabolism of lipids in the adipose tissue, resulting in significant reduction in body weight of rats at a later stage during the treatment period. Similar results were reported by¹⁴ in *Persea americana* leaf extracts treated rats.

The drug caused no significant change in testosterone level. This probably indicates that tramadol has no effect on the hypothalamus-pituitary-gonadal axis, since it has been reported that hypothalamus-pituitary-gonadal axis increases Leydig cell numbers and stimulates their testosterone production through up-regulating LH.¹⁵ Contrary report was given by¹⁶ in rats treated with *Fumaria parviflora* leaf extract.

Tramadol caused significant reduction in sperm motility. This suggest that the drug has an inhibitory effect on fertilizing capacity, since it has been reported that sperm motility is of importance with regard to sperm fertilizing capacity.¹⁷ Similar report was given by¹⁸ in rats treated with *Pueraria tuberosa* root extract.

There was no significant change in sperm viability after treatment of rats with tramadol, which probably indicates that the drug has no significant effect on fertility capacity, since it has been reported that generally, fertility capacity is positively correlated to percentage live ability of the sperm cells.¹⁹ Contrary result was reported by²⁰ in isolated tetra cyclic steroid treated rats.

There was a significant increment in the percentage of morphologically abnormal sperm cells after treatment of rats with tramadol, which probably indicates that the drug has a significant inhibitory effect on fertility, since it has been reported that sperm morphology is an essential parameter that reflects the degree of normality and maturity of the sperm population in the ejaculate and correlates with fertility.²¹ Defects of the head and mid-piece have been classified as primary defects of spermatogenesis²², and arise during testicular degeneration.²³ Primary defects of spermatogenesis are more likely to be associated with decreased fertility.²² Similar result was reported by²⁴ in flavonoid *Cuscutae* treated rats.

Sperm count, motile sperm count and normal sperm morphology have been reported as indices of male fertility.²⁵ The significant reduction in sperm count induced by tramadol in the treated rats could be an indication that this drug has the potential to alter the processes of spermatogenesis by causing damage to important testicular cells such as Sertoli cells.²⁶ Similar report was given by²⁷ in *Camellia sinensis* extract treated rats.

Photomicrographs revealed that rats treated with tramadol presented with normal germinal epithelium with no visible lesion. This suggests that tramadol has no toxic effect on the exocrine function of the testes at histological level. Similar result was reported by²⁸ in rats treated with Cadmium chloride.

CONCLUSION

In conclusion, this study has shown that tramadol has spermatotoxic or antispermatogenic effect in male rats, considering these findings in animal model, it is recommended that moderation should be exercised in the consumption of this drug by those taking it for therapeutic purpose.

REFERENCES

- Xie H, Dong ZQ, MaF, Bauer WR, Wang X, Wu GC. Involvement of serotonin 2A receptors in the analgesic effect of tramadol in mono-arthritic rats. *Brain Res.* 1210, 2008, 76–83.
- KanekoK, Umehara M, Homan T, Okamoto K, Oka M, Oyama T. The analgesic effect of tramadol in animal models of neuropathic pain and fibromyalgia. *Neurosci. lett.* 562, 2014, 28–33.
- Zhuo HQ, Huang L, Huang HQ, Cai Z. Effects of chronic tramadol exposure on the zebrafish brain: a proteomic study. *J. Proteome.* 75(11), 2012, 3351–3364.
- Ghoneim FM, KhalafHA, Elsamanoudy AZ, HelalyAN. Effect of chronic usage of tramadol on motor cerebral cortex and testicular tissues of adult male albino rats and the effect of its withdrawal: histological, immunohistochemical and biochemical study. *Int. J.Clin. Exp.Pathol.* 7, 2014, 7323.
- Elkhateeb A, El Khishin I, Megahed O, Mazen F. Effect of Nigella Sativa Linn oil on tramadol-induced hepato-and nephrotoxicity in adult male albino rats. *Toxicol. Rep.* 2, 2015, 512–519.
- De Wit D, Koomen-Botman I. Neonatal abstinence syndrome after maternal use of tramadol. *Ned. Tijdschr. Geneesk.* 157, 2012, A5610–A5610.
- Hosseini-Sharifabad A, Rabbani M, Sharifzadeh M, Bagheri N. Acute and chronic tramadol administration impair spatial memory in rat. *Res. in Pharm. Sci.* 11, 2016, 49.
- Yan T, Huan X, WeiJ, Yun-cheng N, Wei-feng Q, Peng-cheng W. Effect of tramadol with different doses on the learning and memory of mice. *J. Jingtangshan Uni. (Nat'l Sci).* 3, 2011, 28.
- Boostani R, Derakhshan S. Tramadol induced seizure: A 3-year study. *Caspian J. Intern.Med.* 3(3), 2012, 484–487.
- Abdel-Zaher AO, Abdel-Rahman MS, Elwasei FM. Protective effect of Nigella Sativa oil against tramadol-induced tolerance and dependence in mice: role of nitric oxide and oxidative stress. *Neurotoxicol.* 32(6): 2011, 725–733.
- Candeletti S, Lopetus G, Cannarsa R, Cavina C, Romualdi P. Effect of prolonged treatment with the opiate tramadol on prodynorphin gene expression in rat. *CNS. J. Mol. Neurosci.* 30(3), 2006, 341–347.
- Mohammad – Reza P, Farzaneh D, Taherch TK, Zoherb P.P. The effects of hydroalcoholic extract of *Actinidia chinensis* sperm count and motility, and blood levels of estradiol and testosterone in male rats. *Achv. Iranian Med.* 8 (3), 2005, 211-216.
- Laing JA. Fertility and infertility in domestic animals. 3rd edition 1979 Bailliere Tindall, a division of Cassell Lt; 1979.
- Brai BIC, Odetola AA, Agomo PU. Effects of *Persea americana* leaf extracts on body weight and liver lipids in rats fed hyperlipidaemic diet. *Afr. J. Biotech.* 6 (8), 2007, pp. 1007-1011.
- Sharma V, Boonen J, Spiegeleer BD, Dixit VK. Androgenic and spermatogenic activity of alkylamide-rich ethanol solution extract of *Anacyclus pyrethrum* DC. *Phytother. Res.* 27, 2013, 99-106.
- Mehran D, Seyyed MS, Lotfollah K, Ayoob J. An effect of *Fumaria parviflora* leaves extract on reproductive parameters in adult male rats. *Iran J. Reprod. Med.* 11(11), 2013, 891–898.
- Aitken RJ, Best FSM, Warner P, Templeton A. A prospective study of the relationship between semen quality and fertility in cases of unexplained infertility. *J. Androl.* 5, 1984, 297–303.
- Gupta RS, Rakhi S, Aruna S, Rakesh C, Bhatnager AK, Joshi YC. Antifertility effect of *Pueraria tuberosa* root extract in male rats. *Pharm. Biol.* 42 (6), 2005, 603-609.
- Oyeyemi MO, Okediran BS. Testicular parameters and sperm morphology of chinchilla rabbit fed with different planes of soy meal. *Int. J. Morphol.* 25(1), 2007, 139-144.
- Omirinde JO, Ozegbe PC, Oyeyemi MO. Comparative evaluation of the sperm characteristics and morphology of adult Wistar rats fed either low or normal protein-energy diets and orally dosed with aqueous *Cuscuta australis* extracts. *Niger. J. Physiol. Sci.*, 29, 2014, 55 –61.
- Memon MA, Bretzlaff RN, Ott RS. Comparison of semen techniques in goats. *Theriogenol.* 26, 1986, 823-827.
- Schumacher J, Moll HD. Collection of semen. In: *A Manual of Equine Diagnostic Procedures* (Eds.: Schumacher, J. and Moll, H.D.). Teton New Media, Jackson, WY, USA. Internet Publisher: International Veterinary Information Service, Ithaca NY. Document No. A5420.1011. Year 2011.
- Bloom E. Fertility in male animals. *J. Fertil. Steril.* 1, 1950, 223-224.
- Qin DN, She BR, Shei Y, Wang JH. Effect of flavonoids *Cuscutae* on the reproductive system in male rats. *Asian J. Androl.* 2, 2000, 99-102.
- Almabhouh FA, Osman K, Siti Fatimah I, Sergey G, Gnanou J, Singh HJ. Effects of leptin on sperm count and morphology in Sprague-Dawley rats and their reversibility following a 6-week recovery period. *Andrologia.* 47, 2015, 751-758.
- Bretveld R, Brouwers M, Ebisch I, Roeleveld N. Influence of pesticides on male fertility. *Scandinav. J. Work, Environ. Health.* 2007, 13–28.
- Akinwande DV, Adeyemi JA, Olawuyi ST, Akinola BK, Adedire CO. Protective effects of *Camellia sinensis* on *Syzygium aromaticum*- or chlorpyrifos-induced reproductive toxicity in male Wistar rats. *The J. Basic and Appl. Zoo.* 80, 2019, 48.
- Uwagie-Ero EA, Nwaehujor CO, Abiaezute CN, Ocheja OB, Ekeolu OK, Asuzu IU. D-3-O-methylchiroinositol (from *Pilostigma thonningii*) ameliorates Cadmium chloride (CdCl₂)-induced toxicity in male reproduction. *J. Appl. Sci. Environ. Manage.* 22 (6), 2018, 959 –965.

Source of Support: Nil, Conflict of Interest: None.

