



Left Atrial Appendage – The Watchman Device

Saniya Sanober*, Syed Abdul Mubeen Shah Quadri, Mirza Nouman Baig, Syeda Kubra Mehdi, Sreevani Basavaraju

MRM College of Pharmacy, Ibrahimpatnam, Ranga Reddy, 501510, Telangana, India.

*Corresponding author's E-mail: articlemrm2@gmail.com

Received: 10-05-2023; Revised: 20-07-2023; Accepted: 26-07-2023; Published on: 15-08-2023.

ABSTRACT

Aim: The aim of this study was to evaluate the safety and effectiveness of LAA closure in nonvalvular AF patients who were ineligible for warfarin medication. Atrial fibrillation (AF) is the most frequently encountered cardiac arrhythmia. It is the main cardiac cause to stroke. Despite the possibility that atrial fibrillation is a lifelong condition, a number of therapies and risk-reduction measures have been developed. Warfarin has been shown to have the ability to decrease systemic Embolization in AF patients, but its usage is challenging due to its limited therapeutic window and more side effects (such as a higher probability of bleeding), particularly in older patients. As a result, these individuals need other forms of therapy in order to lower their risk of stroke. In patients with non-valvular AF, the left atrial appendage is the primary source of thrombus development. The permanent implant known as the WATCHMAN Device is intended to block the left atrial appendage in the heart in an effort to lower the risk of stroke.

Conclusion: LAA closure with the watchman device can be successfully operated without a warfarin transition and is a reasonable alternative for the patients at high risk for stroke contraindicated to systemic oral anticoagulants.

Keywords: Atrial fibrillation, WATCHMAN Device, Left atrial appendage closure.

INTRODUCTION

Atrial fibrillation (A-fib) is a heart rhythm disorder and is an irregular rapid heartbeat that can cause blood clots in the heart. A-fib increases the risk of heart problems such as heart failure and stroke. The coordinated contraction of the right and left atria is lost in atrial fibrillation, resulting in an irregular heartbeat (pulse)¹.

Patients may have symptoms from atrial fibrillation such as fatigue, dizziness, shortness of breath, or a fluttering sensation in chest (palpitations). Despite having atrial fibrillation, the drugs often enable patients to feel good and be able to carry out routine activities. However, some patients with atrial fibrillation still experience symptoms despite taking the medications, necessitating the use of additional medications or specialized heart procedures (such as cardio version and ablation) in an effort to completely halt atrial fibrillation and maintain a normal heart rhythm. The blood flow within the atria can be slower than usual since the right and left atria no longer contract regularly when a patient has atrial fibrillation. Blood clots could develop as a result of this alteration in blood flow². Most blood clots that originate in the heart during atrial fibrillation form in the left atrial appendage, a pouch-like structure that is a component of the left atrium. AFib patients may require a blood-thinning drug, such as warfarin, apixaban, rivaroxaban, or another form of anticoagulant, to lower this risk^{3,4}.

EPIDEMIOLOGY:

Globally, both the incidence and prevalence of AF are rising. According to data from the FHS (Framingham Heart Study), the prevalence of AF has tripled over the past 50

years. Around 46.3 million people were predicted to have AF worldwide in 2016 according to the Global Burden of Disease research. In 2004, the estimated lifetime risk of AF was 1 in 4 for white men and women over 40; ten years later, the projections were 1 in 3 for white people and 1 in 5 for black people⁵.

LEFT ATRIAL APPENDAGE:

Similar to the appendix, the LAA is an obsolete bodily organ. It is the last remaining piece of the primordial left atrium, which forms between the third and sixth week of fetal cardiac development⁶. In contrast, the smooth left atrial cavity forms subsequently from the pulmonary venous bud.

Specialized endothelial cells in the left atrium and the LAA are involved in the synthesis and release of the natriuretic peptides ANP and B-type natriuretic peptide (BNP). ANP appears to be primarily produced in the LAA of the human heart, and the granulocytes there retain around 30% of the cardiac ANP that is secreted in response to atrial stretch receptors. The LAA, which serves as a decompression chamber in patients with elevated LA pressure and volume, also serves as a reservoir and is the most extensible structure in the left atrium⁷⁻⁹. The LAA undergoes remodeling in AF patients, which makes it act as a static pouch with lower Doppler flow velocities and less distensibility, which increases the risk of thrombus formation. Even in the absence of AF, patients with dilated cardiomyopathy experience similar alterations, including higher filling pressures and decreased LAA contractile performance.



WATCHMAN DEVICE:

The WATCHMAN implant is structured like a parachute and around the size of a quarter¹⁰⁻¹¹. It is inserted into the heart

to seal off the left atrial appendage (LAA), a blind pouch of heart tissue, in order to stop blood clots from developing and causing stroke.

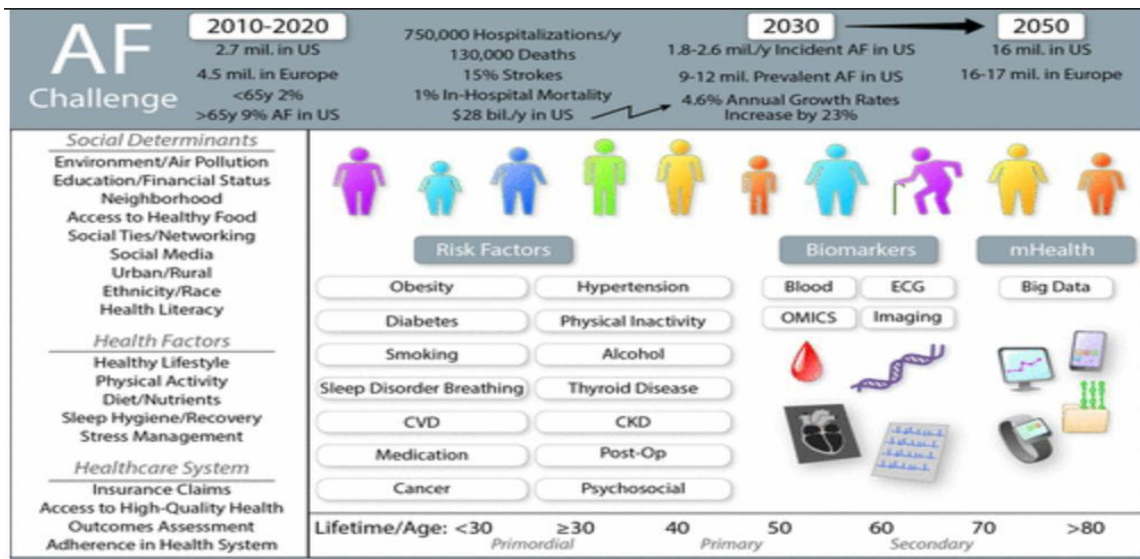


Figure 1: Challenges in atrial fibrillation (AF) epidemiology

[Source: <https://www.ahajournals.org/doi/10.1161/CIRCRESAHA.120.316340>]

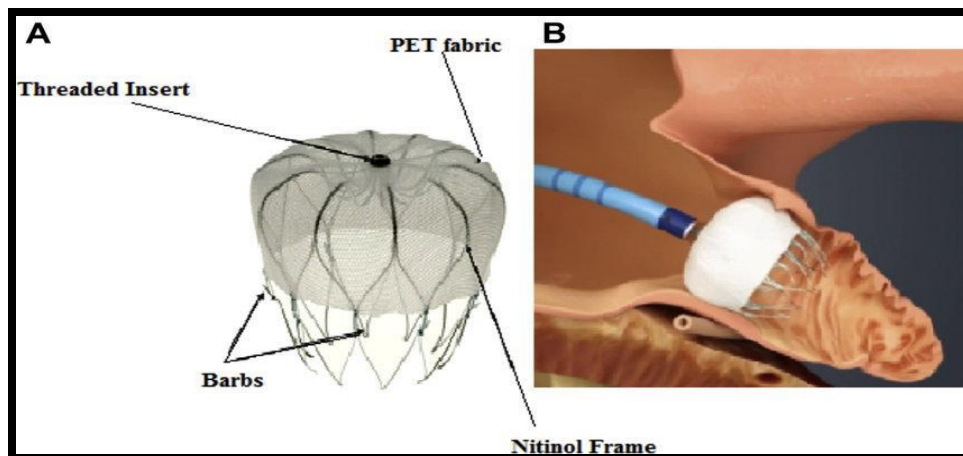


Figure 2: Structure of watchman implant

[Source: https://www.researchgate.net/figure/WATCHMAN-device-A-Structure-B-Inside-left-atrial-appendage-PET_fig1_323770306]

Three key parts make up the Watchman device: the Watchman access system, delivery system, and LAAC gadget. The Nitinol (nickel/titanium alloy) frame structure of the WATCHMAN LAAC device has ten fixation anchors, and the device cover is made of polyethylene terephthalate fabric, which serves as a protective filter. Depending on the size of LAA, size of the device is chosen. There are five sizes of the device: 21, 24, 27, 30, and 33 mm¹²⁻¹⁴. There are two types of curves in the WATCHMAN Transseptal Access system: single curve and double curve. When all requirements for device release are satisfied, the WATCHMAN device is preloaded into the 12F delivery catheter and ready to be released inside the LAA. To match the precise size of the Watchman gadget, the LAA must be measured before implantation.

Patients Who Should Not be Considered for Implantation of the WATCHMAN Implant :

- A WATCHMAN Implant should not be given to an atrial fibrillation patient until the blood clot has been effectively treated with blood thinning therapy.
- The WATCHMAN Implant should not be given to patients who have received an atrial septal repair or closure device.
- Other patients who should not receive the implant include:
- Individuals whose left atrial appendage is too wide or too tiny to fit the WATCHMAN Implant.
- Those patients who cannot take clopidogrel, aspirin, or warfarin.

- Those patients who should not or cannot have cardiac catheterization procedures
- People who are sensitive or allergic to any of the other components of the WATCHMAN implant, including Nitinol (nickel and titanium).

Patients should not be considered for the WATCHMAN Implant if they are doing well and expect to continue with anticoagulant drugs due to the danger of undergoing an invasive heart procedure in people whose left atrial appendage is too broad or too narrow to fit the WATCHMAN Implant.

A WATCHMAN Implant is generally not recommended for patients for whom the danger of the implantation

operation is anticipated to be greater than the benefit from obtaining the implant. Patients whose atrial fibrillation is due to severe heart valve problems are not advised to get the WATCHMAN Implant.

IMPLANTATION PROCEDURE:

The WATCHMAN Left Atrial Appendage Closure Device is inserted at the left atrial appendage's entrance with the goal of preventing blood clots from the left atrial appendage from entering the bloodstream and perhaps leading to stroke. It is constructed with components that are used in numerous medical devices. The implant is intended to be a one-time procedure that never requires replacement.

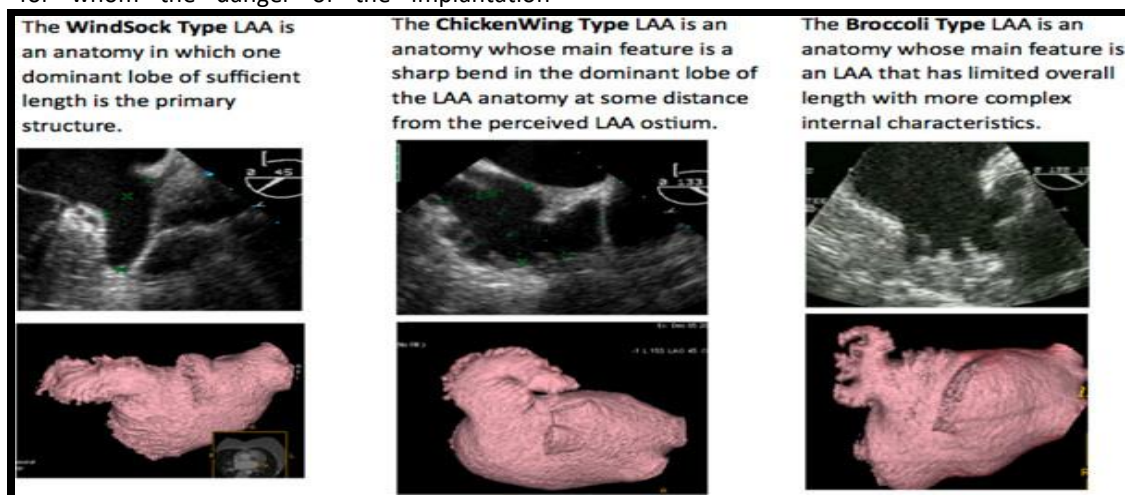


Figure 3: LAA Typing. (Left) The WindSock Type LAA is an anatomy in which one dominant lobe of sufficient length is the primary structure. (Centre) The Chicken Wing Type LAA is an anatomy whose main feature is a sharp bend in the dominant lobe of the LAA anatomy at some distance from the perceived LAA ostium. (Right) The Broccoli Type LAA is an anatomy whose main feature is an LAA that has limited overall length with more complex internal characteristics.

[Source: https://www.researchgate.net/figure/WATCHMAN-device-A-Structure-B-Inside-left-atrial-appendage-PET_fig1_323770306]

1. TEE-Based Determination of WATCHMAN Device Size:

- A transesophageal echocardiography (TEE) is done before the procedure to make sure there are no thrombi in the LAA and to identify the right size WATCHMAN device to be implanted. To carry out the implantation process, the advised international normalized ratio should be less than 1.5.
- Put the patient under a 2 to 5 mg dose of midazolam for conscious sedation before inserting the ultrasonography probe into the esophagus
- Verify that there is no LA/LAA thrombus.
- Examine the following LAA characteristics: pectinate characteristics, ostium size and form, number of lobes, position, and working length. To suit the available WATCHMAN device sizes, the maximum LAA ostium size should be >17mm or 31mm.
- Measure the LAA ostium in at least four different TEE perspectives to perform implantation. The left upper pulmonary vein limbus is 2 cm away from the ostium at 0 degrees from the left coronary artery. After that, measure it at 45, 90, and 135 degrees from the mitral valve annulus's top to a position 2 cm from the left upper pulmonary vein's (LUPV) limbus.
- From the ostium line to the LAA's apex, measure the approximate length of the LAA that can be used. The length of the LAA implant that can be used or made available should be at least as long as the maximum measurement of LAA.
- Identify the LAA type to help in planning the approach. The majority of LAAs can be classified as "WindSock Type," "Chicken Wing Type," or "Broccoli Type."¹⁵ The LAA form's classification allows one to estimate how challenging the implantation process will be.
- The fundamental structure of the WindSock Type LAA is one dominating lobe that is long enough. Majority of these cases involve relatively simple implantation procedures.

- The dominant lobe of the LAA anatomy has a strong bend in it that is located at some distance from the perceived LAA ostium, defining the Chicken Wing Type LAA anatomy.
- The implant process is simple if the longest portion of the implant is longer than its widest diameter. The technique could be challenging if the proximal portion is smaller than the LAA orifice's maximal width.

The LAA of the Broccoli Type is an anatomy distinguished by its short overall length and complicated internal properties. Since there are multiple lobes to cover and the length of the LAA is constrained when this anatomy is present, the device is frequently challenging to implant.

2. Implantation of watchman device:

- Clean and prepare the femoral vein region for cannulation once the patient has received General anesthesia¹⁶.
- Once the femoral vein has been located, a conventional Transseptal access system's venous introducer should be inserted into the femoral vein medial to it. Once it is in position, introduce the vascular dilator and 0.035" guidewire into the femoral vein to gain access to the heart.
- A 5F sheath should then be inserted into the femoral vein. Put a pigtail catheter in the aortic root to serve as a marker and to monitor the pressure.
- Transseptal sheath and needle should be advanced into the upper vena cava cautiously observing the central venous pressure. After that, pull back the sheath with the needle until the TEE shows a tenting of the needle on the atrial septum.
- Determine the mid to lower portion of the posterior septum using TEE which shall be the best location for Transseptal crossing. Before moving the needle and sheath into the left atrium and the sheath into the upper pulmonary vein, recheck the position under fluoroscopy using the lateral view.
- Transseptal access system is removed, leaving a 0.0035" stiff guidewire (such as Amplatz Super stiff 260 cm) in the left upper pulmonary vein.
- To achieve an active clotting time (ACT) of 200–300 seconds, provide 100 IU/kg of heparin. As needed, check the ACT level every 30 minutes.
- Remove the WATCHMAN Access System and dilator from the box while maintaining sterility, then checks the complete system for damage.
- Insert a syringe filled with saline into the WATCHMAN access sheath's side port. Saline should be flushed through the unit. Remove the syringe from the side port and insert it into the dilator's end, flushing it with the remaining saline.
- Next, introduce the WATCHMAN access sheath and dilator through the guidewire into the left atrium and remove the dilator while keeping the sheath in place in the LUPV.
- Flush the pigtail catheter through the WATCHMAN access sheath and over the wire. Remove the guidewire and attach a syringe containing contrast dye to the pigtail.
- Allow bleed-back before tightening the valve on the access sheath to reduce the possibility of introducing air within the sheath.
- Pull the sheath with the pigtail catheter back from the LUPV and turn it anticlockwise until it reaches the LAA under ECG supervision. It should be noted that turning the access system anticlockwise aligns the sheath more anteriorly. Tightening the access system clockwise aligns the sheath more posteriorly.
- Once the pigtail catheter has reached the LAA, perform an angiography with a right anterior oblique (RAO) of 20-30° and a caudal RAO of 20-30°.
- TEE should be performed with a minimum 0–135 degree sweep. This is particularly significant when the sheath is advanced distally in any anatomy, close to the wall or apex of the LAA, or both.
- Carefully move the catheter/sheath in the most right lobe in TEE 135° and the most superior lobe in angiography approximately 2 o'clock.
- Utilizing TEE, measure the maximum LAA dimensions in 4 perspectives at 0, 45, 90, and 135° as before to confirm the dimensions.
- Under fluoroscopic guidance, insert the pigtail catheter into the distal LAA. By using the marker bands on the access sheath as a guide, slowly move the access sheath over the pigtail catheter. The most proximal marker band of the 33 mm, the middle marker of the 27 mm, or the proximal marker of the 21 mm WATCHMAN device all serve as indicators of the device's landing zone. The landing zones for the 24 mm and 30 mm devices are between markers.
- Using the TEE measurements, choose a WATCHMAN device that is the correct size^{17,18}. Then, while maintaining sterility, take the package off the correct-sized WATCHMAN device and check it for damage. To make sure the device is attached to the core wire, open the haemostatic valve and pull the device back by roughly 1 cm.
- Push the device until the distal tip is lined up with the delivery catheter after aligning the distal tip of the device with the marker band. Make sure the WATCHMAN device doesn't protrude out.
- To eliminate air fluid from the system, attach a large 60cc syringe and repeatedly flush the system with

saline. The delivery catheter's tip should next be placed in saline and tapped to remove any air bubbles.

- Recheck the location of the access sheath by angiography after the device has been prepared. The pigtail catheter should be slowly removed from the access sheath by loosening the valve. Introduce the WATCHMAN device.
- Once the device has been deployed, employ fluoroscopy and TEE to verify that the device release criteria have been satisfied which are: Position, Anchor, Size and Seal (PASS.)
- POSITION: To make sure the device was positioned correctly, check to see that its plane of greatest diameter is at or just distal to the LAA orifice and that it spans the whole LAA ostium.
- ANCHOR: Withdraw the access sheath/delivery catheter assembly 1 to 2 cm from the device's face to make sure it is firmly affixed. Release the deployment knob after gently retracting it. LAA should move simultaneously with the gadget.
- SIZE: Use TEE in the conventional 4 perspectives of 0 degrees, 45 degrees, 90 degrees, and 135 degrees to measure the maximum diameter of the device in the plane, making sure that the threaded insert is visible. It should be between 80% and 92% of its previous size.
- SEAL: Verify that all of the lobes distal to the device are sealed using Color Doppler. Near the device, there should ideally be no color flow.
- No correction is required if only a tiny space can be seen between the device and the wall of the left atrial appendage.
- The device should be adjusted or completely recaptured and replaced if there is a gap or jet larger than 5 mm.
- If all release requirements are satisfied, raise the access sheath/delivery catheter to the face of the device and release by turning the deployment knob three to five rotations counterclockwise.
- An angiography with contrast dye should be performed after release, to confirm that the device remains in position. Recheck the size and seal using TEE after the implantation procedure. From the left atrium, remove the sheath assembly.

3. Postoperative Care

- Remove the sheath once the device has been positioned correctly. It is important to achieve local hemostasis.
- According to institutional guidelines, check for hematoma and/or bleeding at regular intervals after the implantation procedure. The patient needs to be closely monitored.

- Continuously monitor blood pressure, heart rate, and oxygen saturation.
- Once the patient is conscious, a neurological examination should be done. For at least 6 hours, the patient should be under blood pressure and heart rate monitoring supervision.
- For at least 45 days after the implantation procedure (internal normalized ratio (INR) 2.0-3.0), the patient should continue taking warfarin and 81mg aspirin. According to the American Heart Association's recommendations, the patient should receive antibiotic prophylaxis. NOTICE: Heparin is not suggested after surgery.
- The patient may be hospitalized overnight and discharged the next day. A TEE is typically performed before discharge.
- Using TEE evaluation is done to assess WATCHMAN device at 45 days. If the LAA is totally closed and thrombus on the device has been ruled out, the doctor can decide to stop taking warfarin. Consideration should be given to keep the patient on warfarin until the flow around the device has dropped to less than 5 mm if it is detected to be larger than 5 mm.
- Patients who've been discontinuing warfarin should start taking 75mg of clopidogrel and aspirin daily for the first six months after getting an implant and continue doing that continuously.
- Give appropriate endocarditis prophylaxis guidance for six months after implantation. The decision to continue endocarditis prophylaxis after six months is left up to the doctor.

SUCCESS RATE OF WATCHMAN DEVICE

This procedure has emerged as a life-changing alternative for people who live with a daily risk of stroke and who want an alternative to drug treatment therapy. It has been implanted in more than 10,000 patients around the world—and it has been successful in 94.7 percent of those patients²⁰.

The WATCHMAN FLX LAAC gadget is made for improved LAA closure, which has been shown to have a 100% rate of effective LAA closure after a year.

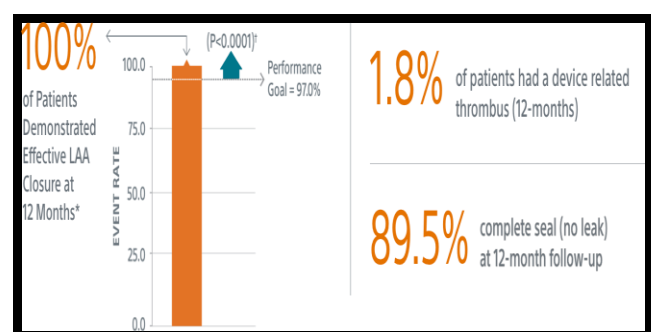


Figure 4: Statistical analysis of success rate

[Source: BOSTON SCIENTIFIC]

WARFARIN CESSATION:

WATCHMAN DEVICE enables patients to discontinue taking long term OAC²¹.

92% OF PATIENTS WERE ENABLE TO DISCONTINUE WARFARIN AFTER 45 DAYS, WITH 99% WERE able to discontinue after 1 year.

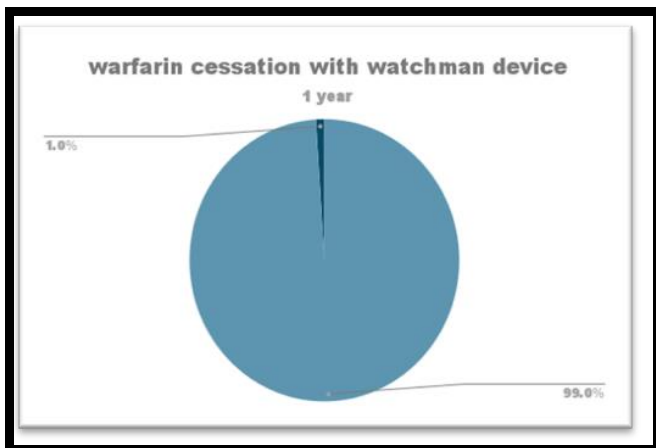


Figure 5: Warfarin cessation with implant in 1yr

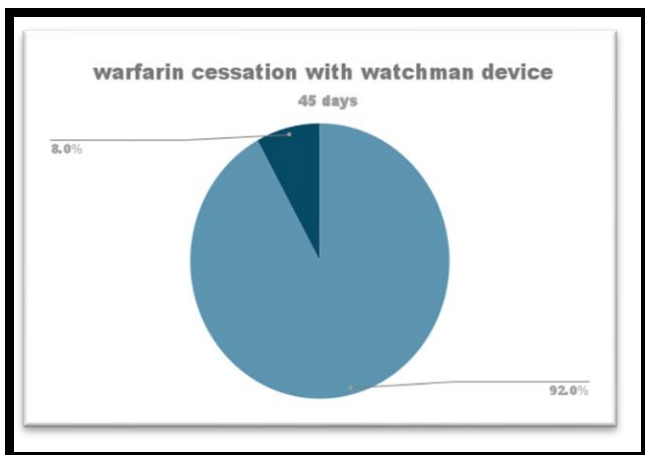


Figure 6: Warfarin cessation with implant in 45 days

Reduction in stroke:

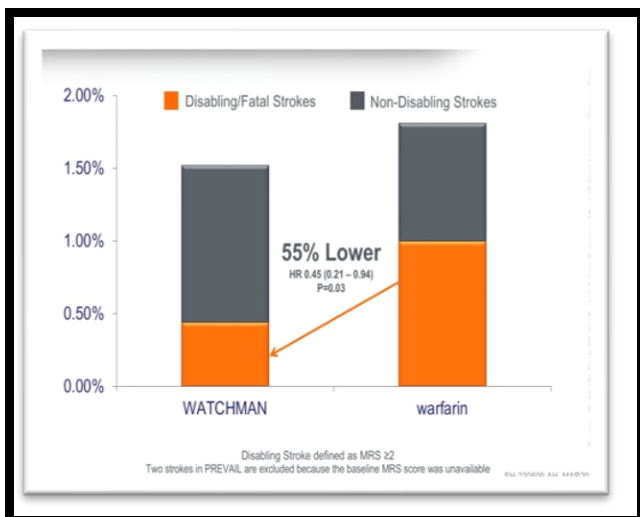


Figure 7: WATCHMAN implant VS WARFARIN

[Source: BOSTON SCIENTIFIC]

ADVERSE EVENTS:

- Air embolism (leak of air bubbles into the bloodstream which may cause damage to organs) Airway trauma (damage to your airways)-
- Allergic reaction to the contrast dye, anesthetic, WATCHMAN Implant material, or medications Altered mental status (change in mental status)-
- Anemia (thin blood) requiring transfusion-
- Anoxic encephalopathy (change in mental status from a lack of oxygen reaching the brain)
- Arrhythmias (heart rhythm abnormalities)
- Bruising, hematoma (blood collection) or seroma (fluid collection) near the catheter-
- Insertion site Cardiac perforation (perforation of the heart muscle)
- Congestive heart failure (decreased ability of your heart to pump blood)-
- Contrast-related nephropathy (kidney damage from contrast dye)-
- Decreased hemoglobin (lack of red blood cells in your blood)
- Device Embolization (implant moves from the intended location)-
- Device fracture (damage to the WATCHMAN Implant)-
- Device thrombosis (clot on the implant)-
- Excessive bleeding-
- Groin pain-
- Groin puncture bleed.
- Hemoptysis (blood in the sputum)-
- Hypotension (low blood pressure)-
- Hypoxia (low oxygen level in the bloodstream)-
- Improper wound healing-
- Inability to reposition, recapture, or retrieve .
- Interatrial septum thrombus (blood clot on wall between heart's upper chambers)-
- Intratracheal bleeding (bleeding in the windpipe)-
- Misplacement of the device / improper seal of the appendage / movement of the device from appendage wall Myocardial Erosion (erosion through heart wall)-
- Nausea (feeling sick)-
- Oral bleeding (bleeding from the mouth)-
- Pericardial effusion / tamponade [accidental heart puncture causing fluid collection in the heart sack (pericardial effusion) which may lead to increased

pressure in the heart sack (tamponade)] Pleural Effusion (collection of fluid around the lungs)

- Prolonged bleeding from a laceration (prolonged bleeding from a cut)
- Pseudo aneurysm (abnormal connection between your blood vessels due to the procedure) Pulmonary Edema (collection of fluid in the lung tissue)
- Renal failure (kidney failure)
- Respiratory insufficiency/failure (breathing failure)
- Stroke – Ischemic (stroke from lack of blood supply to a part of the brain) Stroke – Hemorrhagic (stroke from bleeding inside the brain) Systemic Embolism
- TEE (Transesophageal echocardiogram) complications (throat pain, bleeding, esophageal trauma) Thrombocytopenia (low platelet count)
- Thrombosis (clot formation)
- Transient Ischemic Attack (TIA) (temporary loss of body function that results from lack of blood supply to part of the brain) Valvular or vascular damage (damage to heart valve or blood vessel)
- Vasovagal Reactions (change in blood pressure and/or heart rate).

OTHER DEVICES

AMPLATZER AMULET:

A permanent implant called the Amplatzer Amulet Left Atrial Appendage Occluder (LAAO) is inserted into the patient's left atrial appendage (LAA), a pouch-like region of the heart. The goal of the device is to stop blood clots that form in the LAA from traveling to other parts of the body and perhaps inducing a stroke²⁴.



Figure 8: Amplatzer amulet

[Source: <https://www.fda.gov/medical-devices/recently-approved-devices/amplatzer-amulet-left-atrial-appendage-occluder-p200049>]

COMPARISON:

Outcomes of WATCHMAN FLX™ Device vs Amplatzer™ Amulet Occluder: A Meta-Analysis

The best comparison of peri-procedural success and short-term results between WATCHMAN FLX and Amplatzer Amulet shows that WATCHMAN FLX has better procedural safety, greater procedural success, and better LAA closure²².

- The primary safety objective was better with WATCHMAN FLX (0.6% FLX vs 4.7% Amulet, p=0.01)
- In terms of total pericardial effusion/tamponade, WATCHMAN FLX
- The primary safety objective was better with WATCHMAN FLX (0.6% FLX vs 4.7% Amulet, p=0.01)
- In terms of total pericardial effusion/tamponade, WATCHMAN FLX was safer (0.1% FLX vs. 2.5% Amulet, p=0.01).
- Clinically significant pericardial effusion/tamponade was better treated with WATCHMAN FLX (0.01% FLX vs. 0.7% Amulet, p=0.01).
- (0.1 % FLX vs. 2.3% Amulet, p=0.01) WATCHMAN FLX is superior for peri-procedural major/intracranial hemorrhage.
- With WATCHMAN FLX, there were no device Embolization compared to 15 with Amulet.
- Compared to Amulet, WATCHMAN FLX showed a lower DRT (1% vs. 1.6%).
- (Leaks >5mm; p=0.06) WATCHMAN FLX showed a tendency toward more frequent appendage occlusion. Compared to Amulet, WATCHMAN FLX showed lower peri-device leakage >5mm (0.01% vs. 0.34%, p=0.06).

BENEFITS OF WATCHMAN DEVICE²³:

- ✓ Lowers the risk of stroke by inhibiting the growth of blood clots in the left atrial appendage.
- ✓ The process is minimally invasive. There is no need to open the patient's chest.
- ✓ Compared to open surgery, recovery is frequently quicker and less difficult. One day after the procedure, most patients are discharged from the hospital.
- ✓ Within a few days to a week, the majority of people can resume their regular activities.

RISKS AND OUTCOMES:

- ✓ The left atrial appendage has relatively thin walls. The LAA may be under pressure from the apparatus. While the device is being used, there is a chance that the LAA could rupture. It would take an urgent cardiac operation to correct this potentially severe condition.

- ✓ The access site, where the catheter was put into the blood vessel leading to the heart, is susceptible to infection. Usually, the entry point is in the upper leg. To ensure optimal healing, the medical team will need to keep an eye on these locations.

CONCLUSION

Even in populations with higher risk of stroke, hemorrhage and other comorbidities, WATCHMAN DEVICE has a higher success rate in completely closing the left atrial appendage with a minimal peri-procedural risk which has increased the net clinical benefit. Despite having a higher number of safety events when compared to warfarin therapy, LAA occlusion had an improved overall result in terms of morbidity and mortality. Patients with non-valvular atrial fibrillation may therefore find closure of the left atrial appendage to be a promising and successful option to ongoing warfarin therapy.

REFERENCES

- Nattel S. New ideas about atrial fibrillation 50 years on. *Nature*. 2002 Jan 10;415(6868):219-26.
- Mitrev L, Trautman N, Vadlamudi R, Desai N, Sabir SA. Anesthesia and transesophageal echocardiography for WATCHMAN device implantation. *Journal of Cardiothoracic and Vascular Anesthesia*. 2016 Dec 1;30(6):1685-92.
- Pandya E, Bajorek BV. Assessment of Web-based education resources informing patients about stroke prevention in atrial fibrillation. *Journal of Clinical Pharmacy and Therapeutics*. 2016 Dec;41(6):667-76.
- January CT, Wann LS, Alpert JS, Calkins H, Cigarroa JE, Cleveland Jr JC, Conti JB, Ellinor PT, Ezekowitz MD, Field ME, Murray KT. 2014 AHA/ACC/HRS guideline for the management of patients with atrial fibrillation: executive summary: a report of the American College of Cardiology/American Heart Association Task Force on practice guidelines and the Heart Rhythm Society. *Circulation*. 2014 Dec 2;130(23):2071-104.
- Jelena kornej, Christin S.Borschel,Emelia J.Benjamin and Renate B. Schnabel.Epidemiology of atrial fibrillation in the 21st century.*Circulation Research* 2020;127:4-20.
- Al-Saady NM, Obel OA, Camm AJ. Left atrial appendage: structure, function, and role in thromboembolism. *Heart*. 1999 Nov 1;82(5):547-54.
- Bansal M, Kasliwal RR. Echocardiography for left atrial appendage structure and function. *Indian heart journal*. 2012 Sep;64(5):469-75.
- Donal E, Yamada H, Leclercq C, Herpin D. The left atrial appendage, a small, blind-ended structure: a review of its echocardiographic evaluation and its clinical role. *Chest*. 2005 Sep 1;128(3):1853-62.
- Ernst G, Stöllberger C, Abzieher F, Veit-Dirscherl W, Bonner E, Bibus B, Schneider B, Slany J. Morphology of the left atrial appendage. *The Anatomical Record*. 1995 Aug;242(4):553-61.
- Hornung M, Franke J, Sievert H. Left Atrial Appendage Occlusion for Preventing Stroke—Step-by-Step Technique and Current Status. *Handbook of Interventions for Structural Heart and Peripheral Vascular Disease*. 2015 Nov 30;78.
- Price MJ. Left atrial appendage occlusion: data update. *Interv Cardiol Clin*. 2018 Apr 1;7(2):159-68.
- Kanmanthareddy A, Reddy YM, Pillarisetti J, Swarup V, Lakkireddy D. LAA closure with the watchman device. *Cardiac Interventions Today*. 2013 Sep;5:35-40.
- Sanon SA, Lim DS. Update on left atrial appendage occlusion. *Cardiac interventions today*. 2019;13(4):21-26.
- Jay Mohan DO, Bradley CJ. Current and Future Strategies for Left Atrial Appendage Closure in Patients with Atrial Fibrillation: Experience at Two Centers. *EP Lab Digest*. 2023 Mar 2;23(3):33-39.
- Kuniewicz M, Budnicka K, Dusza M, Jakob N, Cholewa N, Defonseka R, Gosnell M, Wadhwa T, Walocha J, Dobrzynski H, Hołda M. Gross anatomic relationship between the human left atrial appendage and the left ventricular summit region: implications for catheter ablation of ventricular arrhythmias originating from the left ventricular summit. *Journal of Interventional Cardiac Electrophysiology*. 2023 Mar;66(2):301-10.
- Alfadhel M, Nestelberger T, Samuel R, McAlister C, Saw J. Left atrial appendage closure—Current status and future directions. *Progress in Cardiovascular Diseases*. 2021 Nov 27.
- Saw J, Fahmy P, Spencer R, Prakash R, McLaughlin P, Nicolaou S, Tsang M. Comparing measurements of CT angiography, TEE, and fluoroscopy of the left atrial appendage for percutaneous closure. *Journal of cardiovascular electrophysiology*. 2016 Apr;27(4):414-22.
- Nadeem F, Igwe C, Stoycos S, Jaswaney R, Tsushima T, Al-Kindi S, Bansal E, Fares A, Dallan L, Patel S, Rajagopalan S. A new WATCHMAN sizing algorithm utilizing cardiac CTA. *Cardiovascular Revascularization Medicine*. 2021 Dec 1;33:13-19.
- Wunderlich NC, Beigel R, Swaans MJ, Ho SY, Siegel RJ. Percutaneous interventions for left atrial appendage exclusion: options, assessment, and imaging using 2D and 3D echocardiography. *JACC: Cardiovascular Imaging*. 2015 Apr;8(4):472-88.
- Phillips KP, Kar S. WATCHMAN Device. Left Atrial Appendage Closure: Mechanical Approaches to Stroke Prevention in Atrial Fibrillation. 2016:143-68.
- Koifman E, Lipinski MJ, Escarcega RO, Didier R, Kiramijyan S, Torguson R, Waksman R. Comparison of Watchman device with new oral anticoagulants in patients with atrial fibrillation: a network meta-analysis. *International journal of cardiology*. 2016 Feb 15;205:17-22.
- Basu Ray I, Khanra D, Shah S, Char S, Jia X, Lam W, Mathuria N, Razavi M, Jain B, Lakkireddy D, Kar S. Meta-analysis comparing WatchmanTM and Amplatzer devices for stroke prevention in atrial fibrillation. *Frontiers in cardiovascular medicine*. 2020 Jun 22;7:89-94.
- Grygier M, Olasińska-Wiśniewska A, Araszkievicz A, Trojnariska O, Babicz-Sadowska A, Lesiak M. The Watchman FLX—a new device for left atrial appendage occlusion—design, potential benefits and first clinical experience. *Advances in Interventional Cardiology/Postępy w Kardiologii Interwencyjnej*. 2017 Mar 10;13(1):62-6.
- Tzikas A, Gafoor S, Meerkin D, Freixa X, Cruz-Gonzalez I, Lewalter T, Saw J, Berti S, Nielsen-Kudsk JE, Ibrahim R, Lakkireddy D. Left atrial appendage occlusion with the AMPLATZER Amulet device: an expert consensus step-by-step approach. *EuroIntervention: journal of EuroPCR in collaboration with the working group on interventional cardiology of the European society of cardiology*. 2016 Apr 1;11(13):1512-21.
- Lakkireddy D, Thaler D, Ellis CR, Swarup V, Sondergaard L, Carroll J, Gold MR, Hermiller J, Diener HC, Schmidt B, MacDonald L. Amplatzer Amulet left atrial appendage occluder versus Watchman device for stroke prophylaxis (Amulet IDE): a randomized, controlled trial. *Circulation*. 2021 Nov 9;144(19):1543-52.
- Freixa X, Aminian A, Tzikas A, Saw J, Nielsen-Kudsk JE, Ghanem A, Schmidt B, Hildick-Smith D. Left atrial appendage occlusion with the Amplatzer Amulet: update on device sizing. *Journal of Interventional Cardiac Electrophysiology*. 2020 Oct;59:71-8
- Della Rocca DG, Magnocavallo M, Gianni C, Mohanty S, Natale VN, Al-Ahmad A, Lavalle C, Horton RP, Di Biase L, Natale A. Procedural and short-term follow-up outcomes of Amplatzer Amulet occluder versus Watchman FLX device: A meta-analysis. *Heart Rhythm*. 2022 Jun 1;19(6):1017-8.



28. Patel P, Ganta N, Filice G, Richard I, Acquah F, Alnabwani D, Patel HB, Patel H. Embolic Cerebrovascular Accident Secondary to Device-Related Thrombus Post WATCHMAN Device Implantation. *Cureus*. 2022 Jul 15;14(7):80-85.
29. Zhang Y, Zhang Y, Tao L, Du T, Jia B, Zhou M, Zhang Z. Efficacy and safety of left-ear occlusion versus warfarin therapy in patients with atrial fibrillation. *Archives of Clinical Psychiatry*. 2022;49(3):18-24.
30. Pracon R, Bangalore S, Dzielinska Z, Konka M, Kepka C, Kruk M, Kaczmarek-Dyrda E, Petryka-Mazurkiewicz J, Bujak S, Solecki M, Pskit A. Device thrombosis after percutaneous left atrial appendage occlusion is related to patient and procedural characteristics but not to duration of postimplantation dual antiplatelet therapy. *Circulation: Cardiovascular Interventions*. 2018 Mar;11(3):e005997.
31. <https://heartrhythmdoc.com/arrhythmia-treatment-options/watchman-procedure/>
32. Indication, Patient Selection, and Referral Pathways for Left Atrial Appendage Closure. Scientific Figure on Research Gate. Available from: https://www.researchgate.net/figure/WATCHMAN-device-A-Structure-B-Inside-left-atrial-appendage-PET_fig1_323770306 [accessed 14 Jun, 2023]
33. <https://clinicalgate.com/left-atrial-occludersisolation/>

Source of Support: The author(s) received no financial support for the research, authorship, and/or publication of this article.

Conflict of Interest: The author(s) declared no potential conflicts of interest with respect to the research, authorship, and/or publication of this article.

For any questions related to this article, please reach us at: globalresearchonline@rediffmail.com

New manuscripts for publication can be submitted at: submit@globalresearchonline.net and submit_ijpsrr@rediffmail.com

