



## Morphological Analysis of Supra-Scapular Notch with Special Reference to Ossified Superior Transverse Scapular Ligament in Dry Human Scapulae: An Observational Study

Dibya Prabha Bara<sup>1</sup>, Smita Patra,<sup>2</sup> Biren Xalxo,<sup>3</sup> Manoj Kumar Dehury<sup>4</sup>, Dharma Niranjana Mishra<sup>5\*</sup>

1. Assistant Professor, Anatomy BB MCH Bolangir, Odisha, India, ORCID ID: <https://orcid.org/0000-0002-0642-0767>

2. Assistant Professor, Anatomy, SCB Medical College and Hospital, Cuttack, Odisha, India, ORCID ID: <https://orcid.org/0000-0003-0642-507X>

3. Assistant Professor, FMT VIMSAR Burla, Odisha, India, ORCID ID: <https://orcid.org/0009-0001-0050-1214>

4. Assistant Professor, Anatomy, SCB Medical College and Hospital, Cuttack, Odisha, India, ORCID ID: <https://orcid.org/0009-0008-2254-7900>

5. Professor, Department of Anatomy, S. C. B. Medical College, Cuttack- 753007, Odisha, India, ORCID ID: <https://orcid.org/0000-0001-9217-5235>

\*Corresponding author's E-mail: [dharmaniranjana.mishra08@gmail.com](mailto:dharmaniranjana.mishra08@gmail.com)

Received: 16-09-2023; Revised: 22-10-2023; Accepted: 30-10-2023; Published on: 15-11-2023.

### ABSTRACT

**Background:** The supra-scapular notch (SSN) is present on the upper border of the scapula. It is covered by a ligament in living, making it a tunnel for the passage of supra-scapular nerves and vessels. Sometimes it is ossified and responsible for various pathological conditions of the shoulder joint.

**Aims and Objectives:** The aim of the study is to evaluate the incidence, morphology and clinical significance of SSN and the existence of ossified STSL.

**Materials and Methods:** The present analytical cross-sectional study was conducted in the Anatomy department, SCB Medical College, Cuttack, Odisha.

**Results:** Total 291 dried human scapulae of unknown sex were observed in the study. The morphological classification was done as Type 1- absence notch, Type 2- blunted V-shape notch, Type 3- U-shaped notch, Type 4- very small V-shaped notch, Type 5 – U shape notch with partially ossified ligament and Type 6- completely ossified foramen. In the present study Type 3 was observed in maximum specimens followed by Type 1. The least common occurrence was Type 5 partially ossified SSN and Type 6 completely ossified SSN respectively. All the 3 types (4, 5 & 6) were responsible for supra-scapular nerve entrapment syndrome.

**Conclusion:** The morphology of the supra-scapular notch is considered to be a risk factor for the supra-scapular nerve entrapment syndrome.

**Keywords:** STSL, SSN, Morphology, Syndrome, Nerve entrapment.

### INTRODUCTION

The scapula or commonly known as shoulder blade is present back of the thorax extending from 2<sup>nd</sup> to 7<sup>th</sup> ribs. It connects clavicle to the humerus and forms the posterior part of the shoulder girdle. <sup>1</sup> There are 3 groups of muscles attached to scapula. The first group intrinsic muscles of the scapula are the rotator cuff muscles (supraspinatus, infraspinatus, teres minor & subscapularis) and teres major. The second extrinsic group muscles are the triceps, biceps, and deltoid. The third group of muscles is the levator scapulae, trapezius, rhomboids, and serratus anterior. These muscles are responsible for movements of the unstable shoulder joint and stabilization of the scapula to the thoracic wall. <sup>2</sup>

The suprascapular notch (SSN) is present on the superior border of the scapula medial to the coracoid process. Superior transverse scapular ligament (STSL) bridges it to form an osseous-fibrous tunnel, which sometimes ossified to a foramen for the passage of supra-scapular nerve and vessels. <sup>3</sup>

The suprascapular nerve is a mixed nerve, having both motor and sensory branches. It is primarily derived from

ventral rami of fifth and sixth cervical spinal nerves (C5, 6). Suprascapular nerve (SN) is sensory to rotator cuff muscles and motor branches to the supraspinatus and infraspinatus muscles respectively. <sup>4</sup> The sensory supply to the shoulder joint and acromioclavicular joint are also supplied by it. <sup>5</sup> The suprascapular nerve is a mixed nerve, having both motor and sensory branches.

The nerve traverses chiefly through the suprascapular foramen with the suprascapular vein and the suprascapular artery is usually passing above the suprascapular foramen. As the superior transverse scapular ligament (STSL) bridges the suprascapular notch (SSN) converting it into an osseous-fibrous foramen through which suprascapular nerve invariably traverses can result in injury or compression to the suprascapular nerve, which is coined as suprascapular nerve entrapment syndrome. <sup>6,7</sup>

Morphological variations of the SSN were classified into type I (notch absent), II (shallow V shaped notch), III (U shaped notch), IV (deep notch), V (partial ossified STSL) and VI (completely ossified STSL) by Rengachary et al. <sup>8</sup>



There is to some extent a change in morphology in and around the SSN with increasing age.<sup>5</sup> Different variations of STSL includes calcification, partial or complete ossification and multiple bands.<sup>6</sup>

The ossifications of the STSL are major risk factors for suprascapular neuropathy due to entrapment of the SN especially among the volleyball, basketball and tennis players due to frequent overhead abduction<sup>8</sup>. Kopell and Thompson in 1959 were described the above SN neuropathy associated with anatomical variation of SSN approximately 1–2% of all shoulder pathology.<sup>7</sup>

Variations in the superior transverse scapular ligament and supra-scapular notch are the most recognized possible predisposing factors for supra-scapular nerve entrapment. Clinically the neuropathy causes deep and diffused poorly localized pain, weakness of abduction and external rotation of the upper extremity, and atrophy of the supraspinatus and infraspinatus muscles. Many incidences of variations of supra-scapular notch with associated supra-scapular nerve neuropathy in different population has been reported but less attention has been given to the morphology and anatomical cause of the ossification of the supra-scapular ligament

The present study documents the different morphology of suprascapular notch and the incidence of ossified STSL and discusses its clinical significance in the Eastern Indian population. The sampling in such studies is convenient sampling (not purely random) specimens. Such studies should be encouraged further as it helps to add up to the existing sample size from different studies in India, to be of use in meta-analysis study of SSN in the populations of India and the world at large.

AIM: The purpose of this study was to document the incidence, morphology and clinical significance of SSN and the existence of ossified STSL

### MATERIALS AND METHODS

The present analytical cross-sectional study was conducted on 291 dried human scapulae of unknown sex obtained from the osteology bank of Anatomy department, SCB Medical College, Cuttack, Odisha with due permission obtained from the HOD Anatomy from May 2022 to December 2022. Scapulae with damaged SSN were excluded from the study.

Shape of the notch was recorded on gross examination and classified into various types. There are six basic types of scapular notch.<sup>8</sup> Representative photographs of various types were taken by digital camera and documented.

### Factors responsible for ossification of STSL:

Age: older >younger, Sex: male>female (Testosterone), Genetic factor, Mechanical load,

Determination of proportion of suprascapular notch:

**Type I:** Notch is absent. The superior border forms a wide depression from the medial angle to the coracoid process

**Type II:** Notch is a blunted V-shape occupying the middle third of the superior border.

**Type III:** Notch is U-shaped with nearly parallel margins.

**Type IV:** Notch is V-shaped and very small. A shallow groove is frequently formed for the suprascapular nerve adjacent to the notch.

**Type V:** Notch is minimal and U-shaped with a partially ossified ligament.

**Type VI:** Notch is a foramen as the ligament is completely ossified

**Ethical issue:** Ethical clearance had not been considered in the present study as per National Health Act No. 61/2003.

**Statistical analysis:** The observed data were analyzed by SPSS (24) software version. The percentages and proportions were presented in text and tables. The P value (<0.05) was considered statistically significant.

### RESULTS

In the present study the various supra-scapular notches (SSN) are examined as per the frequency distribution of morphological types and mentioned in tables.

In the present study the maximum number of Type III 151(52%) were observed followed by Type I 58(20%), Type II 29 (10%), Type V 24 (8%), Type VI 17(6%) and Type IV 12(4%). (Table No 1 and Fig No 1-6). In the present study 17(5.8%) specimens were completely ossified and 24 (8.2%) were partially ossified out of 291 scapula observed. (Table No 2, Fig No 5, Fig No 6)

**Table 1:** Distribution of SSN according to rengachary’s classification

Types	Type I	Type II	Type III	Type IV	Type V	Type VI	Total
No. of Scapula	58	29	151	12	24	17	291
Percentage	20%	10%	52%	4%	8%	6%	100%

**Table 2:** Incidence of Completely Ossified and Partially Ossified STSL

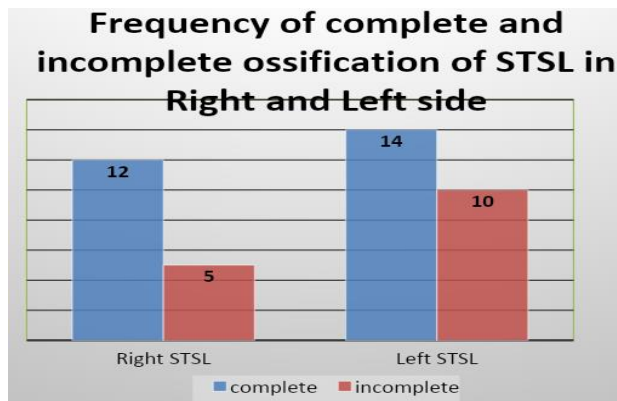
Ossified SESL	Right	Left	Total	N=291(%)
Complete	12	5	17	5.8%
Incomplete	14	10	24	8.2%
Total	26	15	41	14.08%



Type V (6%): Notch is minimal and U-shaped with a partially ossified ligament and Type VI (4%): Notch is a foramen as the ligament is completely ossified.

 <p><b>TYPE I: ABSCENCE OF NOTCH</b></p>	 <p><b>TYPE II: BLUNTED NOTCH</b></p>
<p><b>Figure 1:</b> Type I (8%): Notch is absent.</p>	<p><b>Figure 2:</b> Type II (31%): Notch is a blunted V-shape</p>
 <p><b>TYPE III: U SHAPED NOTCH</b></p>	 <p><b>TYPE IV: V SHAPED NOTCH</b></p>
<p><b>Figure 3:</b> Type III (48%): Notch is U-shaped with nearly parallel margins.</p>	<p><b>Figure 4:</b> Type IV (4%): Notch is V-shaped and very small.</p>
 <p><b>TYPE: V PARTIALLY OSSIFIED NOTCH</b></p>	 <p><b>TYPE: VI COMPLETELY OSSIFIED NOTCH</b></p>
<p><b>Figure 5:</b> Type V: partially ossified</p>	<p><b>Figure 6:</b> Type VI: completely ossified</p>





A Pearson’s chi square test of independence was performed to test for association between left side and right side STSL and the complete and incomplete calcification status of the STSL ligament and there was no significant relationship between the two variables at  $p < .05$ . [ $\chi^2 (1,41)=0.644, p=0.422$ ]

**Table 3:** Incidence of Fan Shaped and Band Shaped STSL in Completely Ossified Specimen

Ossified STSL	Right	Left	Total n= 17
Fan shaped	4	3	7 (41.1%)
Band shaped	8	2	10 (59%)
Total	12	5	17 (100%)

The incidence of fan shaped bands were 7 (41.1%) and band shaped 10 (59%) out of 17 specimens observed for ossified STSL.

In the specimen with completely ossified STSL, the proximal width (PW) and distal width (DW) of the bony bridge at the proximal and distal end were measured. The bony bridge which has  $PW/DW >2$  was classified as fan shaped and  $PW/DW <2$  was classified as band shaped. (Table No 3).

Since the samples size was low, a fisher’s exact test was utilized to test if there was significant association between the shape of STSL (fan shape and band shape) and sidedness (right and left) the result was not significant at  $p < .05$  level

**DISCUSSIONS**

The two ends of supra scapular notch is bridged by a superior transverse scapular ligament (STSL) converting it into a foramen through which supra scapular nerve (SSN) traverses. The anatomical variation of the SSN includes variation in shape, complete or partial ossification of STSL. Previously SSN has been classified by many researchers based on complex geometrical calculation.<sup>9,10</sup>

In the type I the supra-scapular notch (SSN) was absent with wide depression on the superior border of the scapula constituted 20% of the total 291 specimens examined. The results were corroborative with previous authors.<sup>11, 12,13.</sup> Rengachary et al. & Albino P et al. observed it as 8% and 12.4% respectively, which was lower than the present study, maybe due racial variation. (Table No 4, Fig 1) Similarly in the second type (Type II) there were 29(10%) of total scapulae observed, which was corroborative with Indian studies but lower than the findings of American, Kenyan and Italian specimens.<sup>8,14,15</sup>

In the present study Type III was observed in maximum specimens 151(52%) followed by Type I 58(20%), which corresponds to Rengachary et al.<sup>8</sup>, Sangram MR et al. 13 and Kannan U et al<sup>3</sup>

The least common occurrence was Type IV 12(4%) very small or absence of notch, In the present study the incidence of partially ossified SSN Type V was 24(8%) and completely ossified SSN Type VI was 17(6%) respectively.<sup>16, 17, 18</sup> All the 3 types (IV,V and VI) were responsible for suprascapular nerve entrapment syndrome either in combination with an anomalous ossified supra-scapular notch, narrowed notch or absence of notch.<sup>4,8</sup>

Variation in the morphology of SSN had been identified for supra-scapular nerve entrapment. Several classifications of variations of SSN had been reported. Ticker et al.<sup>5</sup> divided the notch into U-shaped (77%) and V-shaped (33%). Polguy classified into types based on specific geometric parameter.<sup>12</sup> Rengachary et al.<sup>8</sup> classified into 6 types and our present study followed the same classification where type III(52%) is more common and type IV(4%) is least common.<sup>19</sup> (Table No 4, Fig V, VI).

Partial and complete ossification of STSL have also been identified as one of the predisposing factor for suprascapular nerve entrapment. In our study complete ossification was observed in 6% cases, similar with the findings of 4% of Rengachary et al and 5% by Ticker et al.<sup>8,9</sup>

According to Polguy, fan shaped STSL (54.6%) is more common than band shaped type(41.9%). In our study band shaped (58.8%) was more common than fan shaped type (41.2%) due to different population<sup>13,19</sup> The mean surface area of supra-scapular foramen is significantly smaller in band type hence chance of nerve compression was higher in comparison to other types.

**Table 4:** comparison of types of SSN studied by various authors

Authors	Specimens	Type I	Type II	Type III	Type IV	Type V	Type VI
Rengachary et al. <sup>8</sup>	N=211 American	8%	31%	48%	3%	6%	4%
Sangram MR et al. <sup>13</sup>	N=104 Indian	21.15%	8.65%	59.61%	2.88%	5.76%	1.93%
Albino P et al. <sup>14</sup>	N=500 Italian	12.4%	19.8%	22.8%	31.1%	10.2%	3.6%
Sinkeet et al. <sup>15</sup>	N= 138 Kenyan	22%	21%	29%	5%	18%	4%
Kannan U et al <sup>3</sup>	N=400 Indian	20%	10%	52%	4%	4%	10%
Present study	N=291 Indian	20%	10%	52%	4%	8%	6%



## CONCLUSION

Since the suprascapular nerve entrapment might be caused by complete ossification of STSL with formation of suprascapular foramen and other morphometric variations of SSN, the knowledge of such variations is essential for clinicians, for making a proper diagnosis and for planning the most suitable surgical intervention. The ossified band shaped STSL as a potential risk factor in suprascapular nerve entrapment. The morphology of the suprascapular notch is considered to be a risk factor for suprascapular nerve entrapment either in combination with an anomalous STSL or as a narrowed notch. Accordingly, this notch is an important landmark of supra-scapular nerve during arthroscopic shoulder operation.

**Works attributed to:** Department of Anatomy, S.C.B. Medical College and Hospital Cuttack,

**Author's contribution:** DPB and SP - Definition of intellectual contents, literature survey, implementation of study protocol, data collection and data analysis. BX - Prepared first draft of Manuscript prepare and submission of manuscript concept design, clinical protocol, manuscript revision: MKD – Design of study, statistical analysis, interpretation, Review of manuscript and preparation of figures: DNM –Final revision of manuscript coordination and manuscript Submission.

## REFERENCES

- Escamilla RF, Yamashiro K, Paulos L, Andrews JR. Shoulder muscle activity and function in common shoulder rehabilitation exercises. *Sports Med.* 2009; 39(8):663-85.
- Perry J. Anatomy and biomechanics of the shoulder in throwing, swimming, gymnastics, and tennis. *Clin Sports Med.* 1983;2(2):247-70. PMID: 9697636.
- Kannan U, Kannan NS, Anbalagan J, Rao. Morphometric study of suprascapular notch in Indian dry scapulae with specific reference to the incidence of completely ossified superior transverse scapular ligament. *J Clin Diagn Res.* 2014; 8(3):7-10.
- Ebraheim NA, Whitehead JL, Alla SR, Moral MZ, Castillo S, McCollough AL, et al. The suprascapular nerve and its articular branch to the acromioclavicular joint: an anatomic study. *J Shoulder Elbow Surg.* 2011; 20(2):e13 –7.
- Lädermann A, Lübbecke A, Mélis B, Stern R, Christofilopoulos P, Bacle G, et al. Prevalence of neurologic lesions after Total shoulder Arthroplasty. *J Bone Joint Surgery-American.* 2011; 93(14): 1288 – 1293.
- Bozzi F, Alabau-Rodriguez S, Barrera-Ochoa S, Ateschrang A, Schreiner AJ, Monllau JC, Perelli S. Suprascapular Neuropathy around the Shoulder: A Current Concept Review. *J Clin Med.* 2020; 9(8):23-31.
- Kopell H.P., Thompson W.A. Pain and the frozen shoulder. *Surg. Gynecol. Obstet.* 1959; 109(1):92–96.
- S.S. Rengachary, D.Burr & S.Lucas. "Suprascapular entrapment neuropathy: a clinical, anatomical and comparative study.II : anatomical study," *Neurosurgery*, vol. 1979; 5( 4): 447-451.
- Ticker JB, Djurasovic M, Strauch RJ, April EW, Pollock RG, Flatow EL, Bigliani LU. The incidence of ganglion cysts and other variations in anatomy along the course of the suprascapular nerve. *J Shoulder Elbow Surg.* 1998; 7(5): 472-8.
- Cohen, S. B.; Dnes, D.M. & Moorman, C.T. Familial calcification of the Superior transverse scapula ligament causing neuropathy. *Clin.Orthop Rel. Res.* 1997, 334:131-135.
- B. Moriggl, P. Jax, S. Milz, A. Buttner and M. Benjamin .Fibrocartilage at the entheses of the suprascapular (superior transverse scapular) ligament of man-a ligament spanning two regions of a single bone. *J. Anat.* 2001; 19(9):539-545.
- Polgaj M, Sibiński M, Grzegorzewski A, Waszczykowski M, Majos A, Topol M. Morphological and Radiological Study of Ossified Superior Transverse Scapular Ligament as Potential Risk Factor of Suprascapular Nerve Entrapment. *Biomed Res Int.* 2014; doi: 10.1155/2014/613601.
- Sangam MR, Sarada Devi SS, Krupadanam K, Anasuya K. A study on the morphology of the suprascapular notch and its distance from the glenoid cavity. *J Clin Diagn Res.* 2013;7(2):189-192.
- Albino P, Carbone S, Candela V, Arceri V, Vestri AR, Gumina S. Morphometry of the suprascapular notch: correlation with scapular dimensions and clinical relevance. *BMC Musculoskelet Disord.* 2013; 14:172. doi: 10.1186/1471-2474-14-172.
- Sinkeet SR, Awori KO, Odula PO, Ogeng'o JA, Mwachaka PM. "The suprascapular notch: its morphology and distance from the glenoid cavity in a Kenyan population." *Folia Morphol. (Warsz).* 2010; 69(4):241-245.
- Piotr L, Synder M, Mariusz W, Orczyk K, Hubert J, Topol M. Protective and Predisposing Morphological factors in Suprascapular Nerve Entrapment Syndrome: A Fundamental Review Based on Recent Observations. *Bio Med Res Int.* 2017; Article ID 4659761: 1-9.
- Kumar A, Sharm A, Singh P. Anatomical study of the suprascapular notch: quantitative analysis and clinical considerations for suprascapular nerve entrapment. *Singapore Med J.* 2014; 55(1):41–44.
- Memon AB, Dymm B, Ahmad BK, Sripathi N, Schultz L, Chandok A. Suprascapular neuropathy: A review of 87 cases. *Muscle Nerve.* 2019; 60(3):250-253.
- Kaledzera T, Matundu B, Adefolaju GA, Manda J, Mwakikunga A. Morphometric study of the suprascapular notch and scapular dimensions in adult Malawian cadavers and implications of completely ossified superior transverse scapular ligament. *Pan Afr Med J.* 2022; 21;41:324.

**Source of Support:** The author(s) received no financial support for the research, authorship, and/or publication of this article.

**Conflict of Interest:** The author(s) declared no potential conflicts of interest with respect to the research, authorship, and/or publication of this article.

For any questions related to this article, please reach us at: [globalresearchonline@rediffmail.com](mailto:globalresearchonline@rediffmail.com)

New manuscripts for publication can be submitted at: [submit@globalresearchonline.net](mailto:submit@globalresearchonline.net) and [submit\\_ijpsrr@rediffmail.com](mailto:submit_ijpsrr@rediffmail.com)

