



## Evaluation of Effectiveness and Functional Outcome of Locking Humerus Plating for Early Mobilization of Proximal Humerus Fractures in Tertiary Care Hospital of Eastern India

Dr Kumar Gautam, Dr Rajni Kaushav, Dr Rakesh Kumar\*

1. Senior Resident, Department of Orthopaedics, Sri Krishna Medical College and Hospital, Muzaffarpur, Bihar, India.
2. Senior Resident, Department of Obstetrics and Gynaecology, RDJM Medical College & Hospital, Muzaffarpur, Bihar, India.
3. Associate Professor and HOD, Department of Orthopaedics, Sri Krishna Medical College and Hospital, Muzaffarpur, Bihar, India.

\*Corresponding author's E-mail: [rakesh23664@gmail.com](mailto:rakesh23664@gmail.com)

Received: 18-09-2023; Revised: 22-10-2023; Accepted: 30-10-2023; Published on: 15-11-2023.

### ABSTRACT

**Introduction:** The fixation of fractures in the proximal humerus is challenging and is linked to high rates of complications, particularly in senior patients, because of osteoporotic bones. Locking plates were created with the proximal humerus' anatomy in mind. These plates are more biomechanically suitable for fixing proximal humerus fractures due to their low profile. Because of their low rate of complications, locking plates are now often utilized to fixate fractures in the proximal humerus.

**Aims/objective:** To compare the effectiveness and evaluate the functional outcome and problems related to locking humerus plating utilized in fixing displaced proximal humerus fractures.

**Materials and Method:** Patients of either sex of age greater than 18 years with displaced fracture of proximal humerus according to Neer classification criteria had PHILOS locking plating and open reduction internal fixation while under general anaesthesia. Constant shoulder and Neer score were used for the functional evaluation. Every follow-up visit included radiography to assess fracture union and to record any complications such as fracture malalignment, loss of reduction, or varus-valgus mal-union.

**Results:** Most of the patients (54.28%) were greater than 50 years of age and most of them were male (65.71%). RTA was major cause of fracture in more than 70 percent of cases. Most of the cases were 2-part fracture of humerus (48.57%) followed by 3-part fracture in 28.57% of cases. Incidence of plate impingement or varus malunion were less than 10%. Stiffness was present in only 11.43% of cases. 65.72% of patients had excellent or good outcome after locking humerus plating as per constant shoulder and Neer score. Only 11.43% of patients had poor outcome.

**Conclusion:** For the treatment of proximal humerus fractures, locking compression plates are advantageous primarily because they provide solid fixation, angular stability, and the possibility of early physical recovery.

**Keywords:** Proximal Humerus Fracture, Locking Humerus Stability, Good Union, Mal-union, Functional Recovery.

### INTRODUCTION

As the most prevalent type of humerus fracture (45%), proximal humerus fractures can account for up to four to five percent of all fractures.<sup>1, 2</sup> Osteoporosis is linked to an increased risk of proximal humerus fractures in the elderly population.<sup>3</sup> In older patients, proximal humerus fractures rank third in frequency.<sup>4,5</sup> The fixation of fractures in the proximal humerus is challenging and is linked to high rates of complications, particularly in senior patients, because of osteoporotic bones.<sup>3</sup>

Falling onto an outstretched hand is the most frequent mechanism of injury, especially in elderly female patients with osteoporosis. Younger patients usually have proximal humerus fractures after high-energy trauma, like auto accidents.<sup>6</sup> Eighty percent of proximal humeral fractures are non-displaced or only slightly displaced, and they can be managed conservatively.<sup>6</sup> K-wire fixation and non-operative therapy cause stiffness and a reduction in range of movement.<sup>7-9</sup>

The best way to treat fractures that are unstable or displaced is still up for debate. The literature has reported

a number of methods, involving arthroplasty, percutaneous or minimally invasive procedures with pins or screws, intramedullary nailing, open reducing of fractures and internal fixation with proximal humeral locking plates, and intramedullary nailing.<sup>7,10</sup> The PHILOS (Proximal Humerus Internal Locking System) plate was created to reduce the considerable number of complications connected with such fractures and to enhance angular stability, particularly in osteoporotic bones.<sup>8,9</sup>

Non locking plates, such as cloverleaf and T-plates, have a high incidence of failure in fragile osteoporotic bones and a high chance of complications, such as AVN (avascular necrosis), subacromial impingement, and slippage of the screws.<sup>11,12</sup> Tension band wiring has not been shown to be beneficial for treating proximal humerus fractures, according to several research.<sup>13,14</sup> Later, blade plates were developed, which were more robust than the standard plates that had been used before. However, because of their wider profile and poor hold in osteoporotic bones, blade plates have an elevated rate of failure.<sup>15</sup>

Although load sharing devices such as intra-medullary nails have a lower lever arm, they are linked to a high likelihood



of complications (31%) because not enough proximal screws were purchased.<sup>16</sup> Reversing or undoing the proximal screw was among the most frequently observed issue. The 2-part fractures of the proximal humerus showed the best results.<sup>17, 18</sup>

Locking plates were created with the proximal humerus' anatomy in mind. These plates are more biomechanically suitable for fixing proximal humerus fractures due to their low profile.<sup>18</sup> In weak osteoporotic bones, they offer locking screw anchoring and angular stability.<sup>19</sup> These plates feature tiny holes for attaching stitches or cerclage wires to the rotator cuff muscle in addition to numerous locking screws. For improved pull-out durability, this plate additionally offers a variety of locking screw alternatives that can be installed in a divergent or convergent manner.<sup>18, 20</sup> Because of their low rate of complications, locking plates are now often utilized to fixate fractures in the proximal humerus.<sup>19, 20</sup>

The purpose of this research was to compare the effectiveness and evaluate the functional outcome and problems related to locking humerus plating utilized in fixing displaced proximal humerus fractures.

## MATERIALS AND METHODS

It was an observational & prospective study conducted in department of orthopaedic of a tertiary care hospital of eastern India from July 2022 to June 2023 after getting approval from institutional ethics committee under the guidelines of good clinical practice and declaration of Helsinki.

### Inclusion Criteria:

Patients of either sex of age greater than 18 years with displaced fracture of proximal humerus according to NEER classification criteria<sup>21</sup> planned for surgery using locking humerus plating were included.

### Exclusion Criteria:

Patients with shoulder dislocation or planned for revised surgery for implant failure, or having pathological fracture from primary or metastatic cancer or having open fracture wound or with neurovascular abnormalities were excluded.

### Sampling Method:

Consecutive sampling method was used and all patients meeting our eligibility criteria during study period were enrolled after taking written informed consent from the eligible subjects who were provided with participant information sheet in their local language.

Patients had PHILOS locking plating and open reduction internal fixation while under general anaesthesia. All patients received three intravenous doses of antibiotics (first generation cephalosporins), the first administered prior to surgery and the other two administered following it. On the first post-operative day, exercises with a shoulder pendulum, active assistance, and passive

exercises were begun. As soon as radiographs showed fracture union, active shoulder workouts were initiated. Early mobilization lessens pain during the recovery phase and encourages the patient to keep up physical therapy after being released from the hospital.

Constant shoulder and Neer score were used for the functional evaluation.<sup>22</sup> Follow up was done every six months and at the first, third, sixth, and twelve weeks. There were four grades for the continuous score: Poor (0 to 55 points), moderate (56 to 70 points), good (71 to 85 points), and excellent (86 to 100 points). Every follow-up visit included radiography to assess fracture union and to record any complications such as fracture malalignment, loss of reduction, or varus-valgus mal-union. Failure was characterized as the humeral head developing AVN (avascular necrosis), mal-union, non-union, and backing out of the screw or plate breakage or pull-out. Radiographs were taken to check for union or any of the aforementioned complications, and patients were assessed using the Neer score at the last follow-up.

Cortical continuity, callus development, and the existence of bridging osseous trabecula were regarded as indicators of good union radiologically. The angle that exists between the humerus head and humeral shaft axis is known as the humeral head-shaft angle. The head's apex was used to draw a line that was perpendicular to the anatomical neck's closest medial and lateral ends. The head-shaft angle was evaluated between the radiographs taken immediately after surgery and the latest follow-up. It was further classified as major varus (115°), minor varus (115–124°), normal (125–145°), minor valgus (146–155°), and major valgus (155°).

### Statistical Analysis

Data collected from the patients were represented in tabular form using Microsoft Excel 365 and transferred to graph pad version 8.4.3 for further statistical analysis. Patients' demographic and clinical characteristics such as like age, sex, cause of fracture, side of fracture, complications and grading based on Neer score were expressed as frequency and percentage using descriptive statistics.

## RESULTS

In this study, 35 patients with displaced fracture of proximal humerus according to NEER classification criteria planned for surgery using locking humerus plating were included. Their baseline demographic and clinical characteristics are given in Table 1.



**Table 1:** Baseline demographic and clinical characteristics of patients planned for surgery using locking humerus plating

Variables	Number of Patients	Percentage of Patients (n = 35)
Age		
18-30	6	17.14
31-50	10	28.57
50-60	9	25.71
>60	10	28.57
Gender		
Male	23	65.71
Female	12	34.29
Cause of Fracture		
RTA	25	71.43
Fall	10	28.57
Side of Fracture		
Right	20	57.14
Left	15	42.86

Most of the patients (54.28%) were greater than 50 years of age and most of them were male (65.71%). RTA was major cause of fracture in more than 70 percent of cases. Most of the fracture were of right humerus.

**Table 2:** Distribution of patients according to classification of humerus fracture

Type	Number of Patients	Percentage of Patients (n = 35)
2 Part Fracture	17	48.57
3 Part Fracture	10	28.57
4 Part Fracture	8	22.86

Most of the cases were 2-part fracture of humerus (48.57%) followed by 3-part fracture in 28.57% of cases.

**Table 3:** Frequency of complications found after locking humerus plating

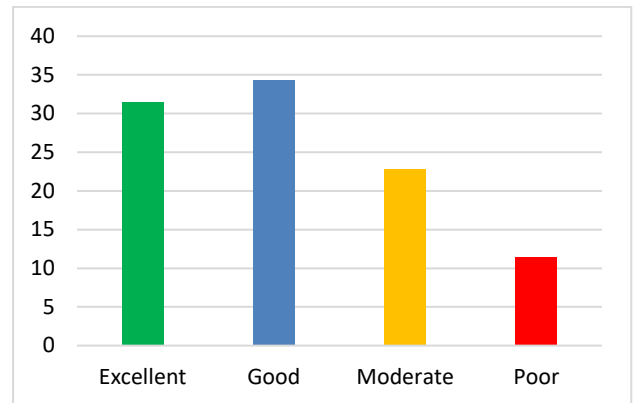
Complications	Number of Patients	Percentage of Patients (n = 35)
Plate impingement	3	8.57
Varus Malunion	3	8.57
Stiffness	4	11.43

Incidence of plate impingement or varus malunion were less than 10%. Stiffness was present in only 11.43% of cases.

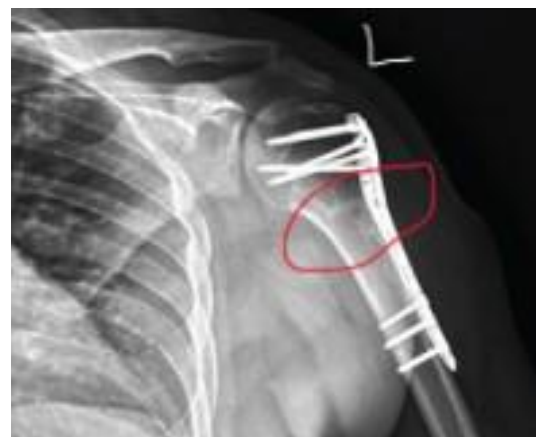**Table 4:** Distribution of patients with respect to constant shoulder Neer score

Grade	Number of Patients	Percentage of Patients (n = 35)
Excellent	11	31.43
Good	12	34.29
Moderate	8	22.86
Poor	4	11.43

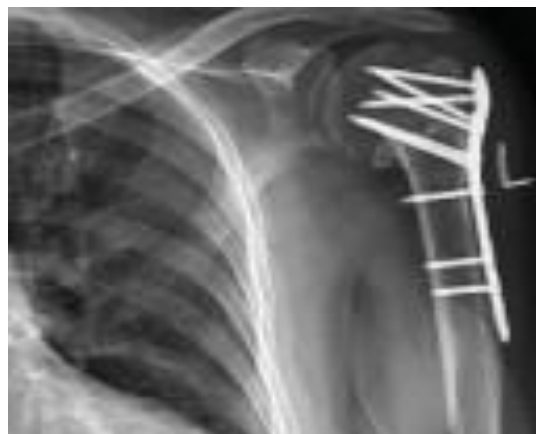65.72% of patients had excellent or good outcome after locking humerus plating as per constant shoulder and Neer score. Only 11.43% of patients had poor outcome.



**Figure 1:** Outcome of Patients after Surgery as per Neer Score



**Figure 2:** Antero-Posterior Radiograph of 1-Year Follow Up of a Patient aged 26 Years Showing Good Union



**Figure 3:** Antero-Posterior Radiograph of 2-Year Follow Up of a Patient aged 55 Years Showing Varus Malunion

**DISCUSSION**

The current study sought to assess the clinical result following PHILOS plate attachment as well as any potential follow-up issues. The study has published the preliminary PHILOS plate fixing results. The premise that the surgical

approach to plate fixation does not significantly affect the result is also supported by this research.

In general, a higher percentage of patients attained satisfactory union, with fewer than 10% experiencing malunion. RTA, which involves 2-part, 3-part, and 4-part proximal humerus fractures, was the most prevalent type of injury, according to a study by Arumugam S et al. on 30 patients, most of whom were male and elderly.<sup>22</sup> 65.72% of patients had excellent and good results, whereas 11.43% had poor results based on Neer's criteria. There were no case of non-union. The average age in the study by Chintan Doshi et al. was  $54.30 \pm 5.80$  years.<sup>24</sup>

Significant rates of complication (16 to 36 percent) have been reported in other researches. These include osteonecrosis of the head of the humerus, subacromial impingement, varus mal-union, non-union, and failure of the implant. All of these complications have a negative impact on the result. Moreover, the majority of these issues were linked to subpar surgical methods, incorrect implant placement, and inaccurate intraoperative measurements of screw size and reduction. Furthermore, to avoid potential problems such as avascular necrosis, careful surgical incision is required to protect the vascularity of the humeral head.<sup>25, 26, 27</sup> The functional result of surgical treatment for proximal humerus fractures is greatly influenced by early physiotherapy and rehabilitation therapies, which enable swift mobilization and a recovery to near-normal functional state.

Osteoporosis is more common in older adults, which has led to an increase in the number of patients suffering from proximal humerus fractures in recent decades. Numerous investigations have demonstrated that osteoporosis negatively impacts internal fixation anchoring and increases the likelihood of failure.<sup>28, 29</sup> Individuals with three or four component proximal humerus fractures are more likely to experience significant non-union rates and subpar clinical outcomes, particularly if traditional non locking plates were used for fixation.<sup>12, 30</sup>

Proximal humeral fractures have been treated with a variety of fixing techniques in the past, with varying degrees of success. In Sadowski et al.'s study, 100% of the problems following PlantTan plate fixation occurred, particularly in elderly osteoporotic bones. The most frequent event was dysfunction of the proximal screw.<sup>31</sup> Numerous investigations on patients treated with tension band wire have shown results comparable to the patient receiving non-surgical therapy.<sup>13, 14</sup> It has also been demonstrated that cloverleaf and AO-T plates perform poorly in patients with osteoporosis.<sup>11, 12</sup> With such plates, problems such as screw dysfunction, subacromial impingement, and up to 40% AVN have been documented.<sup>11, 12</sup> Later, the polarus nail was used to repair similar fractures, but a significant rate of complications (proximal screw dysfunction, additional surgery, and lateral metaphyseal comminution, which increases the risk of implant failure) were seen.<sup>16, 32, 33</sup>

Comparing locking plates to traditional plates from the past, the former offer more stability.<sup>34, 35</sup> Numerous researchers have proven that they prevent issues and provide an improved functional outcome.<sup>1, 9</sup> As a result, especially in older patients with low quality bones, the use of locking plates for open fracture reduction and internal fixation of fractures in the proximal humerus has become standard procedure.<sup>9, 36</sup> In addition, the stability the plate provides affects the functional result. All of the stresses in the locking plate system are transferred from the bone to the plate via the locking head screws and the other way around. Therefore, the fixed angle plates allow for an increase in torsional rigidity and stability, which may lead to a better result and a lower risk of problems such as fractures distal to the plate, failure, AVN, and dysfunction of the screws and plates.<sup>36</sup>

This study is limited in two important ways. Initially, there were fewer patients and a shorter mean follow-up period. We propose that larger sample sizes and longer follow-up times will help to confirm the findings found here.

## CONCLUSION

With early mobilization, PHILOS plate fixation provides satisfactory orthopaedic results in cases with proximal humerus fractures. For the treatment of proximal humerus fractures, locking compression plates are advantageous primarily because they provide solid fixation, angular stability, and the possibility of early physical recovery. Patients benefit from prompt mobilization, improved shoulder operation, and a significantly sooner return to routine activities. Research comparing various methods for applying locking humerus plating is necessary.

## REFERENCES

1. Helmy N, Hintermann B. New trends in the treatment of proximal humerus fractures. *Clin Orthop*. 2006;442:100–08.
2. Kristiansen B, Bartod G, Bredesen J, et al. Epidemiology of proximal humerus fractures. *Acta Orthop Scand*. 1987;58(1):75–77.
3. Kannus P, Palvanen M, Niemi S, et al. Osteoporotic fractures of the proximal humerus in elderly Finnish persons: sharp increase in 1970-1998 and alarming projections for the new millennium. *Acta Orthop Scand*. 2000;71:465–70.
4. Lind T, Kroner K, Jensen J. The epidemiology of fractures of proximal humerus. *Arch Orthop Trauma Surg*. 1989;108:285–87.
5. Nguyen TV, Center JR, Sambrook PN, et al. Symptomatic fracture incidence in elderly men and women: the Dubbo Osteoporosis Epidemiology Study. *Am J Epidemiol*. 2001;153:587–595.
6. Lannotti JP, Ramsey ML, Williams GR, Warner JP. Non prosthetic management of proximal humerus fractures. *JBJS (Am)* 2003;85:1578–93.
7. Resch H, Povacz P, Frohlich R, Wambacher M. Percutaneous fixation of three- and four-part fractures of the proximal humerus. *J Bone Joint Surg Br*. 1997;79(2):295–300.
8. Lungershausen W, Bach O, Lorenz CO. Locking plate osteosynthesis for fractures of the proximal humerus [in German] *Zentralbl Chir*. 2003;128(1):28–33.



9. Björkenheim JM, Pajarinen J, Savolainen V. Internal fixation of proximal humeral fractures with a locking compression plate: a retrospective evaluation of 72 patients followed for a minimum of 1 year. *Acta Orthop Scand.* 2004;75(6):741–45.
10. Mittlmeier TW, Stedtfeld HW, Ewert A, Beck M, Frosch B, Gradl G. Stabilization of proximal humeral fractures with an angular and sliding stable antegrade locking nail (Targon PH) *J Bone Joint Surg Am.* 2003;85(suppl 4):136–46.
11. Rees J, Hicks J, Ribbans W. Assessment and management of three- and four-part proximal humeral fractures. *Clin Orthop Relat Res.* 1998;353:18–29.
12. Kristiansen B, Christensen SW. Plate fixation of proximal humeral fractures. *Acta Orthop Scand.* 1986;57(4):320–23.
13. Ilchmann T, Ochsner PE, Wingstrand H, Jonsson K. Non-operative treatment versus tension-band osteosynthesis in three- and four-part proximal humeral fractures. A retrospective study of 34 fractures from two different trauma centers. *Int Orthop.* 1998;22(5):316–20. [PMC free article]
14. Zyto K, Ahrengart L, Sperber A, Törnkvist H. Treatment of displaced proximal humeral fractures in elderly patients. *J Bone Joint Surg Br.* 1997;79(3):412–17.
15. Drosdowech DS, Faber KJ, Athwal GS. Open reduction and internal fixation of proximal humerus fractures. *Orthop Clin North Am.* 2008;39(4):429–39.
16. Rajasekhar C, Ray PS, Bhamra MS. Fixation of proximal humeral fractures with the Polarus nail. *J Shoulder Elbow Surg.* 2001;10(1):7–10.
17. Young AA, Hughes JS. Locked intramedullary nailing for treatment of displaced proximal humerus fractures. *Orthop Clin North Am.* 2008;39(4):417–28.
18. Strohm PC, Helwig P, Konrad G, Südkamp NP. Locking plates in proximal humerus fractures. *Acta Chir Orthop Traumatol Cech.* 2007;74(6):410–15.
19. Moonot P, Ashwood N, Hamlet M. Early results for treatment of three- and four-part fractures of the proximal humerus using the PHILOS plate system. *J Bone Joint Surg Br.* 2007;89(9):1206–09.
20. Thanasas C, Kontakis G, Angoules A, Limb D, Giannoudis P. Treatment of proximal humerus fractures with locking plates: a systematic review [published online ahead of print September 12, 2009] *J Shoulder Elbow Surg.* 2009;18(6):837–44.
21. Neer CS 2nd. Displaced proximal humeral fractures. I. Classification and evaluation. *J Bone Joint Surg Am.* 1970;52:1077–89.
22. Constant CR. Cork: MCH Thesis. University College; 1986. Age related recovery of shoulder function after injury
23. Arumugam S, Arumugam V, Raviraman V. Surgical management of proximal humerus fracture treated with locking compression plate. *Int J Res Orthop* 2017;3:1165- 9.
24. Chintan Doshi, Gaurav Mahesh Sharma, Lokesh Gudda Naik, Krishna Badgire, Faisal Qureshi, Treatment of Proximal Humerus Fractures using PHILOS Plate, *Journal of Clinical and Diagnostic Research.* 2017 Jul, Vol-11(7): RC10-RC13
25. Jung WB, Moon ES, Kim SK, et al. Does medial support decrease major complications of unstable proximal humerus fractures treated with locking plate? *BMC Musculoskeletal Disord.* 2013; 14: 102.
26. Egol KA, Ong CC, Walsh M, et al. Early complications in proximal humerus fractures (OTA Types 11) treated with locked plates. *J Orthop Trauma* 2008; 22(3): 159–164.
27. Dheerendra SK, Khan WS, Barber J, et al. Outcomes of locking plates in proximal humeral fractures: a systematic review. *Shoulder and Elbow* 2011; 3(2): 74–84.
28. Barrios C, Brostrom LA, Stark A, Walheim G. Healing complications after internal fixation of trochanteric hip fractures: the prognostic value of osteoporosis. *J Orthop Trauma.* 1993;7(5):438–42.
29. Giannoudis PV, Schneider E. Principles of fixation of osteoporotic fractures. *J Bone Joint Surg Br.* 2006;88(10):1272–78.
30. Paavolainen P, Björkenheim JM, Slati P, Pauku P. Operative treatment of severe proximal humeral fractures. *Acta Orthop Scand.* 1983;54(3):374–79.
31. Sadowski C, Riand N, Stern R, Hoffmeyer P. Fixation of the proximal humerus with the PlantTan Humerus Fixator Plate: early experience with a new implant. *J Shoulder Elbow Surg.* 2003;12:148–51.
32. Adedapo AO, Ikpeme JO. The results of internal fixation of three- and four-part proximal humeral fractures with the Polarus nail. *Injury.* 2001;32:115–21.
33. Agel J, Jones CB, Sanzone AG, Camuso M, Henley MB. Treatment of proximal humeral fractures with Polarus nail fixation. *J Shoulder Elbow Surg.* 2004;13:191–95.
34. Weinstein DM, Bratton DR, Ciccone WJ II, Elias JJ. Locking plates improve torsional resistance in the stabilization of three-part proximal humeral fractures. *J Shoulder Elbow Surg.* 2006;15(2):239–43.
35. Walsh S, Reindl R, Harvey E, Berry G, Beckman L, Steffen T. Biomechanical comparison of a unique locking plate versus a standard plate for internal fixation of proximal humerus fractures in a cadaveric model. *Clin Biomech.* 2006;21(10):1027–31.
36. Koukakis A, Apostolou CD, Taneja T, Korres DS, Amini A. Fixation of proximal humerus fractures using the PHILOS plate: early experience. *Clin Orthop Relat Res.* 2006;442:115–20.
37. Lill H, Hepp P, Korner J, Kassi JP, Verheyden AP, Josten C, et al. Proximal humeral fractures: how stiff should an implant be? A comparative mechanical study with new implants in human specimens. *Arch Orthop Trauma Surg.* 2003;123:74–81.

**Source of Support:** The author(s) received no financial support for the research, authorship, and/or publication of this article.

**Conflict of Interest:** The author(s) declared no potential conflicts of interest with respect to the research, authorship, and/or publication of this article.

For any questions related to this article, please reach us at: [globalresearchonline@rediffmail.com](mailto:globalresearchonline@rediffmail.com)

New manuscripts for publication can be submitted at: [submit@globalresearchonline.net](mailto:submit@globalresearchonline.net) and [submit\\_ijpsrr@rediffmail.com](mailto:submit_ijpsrr@rediffmail.com)

