



## A Morphometric Study of The Odontoid Process of Axis Vertebra in North Indian Population

Javed Alam<sup>1</sup>, Ram Sagar Yadav<sup>2</sup>, Vipin Kumar<sup>3</sup>, Chandra Bhushan Chandan\*<sup>4</sup>

1.Tutor, Department of Anatomy, Bhagwan Mahaveer Institute of Medical Sciences, Pawapuri, Nalanda, Bihar (India).

2.Junior Resident, Department of Anatomy, Indira Gandhi Institute of Medical Sciences, Patna, Bihar (India).

3.Professor and Head, Department of Anatomy, Heritage Institute of Medical Sciences, Varanasi, U.P, (India).

4.Senior Resident, Department of Anatomy, Indira Gandhi Institute of Medical Sciences, Patna, Bihar (India).

\*Corresponding author's E-mail: [rkps198101@gmail.com](mailto:rkps198101@gmail.com)

Received: 06-01-2024; Revised: 23-02-2024; Accepted: 02-03-2024; Published on: 15-03-2024.

### ABSTRACT

**Background:** The axis vertebra has a unique feature called the odontoid process that sets it apart from the other cervical vertebrae. Fractures of the axis vertebra are common, and surgery to repair them is risky. Therefore, it is crucial to have a solid understanding of the anatomy before performing the surgery. The aim of this study was to measure the precise morphometric parameters of the odontoid process of the axis vertebra.

**Materials and Methods:** To conduct this study, 50 fully ossified human axis vertebrae, of unknown gender and age, were analyzed using a cross-sectional design. Various dimensions of the odontoid process were measured, including its anterior height, anteroposterior (AP) diameter, maximum width, width, and dens axis sagittal angle. A digital vernier caliper and conventional goniometer were used for measuring different morphometry of the odontoid process. The collected data was tabulated and statistically analyzed using GraphPad Prism version 4.03.

**Results:** In our study, we found that the average height of the odontoid process of the axis vertebra was  $14.55 \pm 1.07$  mm, while the anteroposterior (AP) diameter was  $9.98 \pm 0.85$  mm. The maximum width of the odontoid process was  $10.10 \pm 0.82$  mm, and the average width was  $9.16 \pm 1.00$  mm. Additionally, the dens axis sagittal angle was found to be  $13.18 \pm 4.80$  degrees.

**Conclusions:** To help surgeons avoid and minimize complications like vertebral artery injury, cranial nerve damage, and injury to other vital structures when performing any surgical or interventional procedure around the cranio-vertebral region, the present study provided us with important anatomical data on various parameters of the axis of Indian origin.

**Keywords:** Odontoid process, Vernier caliper, Axis vertebrae, Morphometry.

### INTRODUCTION

The vertebral column of an adult human is composed of thirty-three vertebrae divided into five regions: cervical, thoracic, lumbar, sacral, and coccygeal.<sup>1</sup> The second cervical vertebra axis has unique features such as an odontoid process and superior articular facets. The atlas rotates on the atlantoaxial joint, which is formed by the axis and permits the head to move more freely.<sup>2,3</sup> The axis is a vital component of the craniocervical junction and comprises the tip, body, neck, and base.<sup>4</sup> Clinicians in the fields of diagnosis, treatment, and surgery should be aware of the structural differences of the axis.<sup>5</sup> The cervical region, which connects the head and body, is the most flexible part of the vertebral column and contains many important structures. Conservative measures, surgery, or a combination of both can be used to treat dense axis fractures. Surgical interventions may include plates and screws osteosynthesis, fusion of the C1-C2 vertebrae, or the use of one or two screws to fix the dens fracture of the axis.<sup>6</sup> The application of the ideal screw depends on the type of fracture and the structure of the odontoid process.<sup>7</sup> Approximately 10-14% of all cervical region fractures are caused by a dens fracture of the axis.<sup>8</sup> To make the correct diagnosis and treatment plan, it is

important to understand the distinct anatomy and architecture of the axis, specific fracture patterns, and the mechanism and biomechanics of the dens. For surgical procedures involving the odontoid process of the axis vertebra, knowing various morphometric parameters is crucial.<sup>9,10</sup> Precise morphometric understanding is also required for the structural properties of the materials employed in the operation, including the thickness and length of the screw. It is important to know the key landmarks to reduce the time needed for surgery, minimize the occurrence of complications, and identify variations among different populations before the procedure. It should be noted that even small changes in the craniocervical region can have serious consequences due to its complex structure. Several surgical techniques require the use of standard landmarks for placing components such as screws and plates.

### Aims and objective

The objective of this present study was to measure the detailed morphometric parameters of the odontoid process of the axis vertebra.



**MATERIALS AND METHODS**

In the current work, fifty ossified dried human axis vertebrae of unknown gender and age were examined in a cross-sectional fashion. These axis vertebrae were preserved well and were complete in all aspects, making them suitable for accurate morphometric observations of the odontoid process. They belonged to adult individuals and were obtained from the Departments of Anatomy of different medical colleges of Bihar.

**Exclusion criteria:** Any bones with severe abnormalities impacting the odontoid process, healed fractures, considerable destruction, or fragmentation were not included in the study. For the investigation, only undamaged axis vertebrae devoid of congenital defects, osteophytes, or physical trauma were used.

A digital vernier calliper, with a 0.01 mm sensitivity and a 0.01 mm least count detected, was used to obtain two linear measurements. A standard goniometer was used to measure each angular parameter. The analysis took into account the average of the two measurements.

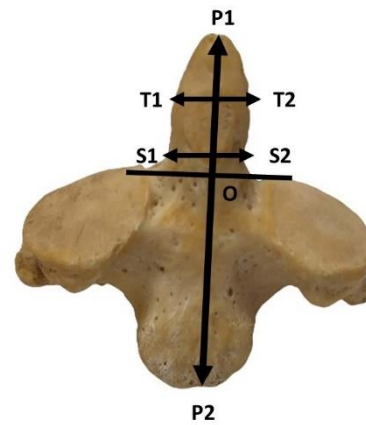
The following parameters were studied:

- The anterior height of the odontoid process:** This measurement is taken from the highest point of the odontoid process i.e. tip of the dens to the arbitrary horizontal line that passes the superior border of the superior articular facets. (P1O in Figure 1).
- Anteroposterior (AP) diameter of the odontoid process:** This is the measurement taken from the anterior surface to the posterior surface of the odontoid process.
- Maximum width of the odontoid process:** This measurement is taken as the maximum transverse width on the anterior surface from one end to the other end (T1T2 in Figure 1).
- Width of the odontoid process:** This is the smallest distance on the front surface measured from end to

end at the point where the dens and vertebral body meet (S1S2 in Figure 1).

- The Dens Axis Sagittal Angle:** This is the angle formed by a vertical line on a sagittal plane and an axis that runs longitudinally via the Dens Axis. A mini-inclinometer is used to measure this angle.

The data was collected, tabulated, and statistically analyzed using GraphPad Prism version 4.03. Mean and standard deviation were used to express continuous variables in this study.



**Figure 1:** Showing different points used for the morphometric measurement of the odontoid process.

[P1O: Anterior height; T1T2: Maximum width; S1S2: Width of the odontoid process]

**RESULTS**

In our study, we found that the average height of the odontoid process of the axis vertebra was 14.55±1.07 mm, the anteroposterior (AP) diameter was 9.98±0.85 mm, and the maximum width of the odontoid process was 10.10±0.82 mm. Additionally, we observed that the average width of the odontoid process was 9.16±1.00 mm, and the dens axis sagittal angle was 13.18±4.80 degrees. (Table:1).

**Table 1:** Showing different morphometric parameters of the odontoid process

Sr. No.	Parameters	Mean (mm) ± SD	Range (mm)
1.	Anterior Height	14.55±1.07	11.92-16.87
2.	Anteroposterior (AP) diameter	9.98±0.85	8.43-12.52
3.	Maximum Width of Odontoid Process	10.10±0.82	8.64-12.34
4.	Width of Odontoid Process	9.16±1.00	7.27-11.21
5.	The Dens Axis Sagittal Angle (in degree)	13.18±4.80	2°-26°

**DISCUSSIONS**

The axis bone is distinguished by its specialized superior articulating facets and dens or odontoid processes that extend upwards from its body. Precise measurements and understanding of the bone's form are crucial for assessing various clinical issues.<sup>11</sup> Multiple surgical procedures,

including interlaminar clamping, interspinous wire, and plate and screw fixation, are required to treat instability in the atlantoaxial complex and occipito-cervical junction caused by traumatic and non-traumatic disorders. While transpedicular screw fixation in the cervical column has several benefits, there is an ongoing debate regarding

potential risks. Incorrect pedicle screw implantation may harm adjacent critical tissues such as the spinal cord, nerve roots, cranial nerves, and vertebral arteries.<sup>12</sup> With the development of new internal fixing techniques, there are indications that our knowledge of the geometry and size of the axis is improving.<sup>11</sup> It is important to consider the

morphometric parameters of the odontoid process of the axis vertebra during various surgical procedures. In Table 2, we have compared the parameters of the odontoid process from our study to those reported by other researchers in previous studies.

**Table 2:** Showing comparison of different morphometric parameters of the odontoid process observed by other authors

Authors (Year)	Anterior Height (mm)	Anteroposterior (AP) diameter (mm)	Width of Odontoid Process (mm)	The Dens Axis Sagittal Angle (in degree)
Doherty & Heggeness <sup>11</sup> (1995)	---	11.2	10.8	---
Xu et al. <sup>13</sup> (1995)	Male: 15.5±1.8 Female: 14.6±1.5	Male: 10.3±0.7 Female: 9.6±0.9	Male: 10.0±0.9 Female: 10.0±0.9	---
Naderi et al. <sup>14</sup> (2006)	15.5±1.8	11.3±1.0	10.5±0.9	---
Senegul & Kodiglu <sup>12</sup> (2006)	14.5	---	11.2	9.7
Gosavi S, Swamy <sup>15</sup> (2012)	14.86	9.92	9.28	---
Singla et al <sup>16</sup> (2015)	14.66±1.37	10.1±0.91	9.32±1.05	13.23±4.36
Teo et al <sup>17</sup> (2017)	17.8	9.4	12.4	59.7
Yousuf et al <sup>18</sup> (2023)	15.8	10.7	10.3	52.2
Present study (2024)	14.55 ± 1.07	9.98 ± 0.85	9.16 ± 1.00	13.18 ± 4.80

Our observations are very near to the findings of Naderi et al.<sup>14</sup>, Senegul & Kodiglu<sup>12</sup>, and Singla et al<sup>16</sup>. The discrepancies observed in the parameters between research could potentially be attributed to the disparities in the ethnic backgrounds of the vertebrae included in each study. In the event of a fracture, it is crucial to determine the diameter and length of the odontoid process when choosing between using one or two screws. A thorough understanding of the technical aspects and bone quality is essential before performing a surgical fixation. These variables dictate how the odontoid process fracture line is treated.<sup>19</sup> When the fracture happens at the base of the odontoid process where it connects to the axis's body, the best course of treatment is up for debate. The typical process entails posterior fusion arches of the axis and atlas, but for stabilization to be effective, this may need extra external immobilization. Although this method improves spinal stabilization, it has drawbacks in that it limits the normal rotation between the atlas and axis, which typically accounts for over half of the cervical spine's normal axial rotation.<sup>16</sup>

**Limitations of the study:** The age and sex of the axis vertebra were not examined in this investigation due to its unavailability.

## CONCLUSIONS

The present study has provided crucial anatomical data on various parameters of the axis of Indian origin. This data can help surgeons minimize complications such as vertebral artery injury, cranial nerve damage, and injury to

other vital structures when performing any surgical or interventional procedure around the cranio-vertebral region.

**Source of Support:** The author(s) received no financial support for the research, authorship, and/or publication of this article

**Conflict of Interest:** The author(s) declared no potential conflicts of interest with respect to the research, authorship, and/or publication of this article.

## REFERENCES

- Moore KL, Dalley AF, Agur AMR. Aradığınız Tüm Tıp Kitapları. Istanbul: Nobel Tıp Kitabevleri; 2015:1136.
- William M, Newell RLM, Collin P. The back: cervical vertebrae, in Gray's Anatomy, Standring S, Ellis H, Haely JC, and Williams A, Eds., Elsevier Churchill Livingstone, London, UK, 39th edition, 2005:742-6.
- Madawi AAS, Solanki G, Casey ATH, Crockard HA. Variation of the groove in the axis vertebra for the vertebral artery. J Bone Joint Surg B. 1997;79(5):820-3.
- Korres DS. Fractures of the odontoid process. In: Korres DS, editor. The axis vertebra. Berlin: Springer-Verlag; 2013:45-59.
- Akobo S, Rizk E, Loukas M, Chapman JR, Oskouian RJ, Tubbs RS. The odontoid process: a comprehensive review of its anatomy, embryology, and variations. Childs Nerv Syst. 2015;31:2025-34.
- Cramer GD. The cervical region. In: Cramer GD, Darby SA, editors. Clinical anatomy of the spine, spinal cord, and ANS. 3rd ed. St.Louis (MO): Mosby; 2014;10:135–209.



7. Böhler J. Anterior stabilization for acute fractures and non-unions of the dens. *J Bone Joint Surg Am.* 1982;64:18-27.
8. Bednar DA, Parikh J, Hummel J. Management of type II odontoid process fractures in geriatric patients; a prospective study of sequential cohorts with attention to survivorship. *J Spinal Disord.* 1995: 166-169.
9. Henry AD, Bohly J, Grosse A. Fixation of odontoid fractures by an anterior screw. *J Bone Joint Surg Br* 1999;81:472-7.
10. Cloché T, Vital JM. Chirurgie des traumatismes récents du rachis cervical. *EMC - Techniques chirurgicales. Orthopedie Traumatologie.* 2016;11:1-28.
11. Doherty BJ, Heggeness MH. Quantitative anatomy of second cervical vertebra. *Spine.* 1995;20(5):513-17.
12. Sengul G, Kodiglu HH. Morphometric anatomy of atlas and axis vertebra. *Turkish neurosurgery.* 2006;16(2):69-76.
13. Xu R, Nadaud MC, Ebraheim NA, Yeasting RA. Morphology of the second cervical vertebra and the posterior projection of the C2 pedicle axis. *Spine.*1995;20(3):259-63.
14. Naderi S, Arman C, Guvencer M, Korkman E, Senoglu M, Tetik S, Arna MN. Morphometric analysis of the C2 body and the odontoid process. *Turkish Neurosurgery* 2006;16:14-18.
15. Gosavi S, Swamy V. Morphometric anatomy of the axis vertebra. *Eur J Anat.* 2012;16(2):98-103.
16. Singla M, Goel P, Ansari MS, Ravi KS, Khare S. Morphometric Analysis of Axis and Its Clinical Significance -An Anatomical Study of Indian Human Axis Vertebrae. *J Clin Diagn Res.* 2015;9(5):AC04-AC09.
17. Teo EC, Hailibkova S, Winkelstein B, Welch W, Holsgrove T, Cazzola D. Morphometric Analysis of Human Second Cervical Vertebrae (Axis). *J Spine.* 2017;6(6)1-7.
18. Yousuf SM, Gulzar S, Itoo MS, Bhat GM, Khan MA. Morphometric study of dens and its clinical importance. *Int J Res Med Sci* 2023;11:1268-71.
19. Daher MT, Daher S, Nogueira-Barbosa MH, Defino HLA. Computed tomographic evaluation of odontoid process: implications for anterior screw fixation of odontoid fractures in an adult population. *Eur Spine J.* 2011;20:1908-14.

For any questions related to this article, please reach us at: [globalresearchonline@rediffmail.com](mailto:globalresearchonline@rediffmail.com)

New manuscripts for publication can be submitted at: [submit@globalresearchonline.net](mailto:submit@globalresearchonline.net) and [submit\\_ijpsrr@rediffmail.com](mailto:submit_ijpsrr@rediffmail.com)

