



## EFFECT OF AQUEOUS EXTRACT OF *ABRUS PRECATORIUS* LEAF ON DNBS - INDUCED INFLAMMATORY BOWEL DISEASE (IBD)

Anant Solanki, Maitreyi Zaveri\*

Department of Pharmacognosy, K. B. Institute of Pharmaceutical Education and Research, Kadi Sarva Vishwavidyalaya, Gandhinagar, India.

\*Corresponding author's E-mail: [khandharmaitreyi@gmail.com](mailto:khandharmaitreyi@gmail.com)

Accepted on: 26-07-2012; Finalized on: 29-09-2012.

### ABSTRACT

In certain tribal regions people chew *Abrus precatorius* leaf for the relief of the mouth ulcer. Therapeutic properties of *Abrus precatorius* leaf was reported in ancient literature as anti-inflammatory or ulcer healing. Hence, the present research work performs study of aqueous leaf extract of *A. precatorius* to achieve optimum inflammatory bowel disease activity. Here, 2, 4 dinitrobenzenesulphonic acid induction of inflammatory bowel (DNBS) - induced inflammatory bowel disease experimental model used to evaluate the aqueous extract of leaf of *A. precatorius* for its anti-inflammatory activity. Treatment of animals with aqueous extract of *A. precatorius* leaf with two different dose levels (300mg/kg and 500mg/kg) was performed and found that animals treated with *A. precatorius* possess marked activity to cure of inflammatory bowel disease and could have a promising role in the treatment of inflammatory bowel disease induced by DNBS. In the colon homogenate malondialdehyde (MDA), superoxide dismutase (SOD), reduced glutathione (GSH), catalase (CAT) and nitric oxide (NO) levels were measured. Rats treated with only DNBS showed higher MDA, NO and lower SOD, GSH, and CAT activity as compared to the control group. Treatment with aqueous extract of *Abrus precatorius* leaf significantly declined CMDI score and decreased the MDA, NO and increased the SOD, GSH, CAT activity. Based on our results we concluded that aqueous extract of *A. precatorius* leaf has a significant protective effect in the IBD in rats that was comparable to that of 5-amino salicylic acid (100 mg/kg) and may be because of the presence of saponins, flavonoids, terpenoids, and phenolic compounds.

**Keywords:** Anti-inflammatory, plant extract, *Abrus precatorius*.

### INTRODUCTION

The search for new pharmacologically active agents from natural resources such as plants, animals and microbes led to discovery of many clinically useful drugs over the past two decades. Inflammatory bowel disease (IBD)<sup>1</sup> describes two major chronic, nonspecific inflammatory disorders of the gastrointestinal (GI) tract, Ulcerative colitis (UC) and Crohn's disease (CD), the causes of which remain unknown. Ulcerative colitis is an inflammatory disease of the large intestine. Ulcers form in the inner lining, or mucosa, of the colon or rectum, often resulting in diarrhea, blood, and pus. Ulcerative colitis affects the colon and rectum and typically involves only the innermost lining or mucosa. Inflammatory bowel disease is thought to result from inappropriate and ongoing activation of the mucosal immune system driven by the presence of normal luminal flora. This aberrant response is most likely facilitated by defects in both the barrier function of the intestinal epithelium and the mucosal immune system. Mechanisms involved in pathogenesis of Inflammatory bowel disease are immune response and inflammatory pathways, the activation of central immune-cell response<sup>2</sup>, genetic factors<sup>3</sup>, histamine in pathogenesis of inflammatory bowel disease<sup>4</sup>, mast cell proteases in pathogenesis of IBD, infectious factors in pathogenesis of IBD and oxidative stress.

In certain tribal regions people chew leaf of *Abrus precatorius* for the relief of the mouth ulcer. It also contains tri-terpenoid, saponins and the leaf of *Abrus precatorius* are used in the treatment of inflammation,

ulcers, wounds, throat scratches and sores since many years. So, present study was designed to evaluate the effects of aqueous extract of *Abrus precatorius* leaf on inflammatory bowel disease (IBD).

### MATERIALS AND METHODS

#### Chemicals used

Chemicals such as 2, 4 dinitrobenzene sulphonic acid (DNBS) and 5-aminosalicylic acid were obtained through Sigma-Aldrich and Sun Pharmaceuticals, Baroda respectively. All other drugs and chemicals used in the study were of analytical grade obtained from were obtained from Finar Chemicals Ltd., Ahmedabad, India.

#### Plant collection and authentication

Fresh leaf of *Abrus precatorius* belonging to the family *Fabaceae* was collected in the month of December, from Vanchetnakendra, Gandhinagar, Gujarat, India. The plant was authenticated by Dr. S.K.Patel, Head of the Botany Department, Government Science College, Gandhinagar, Gujarat, India. The voucher specimen KB/O8/008 was deposited in K. B. Institute of Pharmaceutical Education and Research, Gandhinagar, Gujarat, India.

#### Preparation of aqueous extract: and Phytochemical screening<sup>5-8</sup>

The leaf part of *Abrus precatorius* was separated and dried under sunlight. Dried powdered passed through sieve of 60 mesh (#) size and stored in airtight containers and then used for the present work. Shade dried leaf



powder was extracted by maceration using water. The extract was concentrated using a rotary evaporator at low temperature. The extract was concentrated and dried under controlled temp of 60°C on a water bath and preserved in airtight containers and kept at 4-5°C until further use. The % yield of the aqueous extract was reported. Dried aqueous extract of the leaf was used for further investigation.

### Animals

Wistar albino rats (200-250 g) of either sex were selected for the study. Animals were fed a standard chow diet and water that was freely available under standard condition of a 12 h dark-light cycle, 60±10% humidity and a temperature of 21.5 ±1°C. Coprophagy was prevented by keeping the animals in cages with gratings on the floors. These experiments complied with the guidelines of CPCSEA in our laboratory for animal experimentation. Study was conducted after obtaining approval IAEC No KBIPER/08/109 by our institutional animal ethics committee at K.B.I.P.E.R., Gandhinagar, India.

### Methodology

2, 4 dinitrobenzenesulphonic acid induction of inflammatory bowel Colitis was induced using the technique of DNBS induced colon inflammation, by modification of method described by Cuzzocrea *et al* (2001)<sup>9</sup>. In fasted rats lightly anaesthetized with solvent ether, a 3.5 F catheter was inserted into the colon via the anus until approximately the splenic flexure (8 cm from the anus). In this model, 2, 4 dinitrobenzenesulphonic acid (DNBS 30 mg/rat) was dissolved in 50% ethanol (total volume 0.6ml) and given intrarectally. Thereafter, the animals were kept for 15 minutes in a Trendelenburg position to avoid reflux. After three days colitis was induced. After induction of colitis drug treatment was give for 14 days by intrarectally.

### Drug treatment protocol

The animals were randomly divided into following groups of six animals each.

Group-I Control: Animals received the normal water throughout the study. All animals except that of control group was administered 0.6 ml 2,4- dinitro benzene sulphonic acid (DNBS).

Group-II Negative control: DNBS (2,4-dinitro benzene sulphonic acid) (30mg) intrarectally.

Group-III Animals received equivalent amount of ethanol (0.6 ml) throughout the study.

Group-IV Animals received the standard drug (5-amino salicylic acid 100 mg /kg) daily for 14 days.

Group-V Animals received aqueous extract of leaf of *Abrus precatorius* about 300 mg/kg after induction of colitis.

Group-VI Animals received aqueous extract of leaf of *Abrus precatorius* about 500 mg/kg after induction of colitis.

Average food intake and water intake, body weight were measured on day 1<sup>st</sup> and day 14<sup>th</sup>. On day 15<sup>th</sup>, the animals were weighed and anaesthetized with solvent ether, and the abdomen was opened by a midline incision. The colons from all the group of animals were taken out by making midline incision. After removing from surrounding tissue, the colon was opened out through antimesenteric border. It was then rinsed with water and weighed. They were then spread on a glass slide and the photograph of the luminal side was taken. Later, the colons were cut horizontally into approximately two halves. One half of it was used for preparation of tissue homogenate whereas; the other half was used for histopathological examination.

### Preparation of tissue homogenate

The colon was dissected out, weigh and homogenized (50gm/L) in 50mm/L ice cold potassium phosphate buffer (pH 7.4). Then homogenate was frozen and thawed thrice, then centrifuged at 3000 rpm for 10 min at 4°C for the measurement of malondialdehyde, nitric oxide, reduced glutathione, catalase, superoxide dismutase contents. The resulting supernatant was stored at 20°C until analysis of corresponding enzymes.

The following parameters were investigated.

#### (A) Physical parameters

- (a) Food intake
- (b) Water intake
- (c) Body weight

#### (B) Estimation of free radical generation:

- (a) Nitric oxide (NO)<sup>10</sup> level: Method described by Lisa *et al.*, 2000 was used.
- (b) Malondialdehyde (MDA)<sup>11</sup> level: Method described by Slater *et al.*, 1971 was used.

#### (C) Preventive Antioxidants

- (a) Super oxide dismutase (SOD)<sup>12</sup> level: Method described by Misra *et al.*, 1972 was used.
- (b) Reduced glutathione (GSH)<sup>13</sup> level: Method described by Moron *et al.*, 1979 was used.
- (D) The total protein concentration<sup>14</sup> in each sample was determined as per method described by Lowry *et. al.*, 1952.
- (E) Colon mucosa damage index (CMDI)<sup>9</sup>: The inflammation resulting into redness due to hyperaemia was measured as CMDI.

### Statistical Analysis

Results were presented as mean ± SEM in drug treatment study. Statistical differences between the means of the



various groups were analyzed using paired t-test. Data were considered statistically significant at  $P < 0.05$ . Statistical analysis was performed using Sigma stat statistical software.

## RESULTS

### Phytochemical screening

The preliminary phytochemical screening of the aqueous extract of *Abrus precatorius* revealed the presence of alkaloids, flavonoids, steroids, triterpenoids, saponins, phenolic compounds, tannins, and glycosides as phytoconstituents.

### Inflammatory bowel disease

Pretreatment with aqueous extract of leaf of *A. precatorius* at medium and high doses (300 and 500mg/kg) showed significant alteration in the ulcerated mucosa, lamina propria, muscularis with serosa thinning of lamina propria with loss of mucosal glands noted as compared to control group. It showed protection against inflammatory conditions caused mortality in a dose dependent manner. As compared with standard drug 5-amino salicylic acid, 100 mg/kg (ASA) had abolished ulcerated mucosa, laminapropria, muscularis and serosa and offered 100% protection as shown in Figure 1.


In the 2, 4-dinitro benzene sulphonic acid (DNBS: 30mg/rat, intrarectally, single dose), negative control

group treated animals showed severe hyperplasia, necrosis and ulcers on the mucosal surface were observed in the tissue section of colon. These characters reflecting progression of inflammatory bowel disease were less prominent in animals treated with standard drug and aqueous extract of leaf of *A. precatorius* 300 mg/kg and 500 mg/kg dose respectively.

The histological examination of colon after 15 days of the study with aqueous extract of leaf of *A. precatorius* showed significantly lesser hyperemia of the mucosa and damage to intestinal crypts as shown in Figure 2.

The animals that received aqueous extract of leaf of *Abrus precatorius* extract (300 mg/kg and 500mg/kg), 5-aminosalicylic acid (100mg/kg intrarectally) regained in the body weight to significant extent indirectly suggesting the reduction in inflammation of the colon. The food and water intake were also improved as shown in Table 1.

Animals received *Abrus precatorius* leaves and 5-aminosalicylic acid (100 mg/kg, intrarectally) showed significantly lower malondialdehyde level, nitric oxide and higher catalase, superoxide dismutase and reduced glutathione level in colonic tissue than that in animals treated with 2, 4 dinitrobenzenesulphonic acid (DNBS) alone (Table 2). Treatment with aqueous extract of *Abrus precatorius* leaf significantly declined CMDI score.



**Figure 1:** Effect of aqueous extract of leaf of *Abrus precatorius* on colon produced by DNBS induced inflammatory bowel disease in rat after 14 days treatment.

**Table 1:** Effect aqueous extract of leaf of *Abrus precatorius* (300 mg/kg and 500mg/kg) on different parameters in DNBS treated rats.

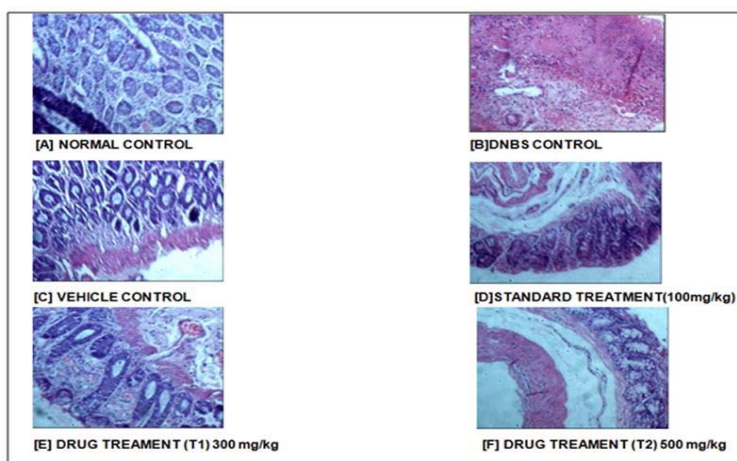
Groups	Water intake	Food intake (gm/day)	% change Body Weight (mg/day)	Colon weight (mg/body weight)
Normal Control	168.333±02.831	131.000±02.193	0.425± 00.483	1729.167±47.640
Negative control DNBS 30 mg/rat	170.667±07.604	101.667±08.419	2.938± 00.794	2607.500±76.070
Vehicle Control 0.6ml ethanol	165.333±02.780	131.667±02.423	0.596±00.379	1810.000±40.680
Standard group 5-ASA 100 mg/kg	155.667±03.548	125.333±03.948	0.749±00.869	1851.167±50.890
Drug treated (300 mg/kg)	167.000±03.478	123.667±01.980	1.088±01.287	2067.500±44.220
Drug treated (500 mg/kg)	172.667±04.108	131.333±03.142	1.425±00.497	2135.500±41.600

Results are expressed as Mean ± SEM; (n=3). The values were found to be significant at  $P < 0.001$  when compared with the control.

**Table 2:** Antioxidant effect of aqueous extract of leaf of *Abrus precatorius* (300 mg/kg and 500 mg/kg) on different parameters in DNBS treated rats.

Groups	MDA Level	NO Level	SOD Level	Catalase Level	GSH Level
Normal Control	0.158 ±0.01	279.772 ±44.22	13.460±2.41	11451.68±1500.70	267.500±13.29
(-ve) control DNBS 30 mg/rat	1.210 ±0.15	1088.88±67.91	02.580±0.59	03365.76±0565.73	031.667±6.37
Vehicle Control 0.6ml ethanol	0.178 ±0.01	365.242±56.76	12.970±2.26	10023.37±1718.85	193.333±9.61
Standard group 5-ASA 100 mg/kg	0.311 ±0.02	633.048±71.90	08.590±2.86	11953.80±2599.17	125.000±14.41
Drug treated (300 mg/kg)	0.351 ±0.02	638.746±51.73	07.830±1.20	11035.45±2307.69	220.000±20.36
Drug treated (500 mg/kg)	0.671 ±0.03	829.630±64.21	09.280±2.00	08423.76±1707.70	214.167±13.88

Results are expressed as Mean ± SEM; (n=3). The values were found to be significant at P<0.001 when compared with the control. Ns= not significant.



**Figure 2:** Effect of aqueous extract of leaf of *Abrus precatorius* on histological changes in colon produced by DNBS induced inflammatory bowel disease in rat after 14 days treatment.

## DISCUSSION

Our study showed that the aqueous extract of leaf of *Abrus precatorius* possesses potent activity in inflammatory bowel disease. *Abrus precatorius* contains different types of phytochemicals such as alkaloids, flavonoids, saponins carbohydrates, steroids and triterpenoids, tannins, phenolic, cycloartane glycosides<sup>15</sup>, proteins and amino acids as phytoconstituents<sup>16</sup>.

Inflammatory bowel disease is a chronic inflammatory disease of gastrointestinal tract. Inflammatory bowel disease comprises the two conditions, Crohn's disease and ulcerative colitis, characterized by chronic recurrent ulceration of the bowel and of unknown etiology. The pathogenesis likely involves genetic, environmental, and immunologic factors<sup>17</sup>. Ulcerative colitis is an inflammatory disease of the large intestine. Ulcers form in the inner lining, or mucosa, of the colon or rectum, often resulting in diarrhea, blood, and pus. Management of inflammatory bowel disease involves mostly the use of 5-aminosalicylic acid and long term use of glucocorticoids is associated with high rates of relapse and unacceptable toxicity<sup>18</sup>. Novel agents such as monoclonal antibodies against TNF- $\alpha$  have been developed and demonstrate clinical efficacy. However, these agents are expensive and not without side effects. Consequently, there is a need for alternative agents that may be equally or more effective as well as being cheaper. There are many reports showing that longstanding inflammation of the colon can be ameliorated by the inhibition of iNOS<sup>19</sup> in experimental Ulcerative colitis<sup>20</sup>. It was reported that there was an

activation of NF $\kappa$ B in inflammatory bowel disease<sup>21</sup>. Cytokines including TNF- $\alpha$  and IL-1 $\beta$  have been shown to be up regulated in inflammatory bowel disease and serve to amplify and perpetuate tissue damage.

*Abrus precatorius* was reported as the contents of glycyrrizic acid which has strong anti-inflammatory and antiulcer activity<sup>22</sup>. Thus, inhibition of NF $\kappa$ B can be expected to have beneficial effect in inflammatory bowel disease<sup>23</sup>. *Abrus precatorius* leaf has also the antioxidant activity. We therefore, evaluated the efficacy of *Abrus precatorius* in animal model of inflammatory bowel disease. The common symptoms observed in inflammatory bowel disease were reduction in food intake and water intake due to reduced tolerance to food and water because of inflammation. Body weight was also reduced as consequence of this. There was increase in colon weight due to inflammation. Here, 2, 4 dinitro benzene sulphonic acid (30mg/rat) administered intrarectally to rats caused significant reduction in food intake, water intake and body weight within 14 days. The animals that received aqueous leaf extract of *Abrus precatorius* (300 mg/kg and 500mg/kg), 5-aminosalicylic acid (100 mg/kg intrarectally) regained in the body weight to significant extent indirectly suggesting the reduction in inflammation of the colon. The food and water intake were also improved.

To further study, the efficacy of *Abrus precatorius* leaves was checked against the reactive oxygen species generated during the colonic inflammation. We

performed malondialdehyde, catalase, GSH, nitric oxide, superoxide dismutase activities in the colonic tissues. Animals received aqueous leaf extract of *Abrus precatorius* and 5-aminosalicylic acid (100 mg/kg, intrarectally) showed significantly lower malondialdehyde level, nitric oxide and higher catalase, superoxide dismutase and reduced glutathione level in colonic tissue than that in animals treated with 2, 4 dinitrobenzenesulphonic acid (DNBS) alone. The antioxidant activity of *Abrus precatorius* leaves was thus confirmed and can be value of reducing the severity of disease. Inflammatory responses by variety of ways increased production of inflammatory mediators and ROS generation<sup>24</sup>. Thus, inflammatory mediators' inhibition or antioxidant effect could be the likely mechanism for the beneficial effects of *Abrus precatorius* leaves in DNBS induced inflammatory bowel disease in rats. However, direct studies to confirm this are required.

### CONCLUSION

In the present work treatment of animals with aqueous extracts of *Abrus precatorius* leaf with two dose levels, so it was found that animals treated *Abrus precatorius* (300mg/kg and 500mg/kg) and 5-aminosalicylic acid (100mg/kg) showed significantly lower malondialdehyde level, nitric oxide level and higher catalase level, super oxide dismutase and reduced glutathione level than that in animals treated with 2,4 dinitrobenzoic acid (DNBS) alone.

It was concluded that, our studies have shown that the leaf of *Abrus precatorius* possesses marked antioxidant activity in cure of ulcerative colitis and could have a promising role in the treatment of ulcerative colitis induced by DNBS.

### REFERENCES

- Ardizzone S, Bianchi Porro G. A practical guide to the management of distal ulcerative colitis. *Drugs* 1998; 55:519-42.
- Fiocchi C. Inflammatory bowel disease: etiology and pathogenesis. *Gastroenterology* 1998; 115:182-205.
- Ogura Y, Bonen DK, Inohara N: A frameshift mutation in NOD2 associated with susceptibility to Crohn's disease. *Nature* 2001; 411: 603-606.
- Knutson L, Ahrenstedt O, Odland B and Hallgren R. The jejunal secretion of histamine is increased in active Crohn's disease. *Gastroenterology* 1990; 98: 849-854.
- Sim SK. Medicinal Plant Alkaloids. University of Toronto Press; 1969: 9-10.
- Geissman A. Modern Methods of Plant Analysis, Heidelberg, Berlin, Springer Verlag. 1955; 3:471.
- Robinson T. The Organic Constituents of Higher Plants, their Chemistry and Interrelationships. Minneapolis 15 Minn., Burgess publishing company. 1964:64.
- Anonymous. WHO Guidelines. Delhi, A.I.T.B.S. Publishers and distributors, 2002; 1:45-46.
- Cuzzocrea S, McDonald MC, Mazzon E. Calpain inhibitor-I reduce colon injury caused by dinitrobenzene sulphonic acid in the rat. *Gut* 2001; 48:478-488.
- Lisa A, Rindnour, Julia E, Micheal A H. A Spectrophotometric method for the direct detection and quantification of nitric oxide, nitrates and nitrite in cell culture media. *Anal Biochem* 2000; 281:223-229.
- Slater TF, Sawyer BC. The stimulatory effects of carbontetrachloride and other halogenoalkanes or peroxidative reactions in rat liver fractions In vitro. *Biochem J* 1971; 123: 805-814.
- Misra HP, and Fridovich I. The role of superoxide anion in the autoxidation of epinephrine and a simple assay for superoxide dismutase. *J Biol Chem* 1972; 247:3170 - 3175.
- Moron MS, Depierre JW, Mannervik B. Levels of glutathione, glutathione reductase and glutathione S-transferase activities in rat lung and liver. *Biochem Biophys Acta* 1979; 582:67-78.
- Lowery OH, Rose BNJ, Farr A, Randall R. Protein determination with Folin's reagent. *J Biol Chem* 1954; 195:133-140.
- Fullas F, Choi YH. Non toxic plants. 1989; 2:6-8.
- Rajaram N and Janardhanan K. The chemical composition and nutritional potential of the tribal pulse, *Abrus precatorius* L. *Plant Foods Hum Nutr* 1992; 42(4):285-290.
- Sartor RB. Current concepts of the etiology and pathogenesis of Ulcerative colitis and Crohn's disease. *Gastroenterol Clin North Am* 1995; 24: 475-485.
- Scudamore CL, Jepson MA, Hirst BH, Miller HR. The rat mucosal mast cell chymase, alters epithelial cell monolayer permeability in association with altered distribution of the tight junction proteins and occludin. *Eur J Cell Biol* 1998; 75: 321-330.
- Perner A, Nordgaard I, Matzen P. Colonic production of nitric oxide gas in Ulcerative colitis, collagenous colitis and uninfamed bowel. *Scand J Gastroenterol* 2002; 37:183-188.
- Taylor BS, Shao L, Gambotto A. Inhibition of cytokine-induced nitric oxide synthase expression by gene transfer of adenoviral I kappa B alpha. *Surgery* 1999; 126:142-147.
- McCafferty DM. Peroxynitrite and inflammatory bowel disease. *Gut* 2000; 46:436.
- Nathan C et al. Nitric oxide as a secretory product of mammalian cells. *Gastroenterology J*, 1996, 3051 – 3064.
- Miller MJ, Thompson JH, Zhang XJ. Role of inducible nitric oxide synthase expression and peroxynitrite formation in guinea pig ileitis. *Gastroenterology* 1995; 109:1475-1483.
- Wang JP, Hsu MF, Chang LC, Kuo JS, Kuo SC. Inhibition of plasma extravasation by abruquinone A, A natural isoflavonequinone isolated from *Abrus precatorius*. *Europ J Pharmacol* 1995; 273:73-81.

\*\*\*\*\*

