



Wound Healing Activities of *Melastoma malabathricum* Leaves Extract in Sprague Dawley Rats

Nurdiana S.*, Marziana, N.

Faculty of Applied Sciences, Universiti Teknologi MARA, 40450 Shah Alam, Selangor, Malaysia.

*Corresponding author's E-mail: nurdiana7251@salam.utim.edu.my

Accepted on: 02-05-2012; Finalized on: 31-05-2013.

ABSTRACT

Melastoma malabathricum or locally known as senduduk have a potential in healing several diseases due to their phytochemical constituent. The study was designed primarily to determine the presence of flavonoids and tannins, and evaluating wound healing properties of *M. malabathricum*. The presence of flavonoids and tannins in aqueous extract of *M. malabathricum* leaves was screened using qualitative and quantitative methods. There was obviously high concentration of flavonoids (10.8 mg/ml) than tannins (6.2 mg/ml) in the extract. The extract then been tested for the wound healing activities. About twelve *Sprague dawley* rats, each with 1 cm² of excision on their back were divided into four groups which received different treatments. The first group was treated with aqueous extract of *M. malabathricum* leaves while Group 2 and Group 3 represent as the positive controls were treated with conventional drugs, Povidern and Actiflavin respectively. The fourth group as the negative control received saline. The percentage of wound contraction was recorded for 15 days where *M. malabathricum* showed the highest percentage of contraction (93%), followed by flavin (88%), Povidern (86%) and negative control (77%). The scar appearance on the wound site was also been observed. Rats which treated by *M. malabathricum* leaves extract showed the finest scar with little inflammation and no microbe infection compared to other treatments. In conclusion, the aqueous extract of *M. malabathricum* leaves showed the highest concentration of flavonoids and also the presence of tannins had improve wound healing activities for the excised wound.

Keywords: *Melastoma malabathricum*, wound healing, flavonoids, tannins.

INTRODUCTION

Wound healing activity was rarely to be concerned by the public. Only 51% of people worldwide with a chronic wound have had a diagnostic examination but just half of them were well treated.¹ Besides of feeling pain and suffering as the wound healing process being delayed, it also can incur high cost.

There are various drugs or medicine, as well as techniques used to cure the chronic wound. Since centuries ago, the traditional medicines were practiced among people in Africa and Asia. Recently, there was more than 3000 plants are known to have their healing ability on human life. In Malaysia, *Melastoma malabathricum* was used traditionally as an agent for treating a burn skin and wound. Previous work was reported that various part of this plant might be an effective agent as antihelmethic and antispasmodic, anti-inflammatory, antipyretic, anticancer, antioxidant and antihypertensive.² All of these biological properties are believed due to presence flavonoids and tannins.

Study done by manicam *et al.*³ was explained the ability of *M. malabathricum* leaves extract as a wound healing agent. The plant extract was found to reduce the bleeding time; repair the scar formation, pimple and black spot on skin. However, the study failed to relate these properties with the chemical constituents. Hence our study is beneficial as initial work to provide knowledge about relationship of chemical constituents of *M. malabathricum* leaves extract with the wound healing activities.

MATERIALS AND METHODS

Preparation of *M. malabathricum* leaves extract

A fresh leaf of *M. malabathricum* was dried at 50°C for five to seven days. The leaves then were ground into fine texture using the grinder with 1.0 mm filter and soaked in distilled water for 24 hours. The solution then was filtered by using a mesh and filter funnel. The residue was eliminated. The filtrate was freeze-drying for two to three days.

Experimental Design

A total of 12 rats were selected for the experiment. The rats were divided into four groups; with each group consist of three rats. The rats then acclimatized to the laboratory environment for seven days. All of the rats then were excised on their back of body with about 1 cm² area by using scalpels. The first group of the rats that were treated with aqueous extract of *M. malabathricum*, second and third group of rats were treated with commercial products, flavin and povidern respectively. The fourth group as a negative control group were administered by saline. All groups were treated for two weeks. The wound area was measured on the 3rd, 6th, 9th, 12th and 15th day. Percentage of wound contraction was calculated using this formula:

Phytochemical screening

Flavonoids content

A gram of the leaves extract was added with 100 ml of distilled water. Then one milliliter of the solution was taken and mixed with a few drops of diluted sodium



hydroxide. The changes of colour from yellow into colourless indicated the presence of flavonoids.

Tannins content

A gram of the leaves extract was added with 100 ml distilled water. About three millilitres of the solution were taken and mixed with a few drops of 1% lead acetate. A yellow precipitate indicated the presence of tannins.

Total tannins content

This procedure is based on Manicam *et al.*³ with slight modifications. One ml aliquots of the leaves extract was transferred into 10 ml volumetric flask. Then, 0.5 ml Folin-ciocalteu reagent and one ml of sodium carbonate was put into the flask and the volume was made up to 10 ml with distilled water. The absorbance was measured at 720 nm against the blank. The total tannin content was determined by using calibration curve against standard tannic acid and expressed as mg tannic acid equivalents per gram of crude extract.

Total flavonoids content

One gram of the crude extract was added with 4 ml of distilled water in 10 ml volumetric flask. To the mixture, 0.3 ml 5% NaNO₂ was added. After five minutes, 0.3 ml 10% AlCl₃ was added. After six minutes, 2 ml of 1M NaOH was added and the total volume was made up to 10 ml with distilled water. The absorption was read at 510 nm using spectrophotometer against blank sample which consisted of 5 ml extract solution with 5 ml methanol without AlCl₃. The total flavonoid content was determined using a standard curve with catechin as standard. Total flavonoid content is expressed as mg of catechin equivalents per gram of extract.

Statistical analysis

Data was represented as mean ± S.E.M. Student t-test and ANOVA analysis were applied to test the significance of differences between the results of the treated, untreated and control group.

RESULTS AND DISCUSSION

Qualitative and quantitative phytochemical screening

Flavonoid and tannin were reported to be involved in wound healing process by having anti-inflammatory and antioxidant activities.^{5,6} Recent study on plant medicine had successfully described the correlation of anti-inflammatory, antioxidant and antimicrobial properties to the presence of flavonoid and tannin. It is expected that a higher percentage of flavonoid and tannin is able to speed up wound healing process. Therefore, the qualitative and quantitative methods were used to examine the presence and concentration of flavonoids and tannins in aqueous extract of *M. malabathricum*.

The presence of flavonoids and tannin content in the aqueous extract of *M. malabathricum* leaves was obtained as showed in Figure 1. After tested with their own indicator, the extract showed the presence of both

flavonoids and tannin. For the flavonoids test, the leaves extract showed decolourization of brownish color to clear yellowish solution after being tested with sodium hydroxide (NaOH). While for the tannin test, the yellow precipitation occurred at the bottom of the mixture of the leaves extract and lead acetate.

The quantitative determination of total flavonoid content of the extracts was expressed as percentage of catechin per 10 ml of aqueous extract showed the content values of 10.8 w/v. While for total tannin content, expressed as mg tannic acid equivalents and per 10 ml of sample showed the content values of 6.2 w/v. The result showed that aqueous extract of *M. malabathricum* leaves contain less tannin than flavonoids. It may be due to the solubility of the tannin in aqueous solution is less than flavonoids. The flavonoids has more hydroxyl group (free hydrogen) to be attracted and extracted in water.⁴



(a) crude extract



(b) flavonoids test



(c) tannin test

Figure 1: The phytochemical screening test of flavonoids and tannin in the aqueous extract of *M. malabathricum* leaves. (a) crude extract before added any indicator; (b) crude extract was mixed with NaOH; (c) crude extract was mixed with lead acetate. The quantitative determination of total flavonoid content of the extracts was expressed as percentage of catechin per 10 ml of aqueous extract showed the content values of 10.8 w/v. While for total tannin content, expressed as mg tannic.

Percentage of Wound Contraction

The percentage of wound contraction and a duration for it to heal is totally depends on the metabolism of the organisms, environment and treatment it takes. Theoretically, in the hygiene environment, wound can

have full contraction and recovery within 14 days.⁷ Hence, this study was conducted for about 15 days.

Figure 2 showed the rate of wound contraction rapid initially on the non-treated group, but then it started to slow down after the third day. On the other hand, the *M. malabathricum* leaf extract treated group showed slow contraction on the first three days (10%), but then speed up on third day with 59% contraction. These findings clearly described that wound was supposed to allow healed by natural immune system as it was the best way to treat the wound for the first three days. The contraction of the wound occurred due to the presence of growth factor that helps the tissue to repair.⁸ The application of the extract or the drugs may lead to slow down the growth factor activities for wound healing process.

But then, when the extract was applied for about five days, the wound contraction showed the significant difference with non-treated group. This difference may occur due to the reaction of the plant bioactive constituents' contents in the leaves extract. Previous work was reported^{10,11} that tannins are able to penetrate and diffuse into the microbe with no outer membrane which finally destroy the microbes. Aligned with this finding, we hypothesize that the ability of the *M. malabathricum* leaf extract to speed up wound contraction might be due to their antimicrobial potential.

However, the percentage of the wound contraction of the extract treated group had increased daily with slow increment on day six and onward. This activity may be due to the phase of tissue remodelling where the new epithelial starts to appear and being mature¹¹. On the fifteenth day, the percentage of wound contraction for extract treated group was 93% compared to the non-treated group which was only 77%. The aqueous extract of *M. malabathricum* leaves showed significantly increased healing by wound contraction when compared to the control group. Increased in the wound healing is indicative of improved collagenation which contributes to healing, enhances epithelization and promotes wound contraction.¹⁴

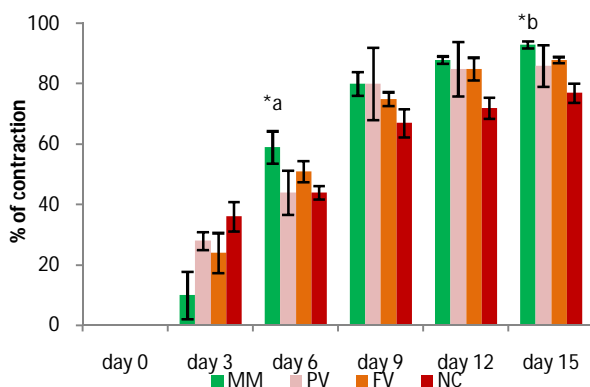


Figure 2: The percentage of wound contraction within 15 days of the observation. Data are expressed as means \pm SEM; n = 3; *a = statistical significant versus Poviderm ($p < 0.05$); *b = statistical significant versus negative control

($p < 0.05$); MM (*M. malabathricum* leaves extract treatment), PV (Poviderm treatment), FV (Actiflavin treatment), NC (no treatment).

Scar Appearance

Scar can be defined as a mark left on injured tissue.¹³ The desirable healing activity is as the site of wound closure shows the flexible and fine scar with high tensile strength. Figure 3 showed the scar appearance on the rat which received different treatments. Figure 3(a) showed the formation of scar on the rat that received the *M. malabathricum* leaves extract. After 15 days of treatment, the scar had no form of lesion with less inflammation and had no bacterial infection. From this study, *M. malabathricum* leaves extract was known to have high concentration of flavonoids and tannins. Both of these chemical constituents gave anti-inflammatory and antimicrobial properties that made the scar to appear better than other treatment groups. They obviously can control the microbial colonization and subsequent proliferation thus promoting the healing of the wound.¹⁴ These bioactive constituents also can inhibit the pro-inflammation, prostaglandins and cyclooxygenase that mediate from macrophages in process on wound healing which then can reduce the inflammation of wound.^{15,16}

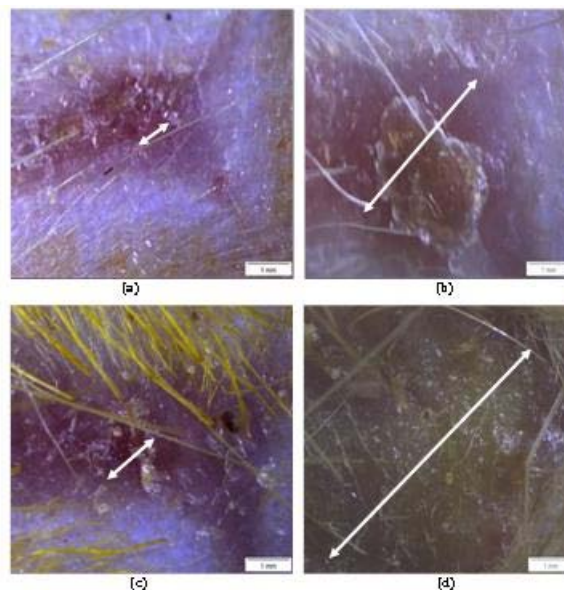


Figure 3: The scar appearance after 15 days of treatment. (a) *M. malabathricum* treatment; (b) Poviderm treatment; (c) Flavin treatment; and (d) non-treated wound. (<->) length of scar

Figure 3(b) and (c) showed the scar appearance of the positive control groups. Both groups were treated with conservative drugs; Poviderm and Actiflavin, respectively. The scar of rat that have been treated with Poviderm appeared to have inflammation and microbial infection as there was lesion and pus formation on the scar, which was comparable with rat that have been treated with flavin have less inflammation and microbes infection. This may be appear due to poviderm is the drug with cream base while flavin is water basis; same as the leaves extract

of *M. malabathricum*. Previous study done by porter *et al.*¹⁷, showed water basis medicine can be easily diffused and react with the protein of skin and help the fibroblast formation. Therefore, the protein can enhance epithelization and collagen distribution rapidly, and make the scar appeared well.

CONCLUSION

The present study possess that an aqueous extract of *M. malabathricum* leaves as the best treatment for healing an excision wound compared to conventional drugs, Povidern and Actiflavin. These findings might be due to the high presence of flavonoids and tannin in this extract which are always associated with antioxidant, anti inflammatory and antimicrobial activity. The application of *M. malabathricum* had effectively increased (93%) the contraction of wound after 15 days which is significant compared to the nontreated wound. The extract was also able to improve the scar appearance at the end of the study.

REFERENCES

1. Gottrup F, Multidisciplinary wound healing concepts, EWMA Journal, 3, 2003, 5-11.
2. Sulaiman MR, Somchit MN, Israf DA, Ahmad Z, Moin S, Antinociceptive effect of *Melastoma malabathricum* ethanolic extract in mice, Fitoterapia, 75, 2004, 667-672.
3. Manicam C, Abdullah JO, Seman Z, In vitro anticoagulant activities of *Melastoma malabathricum* Linn. Aqueous leaf extract: A preliminary novel finding. Journal of Medicinal Plants Research, 4, 2010, 1464-1472.
4. Patel A, Patel A, Patel NM, Estimation of flavonoid, polyphenolic content and *in-vitro* antioxidant capacity of leaves of *Tephrosia purpurea* Linn. (Leguminosae). International Journal of Pharma Sciences and Research, 1, 2010, 66-77.
5. Ramamoorthy PK, Bono A, Antioxidant activity, total phenolic and flavonoid content of *Morinda citrifolia* fruit extracts from various extraction process. Journal of Engineering Sciences and Technology, 12, 2007, 70-80.
6. Atanassova M, Georgieva S, Irancheva K, Total phenolic and total flavonoid contents, antioxidant capacity and biological contaminants in medicinal herbs. Journal of University of Chemical Technology and Metallurgy, 46, 2011, 81-88.
7. Janis JE, Kwon RK, Lalonde DH, A practical guide to wound healing. Plastic and Reconstructive Surgery, 125, 2010, 230-244.
8. Ilango K, Chitra V, Wound healing and anti-oxidant activities of the fruit pulp of *Limonia acidissima* Linn (Rutaceae) in rats. Tropical Journal of Pharmaceutical Research, 9, 2010, 223-230.
9. Choudhury MD, Nath D, Talukdar AD, Antimicrobial activity of *Melastoma malabathricum* L. Assam University Journal of Science & Technology, 7, 2011, 76-78.
10. Tian F, Li B, Ji B, Yang J, Zhang G, Chen Y, Luo Y, Antioxidant and antimicrobial activities of consecutive extracts from *Galla chinensis*: The polarity affects the bioactivities. Food Chemistry, 113, 2009, 173-179.
11. Watson T, Soft tissue wound healing review. Electrotherapy, 1, 2006, 7.
12. Sorensen T, Smoking and wound healing. EWMA Journal, 3, 2003, 13-15.
13. Gauglitz GG, Korting HC, Pavicic T, Ruzicka T, Jeschek MG, Hypertrophic scarring and keloids: Pathomechanisms and current emerging treatment strategies. Molecular Medicine, 17, 2011, 113-125.
14. Sunilson AJ, James J, Thomas J, Antibacterial and wound healing activities of *Melastoma malabathricum* Linn. African Journal of infectious Diseases, 2, 2008, 68-73.
15. Fawole OA, Ndhlala AR, Amoo SO, Finnie JF, Staden JV, Anti inflammatory and phytochemical properties of twelve medicinal plants used for treating gastro intestinal ailments in South Africa. Journal of Ethnopharmacology, 123, 2009, 237-243.
16. Yam MF, Ang LF, Amee, OZ, Salman IM, Aziz HA, Asmawi MZ, Anti inflammatory and analgesic effects of *Elephantopus tomentosus* ethanolic extract. Journal of Acupuncture Meridian studies, 2, 2009, 280-287.
17. Porter S, The role of the fibroblast in wound contraction and healing. Wound Healing Sciences, 3, 2007, 33-40.

Source of Support: Nil, Conflict of Interest: None.

