



## Effect of Aqueous Extract of *Cola Nitida* (Kola Nut) on Reproductive Functions in Male Albino Rats

Oyedeji K.O.<sup>1</sup>, Bolarinwa A.F.<sup>2</sup>, Adegoke A.O.<sup>3</sup>

<sup>1</sup>Department of Physiology, College of Medicine and Health Sciences, Afe Babalola University, Ado-Ekiti, Nigeria

<sup>2</sup>Department of Physiology, College of Medicine, University of Ibadan, Ibadan, Nigeria.

<sup>3</sup>Department of Pharmaceutical Chemistry, Faculty of Pharmacy, University of Ibadan, Ibadan, Nigeria.

\*Corresponding author's E-mail: [sinaoyedeji@yahoo.com](mailto:sinaoyedeji@yahoo.com)

Accepted on: 04-05-2013; Finalized on: 31-05-2013.

### ABSTRACT

*Cola nitida* (Kola nut) is a caffeine-containing nut native to tropical North African and cultivated extensively in the new world tropics. Several studies have reported its effects on body weight and reduction in body fat without undesirable side effect as well as on gastric secretion, but there is a dearth of information on its effect on reproduction. This study was designed to investigate the effect of its aqueous extract on reproductive parameters in male albino rats. Aqueous extract of *Cola nitida* designated as AECON was prepared using cold maceration. The extract was administered for 30 days for andrological study. Distilled water (0.5 ml) served as the control. Plasma testosterone levels were assayed using ELISA and semen analysis was done microscopically, histology of the testis was done. Data was analysed using ANOVA at  $P < 0.05$ . Treatment of rats with all doses of AECON caused significant decrease in testosterone levels, sperm motility, sperm viability and sperm count relative to the control but there was no significant change in sperm morphology. The testicular histopathological study revealed that there was moderate to severe necrosis with the dissolution of numerous seminiferous tubules in testis. It can therefore be concluded that AECON has deleterious effect on reproductive parameters in male albino rats.

**Keywords:** *Cola nitida*, Sperm count, Testosterone, Sperm motility, Albino rats.

### INTRODUCTION

*Cola nitida* (Kola nut) belongs to the family of *Malvaceae*. It is commonly called kola nut in English language, "Guoro" in Hausa language, "Oji" in Igbo language and "Obi" in Yoruba language.

It is important in various social and religious customs and to counter acts hunger and thirst<sup>1</sup>. It is used as a gesture of peace, friendship and hospitality<sup>2</sup>.

*Cola nitida* administration has been reported to stimulate gastric acid in cats<sup>3</sup>. Its extract has been reported to induce behavioral changes in rodents such as increasing exploratory, general reactivity and locomotor activity in rats<sup>4</sup>. Its extract has also been reported to produce a dose-dependent biphasic effects on locomotion in mice<sup>5</sup>. It has been reported to contain stimulants that prevent fatigue and dispel sleepiness<sup>6</sup>.

However, due to paucity of information from literature on the effect of *Cola nitida* on reproductive parameters in male albino rats, this study therefore aims at investigating the effect of aqueous extract of *Cola nitida* on these reproductive parameters.

### MATERIALS AND METHODS

#### Experimental Animals

Adult male albino rats weighing between 160 g and 180 g bred in the Animal House of Physiology Department, LAUTECH, Ogbomoso were used. They were housed under standard laboratory conditions with a 12 hours daylight cycle and had free access to feed and water; they

were acclimatized to laboratory conditions for two weeks before the commencement of the experiments. All experiments were carried out in compliance with the recommendations of Helsinki's declaration on guiding principles on care and use of animals.

#### Plant Materials

Fresh specimens of *Cola nitida* were bought from Ogbomoso market and authenticated in the taxonomy unit of the department of Pure and Applied Biology, LAUTECH, Ogbomoso.

#### Preparation of the Aqueous Extract of *Cola nitida* (AECON)

Large quantities (1.43 kg) of the fresh samples of *Cola nitida* were washed and cut into smaller bits and air-dried for four weeks, the dried specimens were pulverized using laboratory mortar and pestle.

Weighed portion (480.20 g) of the pulverized specimens were macerated and extracted with distilled water (1:2 wt./vol.) for 72 hours at room temperature (26 – 28°C). The resulting solution was then filtered using a wire-gauze and a sieve with tiny pores (0.25 mm). The distilled water was later evaporated using steam bath to give a percentage yield of 12.4% of the starting material.

Ten grams of the aqueous extract of *Cola nitida* (AECON) was dissolved in 100 ml of distilled water to give a concentration of 0.1 g/ml.



## Experimental Design

Twenty-four animals were randomly divided into four groups with each group consisting of six rats. The four groups of rats were subjected to the following oral treatments once a day for 30 days:

Group I rats received 25 mg/kg BW of AECON

Group II rats received 50 mg/kg BW of AECON

Group III rats receive 100 mg/kg BW of AECON

Group IV rats received 1.0 ml of distilled water as the control group.

Twenty-four hours (day 31) after the last dosing of the four groups, blood samples were collected and the animals were then euthenised by cervical dislocation for semen analysis. Histological preparation of the testes was also carried out.

## Body Weight

Body weight of each rat was monitored on weekly basis.

## Collection of Blood Sample

Blood samples were collected through the medial cantus into EDTA bottles for hormonal assay.

## Hormonal Assay

Plasma samples were assayed for testosterone using the enzyme-linked immunosorbent assay (ELISA) technique using the Fortress kit.

## Semen Collection

The testes were removed along with the epididymides. The caudal epididymides were separated from the testes, blotted with filter papers and lacerated to collect the semen.

## Semen Analysis

**Progressive sperm motility:** This was done immediately after the semen collection. Semen was squeezed from the caudal epididymis onto a pre-warmed microscope slide (27 °C) and two drops of warm 2.9 % sodium citrate was added, the slide was then covered with a warm cover slip and examined under the microscope using X400 magnification. Ten fields of the microscope were randomly selected and the sperm motility of 10 sperms was assessed on each field. Therefore, the motility of 100 sperms was assessed randomly. Sperms were labelled as motile, sluggish, or immotile. The percentage of motile sperms was defined as the number of motile sperms divided by the total number of counted sperms (i.e. 100)<sup>7</sup>.

**Sperm viability (Life/dead ratio):** This was done by adding two drops of warm Eosin/Nigrosin stain to the semen on a pre-warmed slide, a uniform smear was then made and dried with air; the stained slide was immediately examined under the microscope using x400 magnification. The live sperm cells were unstained while the dead sperm cells absorbed the stain. The stained and

unstained sperm were counted and the percentage was calculated<sup>8</sup>.

**Sperm morphology:** This was done by adding two drops of warm Walls and Ewas stain (Eosin/Nigrosin stain can also be used) to the semen on a prewarmed slide, a uniform smear was then made and air-dried; the stained slide was immediately examined under the microscope using x400 magnification<sup>8</sup>. Five fields of the microscope were randomly selected and the types and number of abnormal spermatozoa were evaluated from the total number of spermatozoa in the five fields; the number of abnormal spermatozoa were expressed as a percentage of the total number of spermatozoa.

**Sperm count:** This was done by removing the caudal epididymis from the right testes and blotted with filter paper. The caudal epididymis was immersed in 5ml formol-saline in a graduated test-tube and the volume of fluid displaced was taken as the volume of the epididymis. The caudal epididymis and the 5ml formol-saline were then poured into a mortar and homogenized into a suspension from which the sperm count was carried out using the improved Neubauer haemocytometer under the microscope.

## Testicular Histology

After weighing the testes, they were immediately fixed in Bouin's fluid for 12 hours and the Bouin's fixative was washed from the samples with 70 % alcohol. The tissues were then cut in slabs of about 0.5 cm transversely and the tissues were dehydrated by passing through different grades of alcohol: 70 % alcohol for 2 hours, 95 % alcohol for 2 hours, 100 % alcohol for 2 hours, 100 % alcohol for 2 hours and finally 100 % alcohol for 2 hours. The tissues were then cleared to remove the alcohol, the clearing embedded. Serial sections were cut using rotary microtone at 5 microns (5 µm). The satisfactory ribbons were picked up from a water bath (50-55 °C) with microscope slides that had been coated on one side with egg albumin as an adhesive and the slides were dried in an oven. Each section was deparaffinized in xylene for 1 minute before immersed in absolute alcohol for 1 minute and later in descending grades of alcohol for about 30 seconds each to hydrate it. The slides were then rinsed in water and immersed in alcoholic solution of hematoxylin for about 18 minutes. The slides were rinsed in water, then differentiated in 1 % acid alcohol and then put inside a running tap water to blue and then counterstained in alcoholic eosin for 30 seconds and rinsed in water for a few seconds, before being immersed in 70 %, 90 % and twice in absolute alcohol for 30 seconds each to dehydrate the preparations. The preparations were cleared of alcohol by dipping them in xylene for 1 minute. Each slide was then cleaned, blotted and mounted with DPX and cover slip, and examined under the microscope. Photomicrographs were taken at x40, x100 and x400 magnifications.

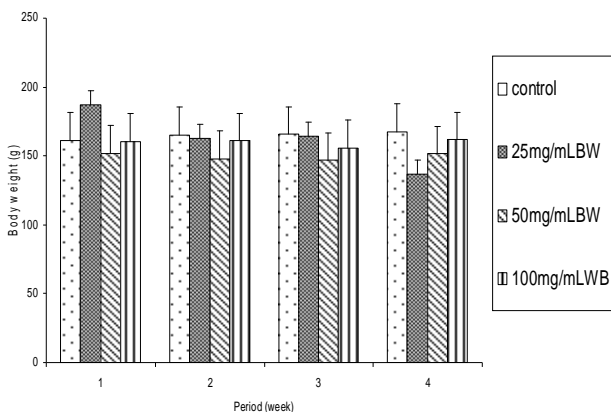
**Statistical Analysis**

The mean and standard error of mean (S.E.M.) were calculated for all values. Comparison between the control and experimental groups was done using one-way analysis of variance (ANOVA) with Duncan's Multiple Range Test. Differences were considered statistically significant at  $p < 0.05$ .

**RESULTS**

**Effect on body weight**

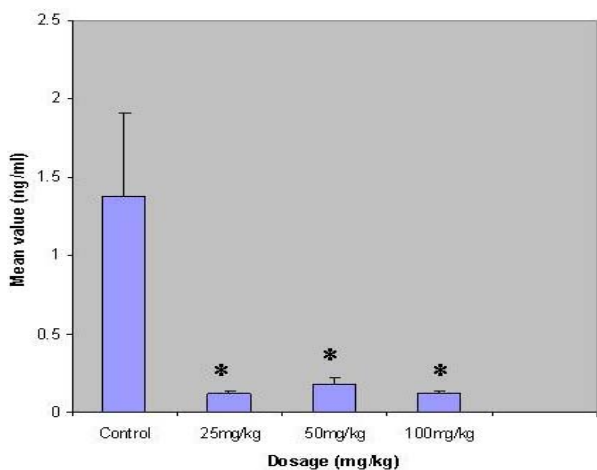
The administration of all doses of AECON (except 25 mg/kg BW) to the rats 30 days caused significant ( $p < 0.05$ ) reductions in body weight relative to the control.



**Figure 1:** Effect of 30 (4 weeks) days treatment with AECON on body weight of male albino rats ( $n=6$ ,  $*p < 0.05$ )

**Effect on Hormonal Levels**

Treatment of rats for 30 days with all the treatment doses of AECON caused significant ( $p < 0.05$ ) decrease in testosterone levels relative to the control.

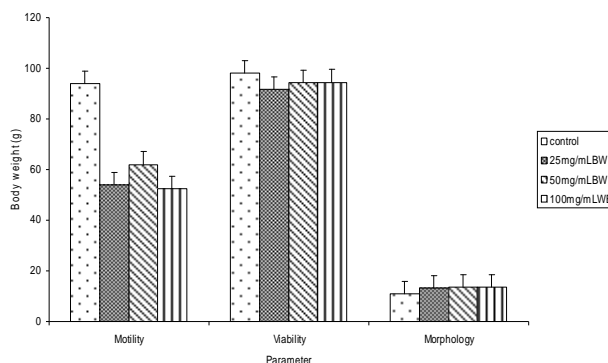


**Figure 2:** Effects of treatment of rats for 30 days with AECON on serum level of testosterone ( $n=6$ ,  $*p < 0.05$ ).

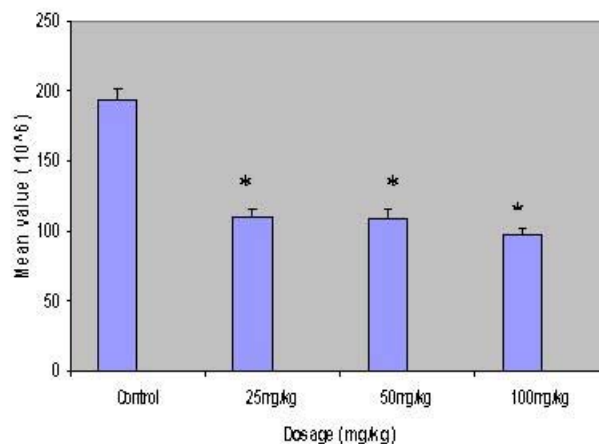
**Effect on Sperm Characteristics**

Treatment of rats for 30 days with all the various doses of AECON caused significant ( $p < 0.05$ ) decrease in sperm motility relative to the control. All the treatment doses of AECON (except 25 mg/kg BW) caused non-significant ( $p > 0.05$ ) decrease in sperm viability (life/dead). All the

treatment doses of AECON caused significant ( $p < 0.05$ ) increase in the percentage of abnormal sperm cells and significant ( $p < 0.05$ ) decrease in sperm count.



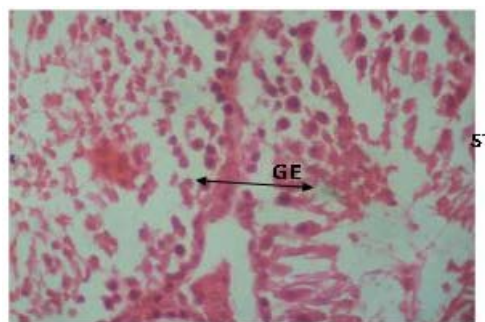
**Figure 3:** Spermogram showing the effects of 30 days treatment with AECON on sperm characteristics ( $n=6$ ,  $*p < 0.05$ ).



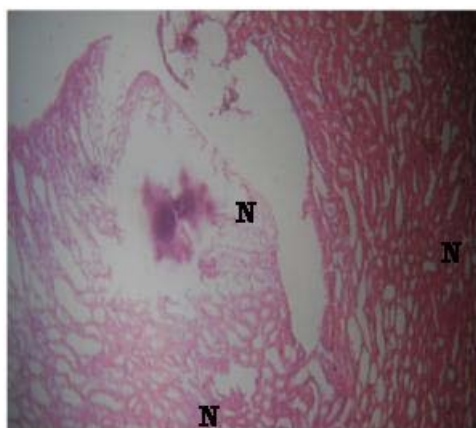
**Figure 4:** Spermogram showing the effects of 30 days treatment with AECON on sperm count ( $n=6$ ,  $*p < 0.05$ ).

**Histopathological Observations**

Treatment of rats for 30 days with different doses of AECON caused moderate to severe necrosis with the dissolution of numerous seminiferous tubules and few remaining seminiferous tubules having lesser cellularity than would be expected. However, the control presented with normal germinal epithelium.



**Plate 1:** Effect of 0.5 ml distilled water (control) on the testis after treatment of rats for 30 days ( $\times 400$ ). Photomicrograph showing normal viable germinal epithelium (GE) with no visible lesion in the seminiferous tubules (ST).



**Plate 2:** Effect of 100 mg/kg BW of AECON on the testis after treatment of rat for 30 days ( $\times 400$ ).

Photomicrograph showing severe necrosis (N) of the seminiferous tubules.

## DISCUSSION

The extract caused significant decrease in body weight of rats after treatment for 30 days, this suggest the anorexic property of *Cola nitida* and which probably confirm earlier report in literature that *Cola nitida* is used for weight reduction and reduction in body fat without undesirable side effect<sup>9</sup>. Similar report was reported previously<sup>10</sup> in rats treated with ethanol.

The extract caused significant decrease in testosterone levels. Similar report was given previously<sup>11</sup> in rats treated with *Aegle mermelos* extract. This decrease in testosterone levels could indicate that the extract inhibit the mechanism intervening in the process of hormone synthesis in the Leydig cells.

The andrological results indicate that treatment of rats for 30 days with the extract caused significant decrease in sperm motility. Similar report was reported previously<sup>12</sup> in rats treated with *Sarcostema acidum* extract. This suggests that the extract was able to permeate the blood-testis barrier with a resultant alternation in the microenvironment of the seminiferous tubules, since it has been reported that the decrease in sperm motility caused by chemical agents was due to their ability to permeate the blood-testis barrier<sup>13</sup> and thus, creating a different microenvironment in the inner part of the wall of the seminiferous tubules from that in the outer part<sup>14</sup>.

The extract caused significant decrease in sperm viability as well as significant increase in the percentage of morphologically abnormal sperm cells in the treated rats. This could be due to the ability of the extract to either interfere with the spermatogenic processes in the seminiferous tubules, epididymal functions or activities of testosterone on hypothalamic release factor and anterior pituitary secretion of gonadotropins which may result in alteration of spermatogenesis<sup>15, 16</sup>.

The extract caused significant decrease in sperm count of the treated rats which could be as a result of decrease in plasma levels of testosterone since this hormone has

been reported to be important in the initiation and maintenance of spermatogenesis<sup>17</sup>. Similar report was reported previously<sup>18</sup> in *Terminalia Chebula* extract treated rats.

Treatment of rats with the extract caused moderate to severe necrosis with the dissolution of numerous seminiferous tubules and few remaining seminiferous tubules having lesser cellularity. Similar result was obtained in rats treated with *Colebrookia opositifolia* extract<sup>19</sup>. This could be due to insufficient amount of testosterone, since it has been reported that testosterone is essential for the growth and division of the germinal cells of the seminiferous tubules<sup>20</sup>.

## REFERENCES

1. Purgesleve JW, Tropical crops cotyledons Longmans London, 1977, 564 – 612.
2. Hatasaka H, Goldstain M, Kola nut as a symbol and its effect on centra nervous system J. Sep., 25; 257 (5), 2001, 2133 – 2136.
3. Osim EE., Arthur SK, Etta KM, Influence of kola nuts (*Cola nitida*) on *in vivo* secretion of gastric acid in rats. Pharm. Biology, 29, 1991, No 3, 215 – 220
4. Scotto G, Maillard C, Vion – Dury J, Balansard G, Jadot G, Behavioural effects resulting from subchronic treatment of rats with extract of fresh stabilized cola seeds. Pharmacol. Biochem. Behav., 26, 1987, 841 – 845
5. Ajarem JS, effects of fresh kola-nut extract (*Cola nitida*) on the locomotor activities of male mice. Acta physiol. Pharmacol. Bulg., 16, 1990, 10 – 15.
6. Oludemokun AA, "Processing, storage and utilization of kola nuts: *Cola nitida* and *Cola acuminata*. Trop. Sci., 24, 1982, 111 – 117.
7. Mohammad – Reza P, Farzaneh D, Taherch TK, Zoherb PP, The effects of hydroalcoholic extract of *Actinidia chinensis* on sperm count and motility, and blood levels of estradiol and testosterone in male rats. Achieves of Iranina Medicine, 8, 2005, 211-216.
8. Laing JA, Fertility and infertility in domestic animals. 3rd edition, 1979, Bailliere Tindall, a division of Cassell Lt.
9. Irvine, Purgesolve, Uses of cola nut family AM J. Chin. 78, 1997, 390 – 393.
10. Weinberg J, Vogl AW, Effects of ethanol consumption on the morphology of the rat seminiferous epithelium. Journal of Andrology, 9(4), 1988, 261 – 269.
11. Das UK, De D, Chatterjee K, Mallick C, Bera TK, Ghosh D, Antigonadal effect induced by hydro-methanolic extract of leaf of *Aegle mermelos* in male rat: Effect of hCG co-administration. Journal of Medicinal Plants Research, 3(10), 2009, 728 – 735.
12. Verma PK, Sharma A, Annu M, Prachi S, Gupta RS, Joshi SC, Dixit VP, Effect of *Sarcostemma acidum* stem extract on spermatogenesis in male albino rats. J. Androl, 4(1), 2002, 43 – 47.
13. Baldessarini RJ, In drugs and the treatment of psychiatriod disorders. The pharmacological basis of therapeutics Ed. By

- Goodman and Gilman. Macmillan Pub. Co. Inc., 1980, 301-417.
14. Bloom W, Fawcett DW, Male reproductive system. In the textbook of Histology, 1975. Saunders Company, Philadelphia.
  15. William KW, Hormones and Hormone antagonists. In: Remington, The Science and Practice of Pharmacy, 11, 2000, 20<sup>th</sup> edition 77: 1390-1391.
  16. Bowman WC, Rand MJ, The reproductive system and drugs affecting the reproductive systems. Textbook of pharmacology, 2<sup>nd</sup> edition, 20, 1985, 1-8.
  17. Christensen AC, Leydig cell: In: Handbook of Physiology, edited by P.O. Greep and E.B. Astwoods. Washington D C American Physiological Society, 1975.
  18. Krishnamoorthy P, Viathinathan S, Rani V, Bhuvanewari A, Effect of *Terminalia chebula* fruit extract on lipid peroxidation and antioxidative system of testis of albino rats. African Journal of Biotechnology, 6(16), 2007, 1888 – 1891.
  19. Gupta RS, Yadav R, Dixit VP, Dobhal MP, Antifertility studies of *Colebrookia oppositifolia* leaf extract in male rats with special reference to testicular cell population dynamics. Fitoterapia, 72(3), 2001, 236 – 17.
  20. Burger H, de Kretsner D, "The Testis". Raven Press, 1989, New York.

**Source of Support:** Nil, **Conflict of Interest:** None.

