



Contraceptive Potential of *Calendula officinalis* Aqueous Extract in Male Rats

Priyanka Sharma, Aksha Sharma, Meera Agarwal, Suresh C. Joshi *

Center for advanced studies, Department of Zoology, University of Rajasthan, Jaipur, India.

*Corresponding author's E-mail: s_c_joshi2003@rediffmail.com

Accepted on: 27-06-2013; Finalized on: 31-08-2013.

ABSTRACT

The effect of aqueous extract of *Calendula officinalis* on reproduction was studied on male rats. The study was divided into three groups. The first groups (I) received vehicle alone to serve as control. The second and third groups were administered with at 150 mg/kg b.wt, and 300 mg/kg. b.wt. respectively, for 60 days. Significant decreases in the weight of testes, epididymis, seminal vesicle and prostate were observed. A dose related reduction in the testicular sperm count, epididymal sperm count and motility were observed. Significant reduction in serum concentration of luteinizing hormone, FSH and testosterone were observed. The level of protein, sialic acid, fructose and glycogen, glutathione were decreased whereas the cholesterol and lipid peroxidation level were increased significantly. It is concluded that the aqueous extract of *C. officinalis* produced dose related effect on male reproduction and possess contraceptive potential in male rats.

Keywords: Glutathione, Lipid peroxidation, Luteinizing hormone, Testes.

INTRODUCTION

Control of population growth is very important in populated countries. In this regard these countries require developing family planning programme. One of the most challenging persists in the realm of pharmaceutical and medical science is the search for newer and more potent drug with little toxic effect, self administrable, less expensive and completely reversible.¹ The synthetic agents available today for fertility control produce severe side effects such as hormonal imbalance, hypertension, and increased risk of cancer and weight gain. Thus there is a need to replace these agents by safe and effective agents such as plant based contraceptive agents.

Medicinal plants have long been used as a source of relief either in form of traditionally prepared or pure active principal and medicinal plants are part and parcel of human society to combat diseases, from the dawn of civilization.² Herbal medicines are in great demand in the developed as well as developing countries for primary healthcare because of their wide biological and medicinal activities, higher safety margins and lesser costs.^{3,4} There are several medicinal plants associated with antifertility properties.^{5,6}

Calendula officinalis Linn. (Asteraceae) commonly known as Pot Marigold, is an important medicinal plant. *Calendula* has been reported to possess many pharmacological activities which include antioxidant⁷, antiviral⁸, antifungal⁹ and antifertility.¹⁰ Despite of prominence in Ayurvedic literature, there is dearth of scientific data on effects of *C. officinalis* on the male reproductive function.

Therefore, in present investigation *C. officinalis* has been used to evaluate its effect in fertility and reproductive function in male rats.

MATERIALS AND METHODS

Animal and housing

Healthy, adult male albino rats (*Rattus norvegicus*), each weight about 180-220 gm were used in experiment. Male Wistar rats were housed in plastic cages under standard conditions of light and dark (12 h: 12h) with an ambient temperature of 24°C±2°C. They were fed with standard laboratory chow and water *ad libitum*. The guidelines for care and use of animals for scientific research¹¹ were strictly followed throughout the course of investigation.

Plant extract

Calendula officinalis was collected from Nursery, University Of Rajasthan, Jaipur. Botanical identification was authenticated at the Department of Botany, University of Rajasthan in comparison with the pre existing vouchers specimen (RUBL 20541). The plant was shade dried and powdered. 100 gm of powder were dissolved with distilled water for 48 hours. The water was evaporated under reduced pressure.

Experimental set up

The calculated doses of *C. officinalis* were administered orally through pearl point needle everyday in the morning.

The animals were divided in three groups having 10 animals in each group:

Group I - Vehicle (Distilled water) 0.5 ml/day/rat for 60 days through Pearl point needle.

Group II - 150 mg/ kg b.wt./day/rat (COAqEX) in 0.5 ml DW for 60 days through Pearl point needle.

Group III -300mg/ kg b.wt./day/rat (COAqEX) in 0.5 ml DW for 60 days through Pearl point needle.

Reproductive performance

To study the reproductive performance of the control and extract treated rats, mating tests were performed. During the last 5 days of the experiment, male rats were caged overnight with parous females (proestrous / estrous) in ratio of 1:2 for fertility test. Mating was confirmed by the presence of sperms in the vaginal smears on the following morning and this was considered to be the first day of pregnancy. The mated females (sperm positive) were separated until parturition. The number of pups (litters) delivered on the day of parturition was recorded. The numbers of rats that became pregnant and litter size were taken into consideration to assess the fertility and fecundity of male rats.

Autopsy Schedule

The rats were weighed and autopsied under light ether anesthesia, 24 hour after last dose of treatment. The blood from heart was collected in pre heparinised tubes for hematological studies.

Body and organ weight measurements

Initial and final weights of the animals were recorded. At autopsy, the reproductive organs (testes, epididymis, seminal vesicle, prostate, vas deferens) were taken out trimmed free of fat and weighed separately on electronic balance.

Sperm motility and density

After anesthetizing the rats, the epididymis was exposed by scrotal incision and spermatozoa were expressed out by cutting the distal end of the cauda epididymal tubules.

Epididymal fluid with spermatozoa was diluted with physiological saline and placed on a Neubauer's chamber slide and motility (rate and percentage) of 100 spermatozoa per rat was observed under microscope using per calibrated ocular micrometer.¹²

Spermatozoa were counted by placing the sperm suspension on both slides of Neubauer's hemocytometer and allowed to settle in a humid chamber for one hour. The number of spermatozoa in the appropriate squares of hemocytometer was calculated under the microscope at 100 X magnification.¹³

Tissue Biochemistry

Biochemical estimation of fresh frozen testes and epididymis were done by Colorimetric method. The tissues were analyzed for the total protein in testes and epididymis¹⁴, glycogen¹⁵, total cholesterol¹⁶, lipid peroxidation¹⁷ and glutathione (GSH)¹⁸ in testes.

Hormones

Estimation of testosterone, FSH (Follicle Stimulating Hormone) and LH (Luteinizing Hormone) in serum were performed with the help of ELISA technique.

Histological Study

For histological observation Bouin's fixed testes were washed in water to remove excess of fixative, dehydrated in graded series of alcohol, cleaned in xylene, embedded in paraffin wax and sectioned at 5µm and counter stained in eosin for the cytoplasmic contrast. Sections were observed for histopathological effects.

Statistical Analysis

All of the recorded values of body organ weight, sperm dynamics, hematological parameters and testicular cell dynamics were expressed in terms of mean ± SEM. The treated groups were compared with control using the student's test.

RESULTS

Body and organ weight

The body weight of the animals did not bring any significant changes at all the two dose levels after *C. officinalis* aqueous extract (COAqEx) treatment. However COAqEx caused non significant decrease in the testicular weight at 150 mg but a significant ($P \leq 0.01$) depletion was observed at 300 mg/kg b.wt./day dose levels. A non significant decline in relative weight of epididymides was observed in rats receiving COAqEx at 150mg but significant ($P \leq 0.01$) decline in relative weight of epididymides was observed in rats receiving 300 mg/kg b.wt./day for 60 days when compared with control rats. After oral administration of COAqEx at 150 mg dose level a non significant decrease was observed in the weight of seminal vesicles. Whereas significant ($P \leq 0.01$) reduction was noticed at 300 mg dose level. After the oral administration of COAqEx at 150 mg dose level, non significant decrease was observed in the weight of prostate gland and highly significant ($P \leq 0.001$) reduction was noticed at 300 mg dose level dose level. COAqEx treatment caused a non significant reduction in the weight of vas deferens at the dose level of 150 mg and but it was decreased ($P \leq 0.01$) significantly when 300 mg dose level was administered.

Implantation sites

COAqEx treatment caused a significant ($P \leq 0.01$) to highly significant ($P \leq 0.001$) reduction in the implantation sites in female mated with males received 150 mg, 300mg and when compared with control group of animals (Table 1).

Sperm density and motility

The density of sperms in the testes was decreased significantly ($P \leq 0.01$) at 150 mg dose level and it was decreased highly significantly ($P \leq 0.001$) at 300mg dose levels. The number of spermatozoa in cauda epididymis was declined significantly ($P \leq 0.01$) in rats receiving 150

mg/kg b.wt/day and significantly ($P \leq 0.001$) in rats receiving 300 mg/kg b.wt./day doses of COAqEx when compared with control and also between three groups themselves. The administration of 150mg and 300mg of COAqEx caused a remarkable reduction in the sperm motility in the cauda epididymis in all the treated groups (Table 1).

Serum Hormones

The serum testosterone, FSH and LH level were decreased significantly ($P \leq 0.01$) at 150 mg dose level while it was highly significantly decreased at 300 mg dose levels when compared with that of control group (Figures 1-3).

Table 1: Sperm Dynamics and Fertility Tests of Control and *Calendula Officinalis* Extract (Aqueous) Treated Rats

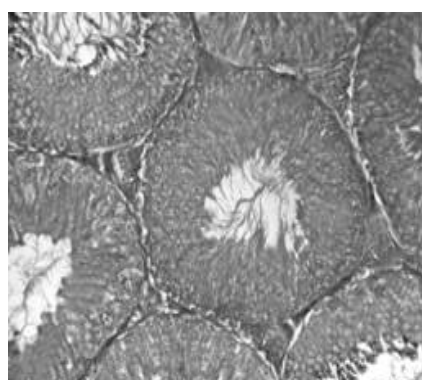
Treatment	No. of males	No of females	No of pregnant females	No of implantation sites/rat	No. of viable fetuses	Sperm density (million/ml)		Sperm motility Cauda epididymis %	Fertility %
						Testis	Cauda epididymis		
Group I Control (vehicle treated)	10	20	20/20	11.25 ± 0.92	8.25 ± 1.10	4.55 ± 0.43	56.50 ± 1.62	79.01 ± 6.73	100(+ve)
Group II 150mg/kg.b.wt/day for 60 days	10	20	9/20	6.25* ± 0.47	5.12* ± 0.69	3.24* ± 0.11	34.04* ± 0.83	45.18* ± 4.91	55(-ve)
Group III 300mg/kg.b.wt/day for 60 days	10	20	4/20	4.50** ± 0.18	3.54** ± 0.71	2.55** ± 0.10	22.08** ± 1.85	37.96** ± 4.46	80(-ve)

(Mean ± SEM of 10 Animals); Group II, III, Compared with group I; ns = non-significant; * = significant ($p \leq 0.01$); ** = highly significant ($p \leq 0.001$).

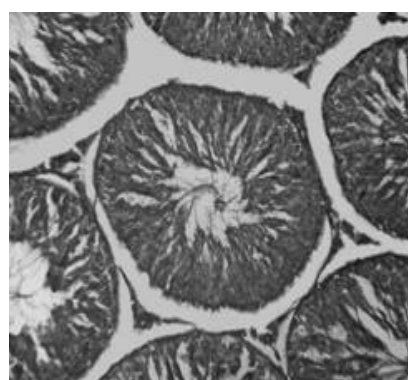
Table 2: Tissue biochemistry of control and *calendula officinalis* extract (aqueous) treated rats

Treatment	Protein (mg/gm)		Sialic acid (mg/gm)		Cholesterol (mg/gm)	Glycogen (mg/gm)
	Testes	Epididymis	Testes	Epididymis	Testes	Testes
Group I Control (vehicle treated)	212.43 ± 4.15	218.90 ± 6.02	6.90 ± 0.90	6.20 ± 0.69	7.96 ± 0.36	4.89 ± 0.14
Group II 150mg/kg.b.wt/day for 60 days	194.09 ^{ns} ± 9.73	198.06 ^{ns} ± 7.71	5.09* ± 0.31	4.17* ± 0.42	8.38 ^{ns} ± 1.24	3.43* ± 0.20
Group III 300mg/kg.b.wt/day for 60 days	168.23* ± 12.64	164.49* ± 4.56	4.76** ± 0.28	3.99** ± 0.18	11.96** ± 1.68	2.55** ± 0.24

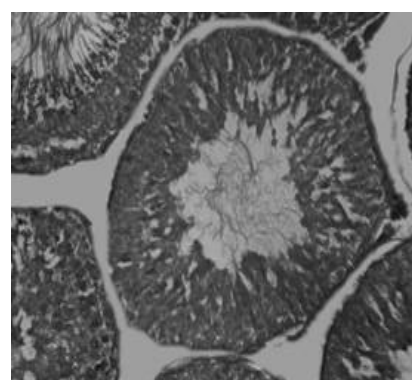
(Mean ± SEM of 10 Animals); Group II, III Compared with group I; ns = non-significant; * = significant ($p \leq 0.01$); ** = highly significant ($p \leq 0.001$).



(a) Control



(b) 150 mg/kg b.wt.



(c) 300 mg/kg b.wt

Figure 1.1: a (Control): Microphotograph of control rat testis shows clearly visible successive stages of spermatogenesis with a normal morphological architecture of seminiferous tubules. **b (150 mg/kg b.wt of *C. officinalis* aqueous extract):** Microphotograph of seminiferous tubules shows spermatogenic element decrease in number. Spermatozoa damaged. Intertubular space increased. **c (300 mg/kg b.wt of *C. officinalis* aqueous extract):** The microphotographs shows seminiferous tubules with degenerated spermatogonia and damaged Sertoli cells and lumen with less sperm. Intertubular space increased (H&E 200X for each microphotograph).

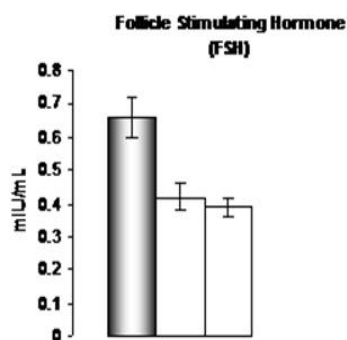


Figure 1

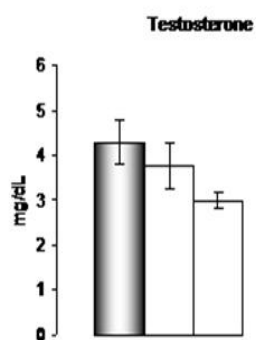


Figure 2

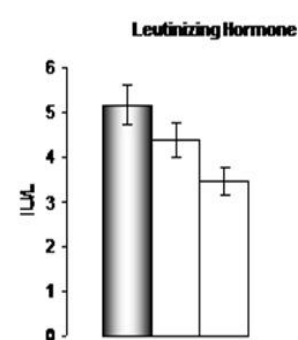


Figure 3

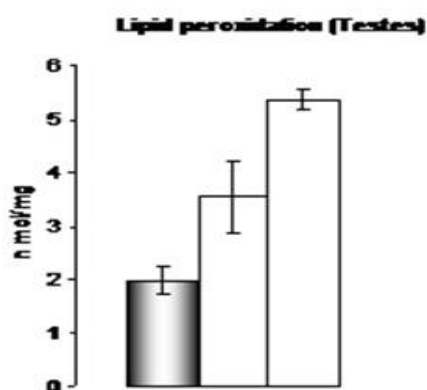


Figure 4

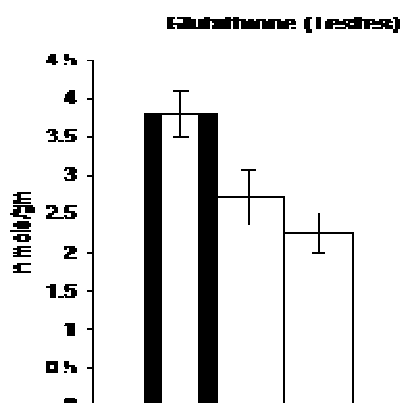


Figure 5

Biochemical analysis

The value of total protein content in the testes and epididymis was changed non significantly at the 150 mg dose level and but it was decreased remarkably ($P \leq 0.01$) at 300 mg dose levels after the oral administration of *C. officinalis* (aqueous) extract when compared with that of control group (Table 2).

The level of sialic acid in testis and epididymis was decreased significantly ($P \leq 0.01$) in the 150mg treatment group but it was decreased highly significantly ($P \leq 0.001$) in the 300 mg of *C. officinalis* (aqueous) extract treated rats (Table 2).

The change in level of cholesterol in the testis was non-significant in the rats received 150 mg dose of *C. officinalis* for 60 days while it was increased highly significantly ($P \leq 0.001$) after treatment with 300 mg dose levels. The level of glycogen in testis was decreased significantly ($P \leq 0.01$) in the 150mg treatment group whereas it was decreased highly significantly ($P \leq 0.001$) in the animals received 300 mg of *C. officinalis* (aqueous) extract (Table 2).

Antioxidants

The level of lipid peroxidation in testes was increased significantly ($P \leq 0.01$) in the 150mg treatment group and it was increased highly significantly ($P \leq 0.001$) in the rats receiving 300 mg of *C. officinalis* (aqueous) extract for 60 days (Figure 4). The level of glutathione in testis was decreased significantly ($P \leq 0.01$) in the 150mg treatment group and it was decreased highly significantly ($P \leq 0.001$) in the rats received 300 mg of *C. officinalis* (aqueous) extract (Figure 5).

Histological observations

The histological picture of the testis of control rats displayed normal process of spermatogenesis. The seminiferous epithelium showed characteristic tiered arrangement of all successive germ cell types. The tubular lumen was fully occupied by large number of healthy spermatozoa. The presence of large number of normal Leydig cells was also conspicuous in the interstitium (Figure 1.1a).

The histoarchitecture of the testis in the rats receiving *C. officinalis* (aqueous) extract (150 mg/kg/day) showed degenerative changes. The characteristics tiered arrangement was also disturbed. The number of spermatogonia and spermatocyte remain unaffected. The

Leydig cells showed atrophic changes. Intertubular space is increased (Figure 1.1b). The histoarchitecture of the testis in the rats receiving *C. officinalis* (aqueous) extract (300 mg/kg/day) showed some degenerative changes and disruption of spermatogenesis. The number of spermatogonia remained significantly decreased. The Leydig cells were shrunken and showed disruption of normal epithelial organization. Few spermatozoa were seen in lumen. The Leydig cells were shrunken and showed atrophic changes (Figure 1.1c).

DISCUSSION

In the present investigation aqueous extract of *C. officinalis* were studied to evaluate their anti fertility effect on testes and accessory sex organ weight; sperm dynamics and fertility, biochemistry of reproductive organs, serum testosterone, FSH, LH level, histology of male reproductive organs and antioxidants.

The weight of testes largely depends on the mass of differentiated spermatogenic cells. The reduction in the weight of testis may be due to loss of spermatids and spermatozoa, reduced tubular size and inhibition of steroid synthesis by Leydig cells.¹⁹ In addition to this decline in testicular protein content may also be responsible for testicular weight loss.^{20, 21}

The observed reduction in the relative weight of the epididymis in both extracts treated rats could be due to a reduction in the number of sperms in the epididymal lumen by virtue of suppression of androgen supply, since the threshold of androgen required for the maintenance of epididymal structure and function is ten times higher than in the blood. The adult epididymis is important for fertility not only as a conduit as an active contributor in the formation of a fertile ejaculate. The epididymis transport, concentrates, matures and stores spermatozoa.²² The weights of seminal vesicle, vas deferens and prostate gland are used in hormonal bioassay of androgen activity.²³

The function of sperm as well as the production of a sufficient number of sperm is an absolute requirement for the male side to ensure fertilization. Forward, progressive and sustained motility is an important function of sperm, and evaluation of sperm motility should provide useful information for evaluating effects on male fertility.²⁴

Administration of aqueous extract of *C. officinalis* caused decreased serum testosterone and adversely affected the biochemical milieu of epididymis rendering it hostile for sperm maturation. Impaired maturation of spermatozoa is responsible for decline in motile and viable spermatozoa and consequently decline in fertility. Our results are in consonance with earlier reports which have also indicated decline in sperm motility and density in cauda epididymis after treatment of various plants extracts exhibit anti androgenic, anti spermatogenic and anti fertility effects.²⁵ The decline in testosterone adversely affects the testicular and sex accessory organs function. The synthesis of testosterone takes place in

Leydig cells and requires cholesterol.²⁶ Spermatogenesis is dependent on high intratesticular testosterone concentration and the action of FSH on the Sertoli cells. The decrease in LH leads to marked suppression of testosterone production by the Leydig cells; the decrease in intratesticular testosterone coupled with suppression of FSH leads to a decrease in Sertoli cell function required for germ cell maturation and survival.²⁷ The reduced testicular and epididymal protein content could be correlated with the absence of spermatozoa in the lumen of testes and epididymis.²⁸ Decreased in sialic acid content of testes and sex accessory organs may be correlated with loss of androgen.¹⁰ A similar increase in testicular cholesterol was observed in rats due to functional impairment of Leydig cells by the treatment of synthetic hormonal or non hormonal compounds²⁵ and plant extracts possessing anti androgenic activity.²⁹ A similar decrease in glycogen content of the testis has been observed by many workers after treatment with many plant extracts which caused severe impairment of spermatogenesis.³⁰ A large number of environmental chemical and heavy metals are reported to increase the level of lipid per oxidation in testis and a concomitant decrease in antioxidant levels, culminating in impaired spermatogenesis.³¹ GSH is a major endogenous antioxidant which counters balance free radical mediated damage. In a state of oxidative stress, the level of glutathione is reduced because it is converted to glutathione disulfide (GSSG).³² The decrease testicular weight and reduced seminiferous tubules diameter reflects widespread cellular damage and androgen deprivation. Decreased androgen level affected the number and volume of mature Leydig cells, seminiferous tubules and their function status.³³

CONCLUSION

In conclusion, present study demonstrate that aqueous extract of *C. officinalis* is a potential antispermatic and capable to suppress male fertility. However, further studies are required to understand the mechanism of action of *C. officinalis* for its contraceptive activity.

REFERENCES

1. Unny R, Chauhan AK, A Review of potentiality of medicinal plant as the source of new contraceptive principles, *Phytomedicine*, 10, 2003, 233-260.
2. Bandyopadhyay U, Biswas K, Chattopadhyay I, Banerjee RK, Biological activities and medicinal properties of neem (*Azadirachta indica*), *Currnt Sci*, 82(11), 2002, 1336-1345.
3. Joshi SC, Sharma A, Chaturvedi M, A review on plants/plants products possessing antifertility/contraceptive efficacy in males, *Pharmacologyonline*, 3, 2010, 818-832.
4. Chaudhary G, Goyal S, Poonia P, *Lawsonia inermis* Linnaeus: A Phytopharmacological Review, *International Journal of Pharmaceutical Sciences and Drug Research*, 2(2), 2010, 91-98.



5. Joshi SC, Sharma A, Chaturvedi M, Antifertility potential of some medicinal plants in males: an overview, *Int. J. Pharm. Pharm. Sci.*, 3(5), 2011, 204-217.
6. Verma PK, Sharma A, Joshi SC, Gupta RS, Dixit VP, Effect of isolated fractions *Barleria prionitis* roots methanolic extract on reproductive function of male albino rats, *Fitoterapia*, 76(5), 2005, 428-432.
7. Preethi KC, Kuttan G, Kuttan R, Antioxidant potential of *Calendula officinalis* flower in vitro and in vivo, *Pharmaceutical. Biol.*, 44(9), 2006, 691-697.
8. Barbour EK, Sagherian V, Talhouk S, Talhouk S, Talhouk R, Farran MT, Sleiman FT, Harakeh S, Evaluation of homeopathy in broiler chicken exposed to liver viral, vaccins and administrated *Calendula officinalis* extract, *Med. Sci. Monit*, 10(8), 2004, 281-285.
9. Kasiram K, Sakharkar PR, Patil AT, Antifungal activity of *Calendula officinalis*, *Indian. J Pharm Sci*, 6, 2000, 464-466.
10. Agrawal M, Sharma P, Kushwaha S, Antifertility efficacy of 50% ethanolic extract of *Calendula officinalis* in male rats, *Int. J. Pharm. Pharm. Sci.*, 3(5), 2011, 192-196.
11. Indian National Science Academy (INSA). Guidelines for care and use of animals in scientific research reported by Indian National Science Academy, New Delhi, 2000.
12. Srikanth V, Malini T, Arunakaran J, Govndarajulu P, Balasubramanian K, Antispermatogetic activity of leaves of *Aegle marmelos* Corr. in albino rats, *Biomedicine*, 19(3), 1999, 199-202.
13. Zaneveld LJD, Polakoski KL, Collection and physical examination of the ejaculate. In: Hafez, E.S.E. Ed., *Techniques of Human Andrology*. Amsterdam, Holland: North Biomedical Press, 1977, 147-156.
14. Lowry OH, Rosenburg DJ, Farr AL, Randoll RJ, Protein measurement with Folin-phenol reagent, *J. Biol. Chem*, 193, 1951, 265-275.
15. Montgomery R, Determination of glycogen, *Arch Biochem Biophys*, 67, 1957, 378-381.
16. Zlatkis A, Zak B, Bayle AJ, A new method for the direct determination of serum cholesterol, *J. Lab. Elin. Med*, 41, 1953, 486-492.
17. Okhawa H, Ohishia N, Yagik, Assay for lipid peroxidation in animals tissue by thiobarbituric acid test, *Anal. Biochem*, 95, 1979, 351-358.
18. Moron MS, Depierren JW, Mannervik B, Level of glutathion, glutathion reductase and Glutathion Stransferase activities in rats lung and liver, *Biochem. Biophysics. Acta*, 582, 1979, 67-78.
19. Jana K, Jana S, Samanta PK, Effect of chronic exposure to sodium arsenate on hypothalamic-pituitary-testicular activities in adult rats: possible an estrogenic mode of action, *Reproductive Biol & Endocrinol*, 4, 2006, 9. dot: 10 1186/14 77-7829-4-9.
20. Chaudhary N, Joshi SC, Reproductive toxicity of endosulfan in male albino rats, *Bull. of Environ. Cont. and Toxicol*, 70, 2003, 285-289.
21. Choudhary N, Goyal R, Joshi SC, Effect of malathion on reproductive system of male wistar rat, *Journal of environmental biology*, 29(2), 2008, 259-262.
22. Turner TT, The human epididymis, *J, Androl*, 24, 2008, (online).
23. Adesanya OA, Oluayemi KA, Dare NW, Lukeman AJ, Shittu, Oyesola OA, Sex steroid induced changes on the morphology of prostate of Sprague-dawley rats, *Scientific Res. Essay*, 2, 2007, 309-314.
24. Kaneto M, Kishi K, Spermatogenic dysfunction and its evaluation by computer - assisted sperm analysis in the rat, *Ann. Rpts. Shionogi. Res. Lab*, 53, 2003, 1-20.
25. Jain GC, Ali SM, Effect of ethanolic extract of *Cassia alata* (L.) flowers on reproductive function of male albino rats, *J. Exp. Zool.India*, 10, 2007, 129-132.
26. Soez JM, Leydig cells: endocrine, paracrine and autocrine regulation, *Endocr. Rev*, 15, 1994, 574-626.
27. Wang C, Swerdloff RS, Hormonal Approaches to Male contraception, *Curr Opin Urol*, 20(6), 2010, 520-524.
28. Bedwal RS, Edwards MS, Katoch M, Bahuguna A, Dewan R, Histological and biochemical changes in testes of Zinc deficient BALB/C strain of mice, *Indian J. Exp. Biol*, 32, 1994, 243-247.
29. Seetharam YN, Sujeeth H, Jyothishwaran G, Barad A, Sharanabasappa G, Umareddy B, Antifertility effect of ethanolic extract of *Amalakyadi churna* in male albino mice, *Afr J. Med. Sci*, 5(3), 2003, 247-250.
30. Gupta RS, Kumar P, Dixit VP, Dobhal MP, Anti fertility studies of the root extract of the *Barleria prionitis* Linn in male albino rats with special reference to testicular cell population dynamics, *J. Ethnopharmacol*, 70(2), 2000, 111-117.
31. Wang C, Swerdloff RS, Male hormonal contraception, *Am. J. Obstet. Gynecol*, 190(4 Suppl), 2004, S60-S68.
32. Wu G, Fang YZ, Yang S, Lwpton JR, Turner ND, Glutathione metabolism and it's implication for health, *J. Nutr*, 134, 2004, 489-492.
33. Jensen TK, Bonde JP, Joffe M, The influence of occupational exposure on male reproductive function, *Occup Med*, 56 (8), 2006, 544-553.

Source of Support: Nil, Conflict of Interest: None.

