



## *Jussiaea repens* (L) Induced Morphological Alterations in Epididymal Spermatozoa of Rat

Subhasish Ghosal, Indrani Chakraborty, Nirmal Kr Pradhan\*

Presidency University, Department of Physiology, Reproductive Biology Research Unit, 86/1 College Street, Kolkata, West Bengal, India.

\*Corresponding author's E-mail: [pradhan.nirmal11@gmail.com](mailto:pradhan.nirmal11@gmail.com)

Accepted on: 25-08-2013; Finalized on: 30-09-2013.

### ABSTRACT

*Jussiaea repens* (L), a medicinal plant has been reported to have antigonadal activity on male reproduction in rat in a dose dependent manner when administered orally. The crude aqueous extract (except root) decreased the total sperm count, motility, viability and increased the abnormal sperm percentage significantly (58%) and the effect was maximum at the dose of 200mg/kg b.wt/ day for 28 days. The present study was aimed at determining the sperm quality and morphological alterations of sperm cells at the dose mentioned and to confirm the anti fertility activity of the plant extract by mating experiments. Results showed that the extract induced alterations of sperm morphology was predominantly of primary abnormalities (40%), which include hook less, banana head, pin head, bent neck, bent tail, head amorphous and presence of cytoplasmic droplets. About 10% secondary abnormalities were found to have coiled tail or head less spermatozoa. The tertiary abnormalities (8%) i.e., tailless or detached head and simple coil tail were also found. Morphological changes in plasma membrane of spermatozoa were further confirmed by SEM study. Presence of cytoplasmic droplets and disruption of plasma membrane of spermatozoa in treated group also confirm the potentiality of this plant extract as an anti fertility agent. Our mating experiments also confirm the anti fertility activity of this plant extract as it showed that the mating rate of treated male is low in compared to control, whereas fertility rate was absolutely 'zero' in experimental group. The resumed fertility after withdrawal of the treatment also confirmed the reversible action of this plant extract.

**Keywords:** Antifertility, Fertility assessment, *J.repens*, Reversal effect, SEM study, Sperm morphology.

### INTRODUCTION

*Jussiaea repens* (L), locally known as 'Kesardam' of onagraceae family, is a water creeping prime rose found in the wet lands of different parts of India as well as in other countries like Africa, China, Thailand, Malaysia, Australia etc.<sup>1,2</sup> This plant has great medicinal values as reported by others. It can be used as hepatoprotective, anti diabetic, anti helminthic, anti dysenteric, anti-inflammatory and anti bacterial agent.<sup>3,4</sup> It has also some therapeutic uses i.e., in ulcer, fever, cough, diuretic, urinary tract infection etc.<sup>5,6</sup> But there was no available scientific report of this plant on male reproductive system, only an ethno-biological report from Papua, New Guinea shows that leaves and stem of this plant can be used to prevent pregnancy.<sup>1</sup> This plant, though it contains some antifertile agents like rutin, kaempferol, quercetin, triterpenes etc. as their active compounds,<sup>7-13</sup> still unknowingly it is widely consumed by village people as vegetable<sup>14</sup> and animal forage.<sup>15</sup>

In our previous study, we have reported that aqueous extract of *Jussiaea repens* is a non-toxic antigonadal herb which affects the male reproductive system of rats when administered orally in a dose dependent manner for a period of two spermatogenic cycles. This plant extract reduced the epididymal sperm count, motility, viability and increased the percentage of abnormal sperm concentration significantly when compared with control and the effect was maximum at moderate dose (200mg/kg b.wt/day for consecutive 28 days).<sup>16</sup>

The present study was aimed to evaluate the sperm characteristics including morphology and fertility activity of treated animals to ascertain the anti fertility nature of the plant extract after oral administration of the effective dose (200mg/kg b.wt/day for 28 days) to male albino rats. Drug withdrawal experiments were also performed to assess the nature of action of the extract i.e., reversible or irreversible. Since fertility depends on the viability, concentration and morphology of the sperm cells<sup>17</sup> produced by the testes and this plant is widely consumed by the common people, the outcome of this study will be the basis for advising the ethnomedical practitioners and the general public on the usage of this herb.

### MATERIALS AND METHODS

#### Plant material

The plant *Jussiaea repens* L. was collected from wet lands of Duttapukur, North 24 pargana district, WB, India, during the month of March - April. The plant was identified and authenticated by taxonomist of Central National Herbarium (Kolkata), Botanical Survey of India (BSI), Shibpur, Howrah, having voucher specimen number NP-01 dated 25.03.2011. The collected fresh plants were carefully washed repeatedly under running tap water and finally with distilled water then air dried at 35-40°C for 4-5 days and homogenized the whole plant except root to a fine powder using a sterilized mixer grinder and stored for extraction.



### Preparation of extract

The plant extract (except root) was prepared as reported earlier.<sup>16</sup> Briefly, the dried powdered sample (400gm) of *J. repens* was extracted in 4L boiled distilled water at 50°C for 30 minutes then allowed to cool and stay overnight at room temperature. The residue was further extracted twice similarly. Then it was filtered using a clean muslin cloth and ordinary filter paper finally by Whatman No.1 filter paper. The resulting filtrate was then concentrated using a rotary evaporator and further dried at 40°C. Finally yield 8 % solid crude extract was stored in powdered form in an air tight container at (4°C) for further use in the experiment.

### Animal

36 adult male albino rats (*Rattus norvegicus L.*) of Wistar strain weighing 130g ±10 were selected for this experiment. The animals were acclimatized to the laboratory environment for a period of one week before starting the experiment. The animals were maintained under standard laboratory conditions (12 hrs light: 12 hrs dark, 25±2°C and relative humidity 40-60%) with free access to standard normal diet (prescribed by ICMR, NIN, Hyderabad, India)<sup>18</sup> and water *ad libitum*. All animal experiments were performed according to the ethical guidelines suggested by the Institutional Animal Ethics Committee (IAEC) guided by the Committee for the Purpose of Control and Supervision of Experiments on Animals (CPCSEA), Ministry of Environment and Forest, Government of India (Ref. no. PU 796/03/ac/CPSEA).

### Animal treatment

Animals were equally divided and randomly selected into 3 groups having 12 animals in each and were treated as -

Group I (Control): Given sterile distilled water (5 ml/ kg body weight/day) for 28 days.

Group II (Treated): Given aqueous extract (200 mg/kg body weight/day) for 28 days.

Group III (Recovery): Treated with aqueous extract (200 mg/kg body weight/day) for 28 days and allowed for next 28 days without any treatment to check the reversibility.

The daily dose was prepared by suspension the extract in 0.5 ml of sterile water and administered to each animal orally with the help of oral gavage needle. The initial body weight of animals was recorded. Animals were weighed twice weekly throughout the experiment and the dose was adjusted accordingly. Treatment schedule was selected for two seminiferous cycles (~ 28 days) consecutively. On the 29th day (24 hours after the last dose of treatment and 18 hours after fasting), 8 animals from control and treated groups, were anaesthetized by diethyl ether. Blood samples were collected and Serum samples were separated by centrifugation which was stored at - 20°C for different biochemical assay. The reproductive organs i.e. testes and epididymis of each animal were dissected out, freed from adherent tissues, blotted free of blood and wet weights were recorded on

an electronic top pan balance to the nearest mg. Remaining 4 rats, each of control and treated group (group I,II) were subjected to fertility testing. In Group III, for recovery studies over a period of next 28 days after consecutive treatment, 8 animals were sacrificed. All spermatological and biochemical parameters along with the weight of testis and epididymis were repeated in order to ascertain the nature of action of extract, i.e. reversible or irreversible. The remaining 4 rats from Group III were left for fertility studies.

### Sperm motility and total sperm count

One caudal epididymis of each animal in right side was rinsed and gently minced in 2 ml of phosphate buffered saline (PBS, pH 7.4). Epididymal sperm motility and sperm concentration was determined as per the method described in the WHO Manual.<sup>19</sup> sperm suspension was placed on a Neubauer hemocytometer in WBC chamber and percentage motility was determined by counting both motile and immotile spermatozoa compared to total cells. The number of sperms was counted by Neubauer hemocytometer with a light microscope at X 400 magnification in a RBC counting 5 major squares and were expressed as million/ml of suspension.

### Sperm viability

Sperm suspension (50µl) was mixed with eosin-nigrosin staining solution (50µl). The suspension was incubated for 30s at room temperature (20°C). Then incubated suspension was transferred with a pipette to a labeled glass slide and thin smear was prepared. Two such smears were prepared from each sample. The smears were air dried and examined directly under microscope. At least 200 sperms were studied at magnification of x400 under oil immersion with a bright field objective. Unstained sperms were considered as live and pink or red coloured sperm as dead.<sup>20</sup>

### Sperm morphology

Sperm morphology was studied from a total count of 200 spermatozoa in a smear prepared from above sperm suspension stained by eosin-nigrosin mixture (6.7 gm eosin and 100 gm nigrosin in 1L 0.9 gm % saline. ) as observed under high power objective (magnification × 400). The defective shape and structure of either head and or tail were considered as abnormal and the data was presented as percentage incidence of total abnormalities. Sperm abnormalities were classified by the method of Bloom (1973).<sup>21</sup>

### Preparation of spermatozoa for SEM study

Rat spermatozoa for SEM study were prepared according to Mayuva Areekijserree et al.<sup>22</sup> Briefly, a drop of cauda epididymal spermatozoa suspension was fixed in 2.5% glutaraldehyde in 0.1 M phosphate-buffer (pH 7.4) for 2 h at 4°C and a thin film was applied on a coverslip then rinsed with same buffer. Preparation was dehydrated by graded alcohol and air dried, coated with gold, and finally observed under S-530 Hitachi SEM.

## Fertility test

Fertility tests were carried out during the treatment and recovery periods (for 5 days prior to termination of treatment) along with control by allowing a male rat to mate with fertility proven females in a ratio of 1:2. Prior to mate, the females were isolated for one month to rule out pre-existing pregnancy. During mating the vaginal smear was checked daily in the next morning to observe the presence of sperm. When sperms were detected in the smear, which indicated the positive mating (sperm-positive) and the day was considered as zero day of pregnancy. The mated females were separated and observed the implantation sites on 16th day of pregnancy through lapotomy to assess the fertility rate with reference to the number of implantations. Percentage of fertility was calculated as number of pregnant female rats divided by the number of mated females multiplied by 100 according to WHO Protocol MB-50, 1983.<sup>23</sup>

## Statistical analysis

The recorded values were expressed in mean  $\pm$  SEM. The treated groups were compared to control using one way

ANOVA with post hoc LSD test were performed using SPSS version 16 Software. The value of  $p < 0.05$  was considered to be statistically significant.

## RESULTS

In the present investigation, the body weights were not affected after the treatment suggesting that the extract have no side effect of the animals throughout the experiment. But there is significant decrease in organ weights, viz., epididymis and testis at the dose of 200mg/kg b. wt/day for consecutive 28 days. The results were similar with the effects shown by *J. repens* extract treatment to rats in the earlier study.<sup>16</sup> However, the organ weights were gradually recovered towards control by 28 days after withdrawal of treatment (Table 1).

Sperm analysis of treated group exhibited significant ( $p < 0.01$ ) decrease in total sperm count, motility, viability and increase in sperm abnormalities (58%) when compared to control (10%). However, the sperm count, motility and viability were gradually recovered to normal and the percentage of normal sperm increased towards control by 28 days after withdrawal of treatment (Table 2).

**Table 1:** Body and relative weight of reproductive organs (gm) of male albino rats in different groups

Treatment	Body weight (gm)		Relative weights of reproductive Organs (g/100 g. body weight)	
	Initial	Final	Testes	Cauda Epididymis
Group I: Control group	131.25 $\pm$ 2.950	161.75 $\pm$ 5.216	1.384 $\pm$ 0.0335	0.2130 $\pm$ 0.0041
Group II: Treated with aqueous extract (200 mg/kg body weight)	128.13 $\pm$ 3.125	165.62 $\pm$ 5.858	1.103* $\pm$ 0.0427	0.1841 * $\pm$ 0.0037
Group III: Recovery group	130.62 $\pm$ 2.745	169.75 $\pm$ 4.558	1.310 $\pm$ 0.1088	0.2124 $\pm$ 0.0107

Values are expressed as means  $\pm$  S.E.M; N=8; \*Significant ( $P < 0.05$ ) Group II were compared to Group I (Control) & Group III (Recovery)

**Table 2:** Cauda epididymal sperm characteristics of adult male albino rats of different groups

	Sperm motility (%)	Sperm count (millions/ml)	Sperm Viability (%)	Sperm Morphology (%)
				Abnormal (%)
Group I: Control group	79.018 $\pm$ 1.899	31.028 $\pm$ 0.9485	87.009 $\pm$ 2.139	10.875 $\pm$ 0.789
Group II: Treated with aqueous extract (200 mg/kg body weight)	24.034** $\pm$ 6.325	15.003 ** $\pm$ 1.585	25.043** $\pm$ 4.424	58.000 ** $\pm$ 3.625
Group III: Recovery group	73.325 $\pm$ 2.623	28.215 $\pm$ 1.044	77.889 $\pm$ 1.632	11.000 $\pm$ 0.597

Values are expressed as means  $\pm$  S.E.M; N=8; \*\*Significant ( $P < 0.01$ ), Group II were compared to Group I (Control) & Group III (Recovery).

The table 3 shows the morphological analysis of sperm cells in different groups of treatment and revealed that the extract treated group exhibits significant ( $p < 0.01$ ) increase in sperm abnormalities (58%) when compared to control (10%). Out of 58% abnormal sperms, the extract induced morphological alterations were found as predominantly of primary abnormalities (40%), where secondary and tertiary abnormalities were 10% and 8% respectively. Primary abnormalities include double head, hook less, pin head, banana head, head amorphous, double head, double tail, cytoplasmic droplets (light and heavy), bent neck, proximal and distal bent tail. While tail coiled around head, mid piece and below the mid piece level, headless tail and other multiple abnormalities were

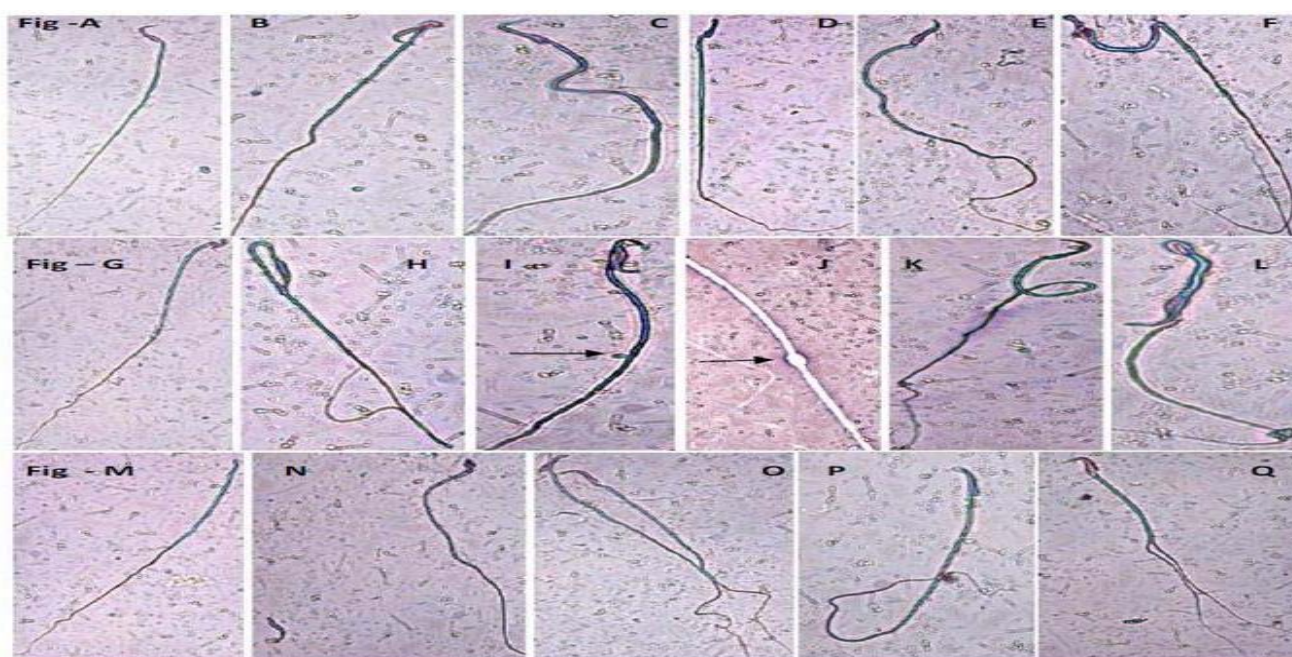
found as secondary abnormalities. The tertiary abnormalities were detached head and simple coiled tail. The primary abnormalities showed 5.25%, 39.4375%, 4.9375 % and secondary abnormalities were 3.5625%, 10.25%, 3.68 % where tertiary abnormalities were 2.0625%, 8.3125%, 2.3750% for Groups I –III respectively. The percentage of primary (39.4375 %), secondary (10.5%) and tertiary (8.3125%) abnormalities in Group - II (treated) were significantly ( $P < 0.01$ ) higher than Group I (control) and III (recovery). After 28 days of recovery, the extract induced altered sperm morphology was returned nearly to normal (Table-3, Figure 1 & 2).



**Table 3:** Morphological analysis of sperm cells in different group

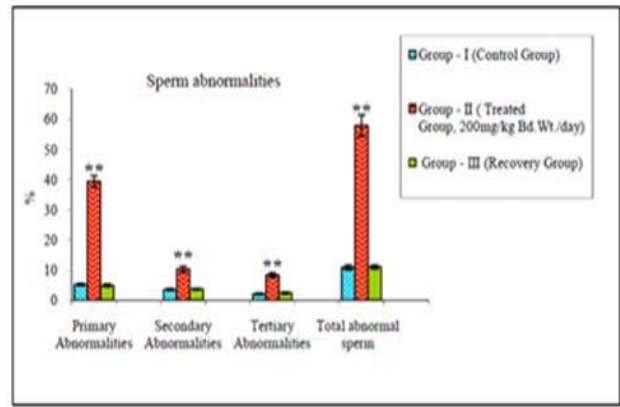
Classification		Group- I (Control)	Group – II Treatment ( 200 mg / kg body wt./day)	Group – III (Recovery )
Primary Abnormalities	Double Head	0.0000 ± 0.0000	0.6250* ± 0.08183	0.0000 ± 0.00000
	Hook less	1.0625 ± 0.11329	7.4375** ± 0.29028	0.8125 ± 0.013153
	Pin Head	0.3750 ± 0.08183	1.6875 ** ± 0.13153	0.2500 ± 0.09449
	Banana Head	0.8750 ± 0.1250	4.1875 ** ± 0.20996	0.6875 ± 0.09149
	Head amorphous	0.2500 ± 0.09449	2.5000 * ± 0.28347	0.3125 ± 0.09149
	Double Head & Double tail	0.0000 ± 0.0000	0.5000 ± 0.1889	0.1250 ± 0.08183
	Cytoplasmic droplet ( Light)	0.0000 ± 0.0000	0.6875* ± 0.09149	0.2500 ± 0.13363
	Cytoplasmic droplet ( Heavy)	0.0000 ± 0.0000	1.0000 ** ± 0.1336	0.1875 ± 0.13153
	Bent neck	0.8750 ± 0.08183	10.1250 ** ± 0.83318	0.8750 ± 0.08183
	Proximal bent tail	0.312 ± 0.09149	2.3125 ** ± 0.09149	0.3125 ± 0.09149
	Distal bent tail	1.5000 ± 0.13363	8.3750 ** ± 0.68628	1.1250 ± 0.18298
	Total %	5.2500 ± 0.35355	39.4375 ** abc ± 1.92363	4.9375 ± 0.41659
	Secondary Abnormalities	Tail coiled around head	0.4375 ± 0.06250	1.3125 ** ± 0.09149
Tail coiled around midpiece		0.7500 ± 0.09449	2.7500 ** ± 0.23146	0.6250 ± 0.08183
Tail coiled below		1.3750 ± 0.18298	2.3125 ** ± 0.1875	1.6250 ± 0.12500
Headless tail		1.0000 ± 0.13363	2.7500 ** ± 0.31339	1.0000 ± 0.13363
Multiple abnormalities		0.0000 ± 0.0000	1.1250 ** ± 0.35038	0.1250 ± 0.08183
Total %		3.5625 ± 0.31956	10.2500 ** ab ± 1.0220	3.6875 ± 0.20996
Tertiary Abnormalities	Detached Head	1.6250 ± 0.18298	6.5000** ± 0.7196	1.1250 ± 0.08183
	simple coil tail	0.4375 ± 0.14752	1.8125 ** ± 0.1875	1.2500 ± 0.16366
	Total %	2.0625 ± 0.25769	8.3125 ** ac ± 0.8395	2.3750 ± 0.20594
	Total abnormal %	10.875 ± 0.789	58.000** ± 3.625	11.000 ± 0.597

Values are expressed as means ± S.E.M.; N=8. \*Significant (P < 0.05), \*\*Significant (P < 0.01), Group II was compared to Group I (Control) & Group III (recovery). Different superscript letters are significantly different; P<0.01 (a = Primary Abnormalities, b = Secondary Abnormalities, c = Tertiary Abnormalities).

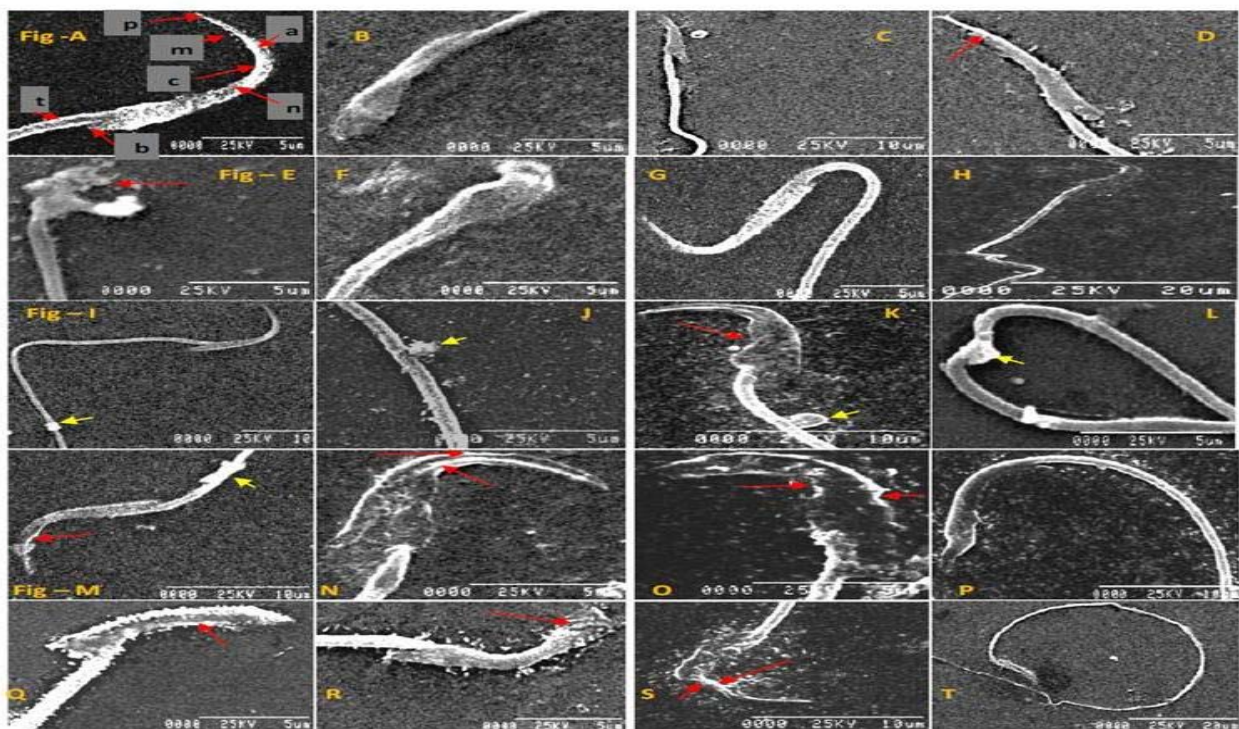


**Figure 1:** Different types of sperm abnormalities - A) Normal sperm, (B) Bent neck, (C) Distal bent tail, (D) Hook less, (E) Banana head, (F) Amorphous head, (G) Pin head, (H) Proximal bent tail, (I) Cytoplasmic droplet (light), (J) Cytoplasmic droplet (heavy), (K) Tail coiled around midpiece, (L) Tail coiled around head, (M) Headless tail, (N) Detached head, (O) Multiple abnormalities, (P) Simple coiled tail, (Q) Double head and double tail. After Eosin-Nigrosin staining. Magnification: X400, Except (J) X1000.

In figure-3, the SEM (Scanning electron microscopic) observations of cauda epididymal spermatozoa in control rats showed the normal morphology (Figure 3A).The whole spermatozoon was intact with all the membranes and organelles. However, the animals fed with 200mg/kg b. wt /day of *J. repens* aqueous extract showed distortion in the plasma membrane and acrosomal membrane in most of the sperm heads. Serrations at the head region of the spermatozoa were observed. The shape and size of sperms were also changed considerably (Figure 3-B, D, E, F, M-S). There was acute dorsoventrally constriction in the mid-head region in most of the sperms. The sub-acrosomal material was bulged/swelled out (Figure 3-O, S). Spermatozoa showed a splitting of tail and distinct visibility of balloon-like cytoplasmic droplets in the mid region of tail. (Figure 3-I, J, K, L).



**Figure 2:** Percent abnormalities of different types of spermatozoa in different groups. \*\*Significant (P < 0.01), Group II was compared to Group I (Control) & Group III (recovery).



**Figure 3:** Scanning electron micrographs (SEM) of cauda epididymal spermatozoa in control (Fig.A) and treated (*J.repens* L. extract of 200mg/kg b. wt/day for 28 days) rats (Figs. B - T) - **A** : Spermatozoa of control rat exhibiting normal parts of acrosome (a), post nuclear cap (c), plasma membrane(m), nucleus(n), sub-acrosomal material (p), basal plate(b) and tail region(t). Magnification: X 5000. **B – T** : Different morphological abnormalities observed in head and tail region of sperms in male albino rat. (→) yellow arrow = cytoplasmic droplet ( light & heavy), (→) Red arrow = Absence of sub acrosomal material , swell and the constriction in middle region of sperm head , structural abnormalities in the acrosomal part and plasma membrane and also serration at the connective piece of spermatozoa.

**Table 4:** Fertility study on male rats of treated and recovery group.

	No. of mated male : female (1:2)	No. of Sperm-positive females	No. of Pregnant females	Mating index (%)	Implantation sites / rat	Fertility index (%)
<b>Group I:</b> Control group	4 /8	8	8	100	10.70 ± 1.3	100
<b>Group II:</b> Treated with aqueous extract (200 mg/kg body weight)	4/8	4	0	50	0.00 ** ± 0.00	0.00
<b>Group III:</b> Recovery group	4/8	8	7	100	9.8 ± 1.1	87.5

\*\*Significant (P < 0.01), Group II were compared to Group I (Control) & Group III (recovery).

Results of mating experiment for fertility study showed that, after oral administration of crude extract of the plant for a period of two spermatogenic cycle reduced mating index (50%) but fertility rate was 'zero' when compared to control (Table 4).

## DISCUSSION

Fertility depends on the sperm quality like sperm cell concentration, motility, viability and also the morphology of spermatozoa.<sup>24</sup> The epididymis plays an active role in sperm development and maturation.<sup>25,26</sup> Our present studies showed that the *J repens* extract reduced the relative weights of the reproductive organs without affecting the body weight (Table-1) and it also altered the sperm parameters (Table-2) including sperm morphology (Table-3, Fig. 1,3) significantly which support the non-toxic antigonadal activity of this extract as we reported earlier.<sup>16</sup> Results from present studies showed that extract induced abnormal sperm percentage was 58% which was much more greater than the control group where only around 10% abnormality was found and it also altered other sperm parameters (Table-2). Similar effect with *L.breviflora* Roberts extract induced alterations of sperm parameters were also observed by Saba et al 2009.<sup>27</sup> Chemicals, ions, and other herbal products induced alterations of spermatozoa morphology were also reported by others.<sup>28-30</sup> The andrological parameters are usually considered to determine the fertility of the male individual. Zemjanis in 1977, reported that when critical percentage (>10%) of sperm cell abnormalities were present in the semen, the male subject was considered as infertile.<sup>31</sup> Our studies showed that extract induced different types of sperm morphological abnormalities were 58% (Table-3) which was more than enough to develop infertility and it was confirmed by our fertility assessment study (Table-4). According to classification by Noarkes et al. 2004<sup>32</sup>, the alteration of sperm cells morphology caused by *J.repens* in this study had been grouped into primary, secondary and tertiary abnormalities and found that the sperm cells abnormalities in treated group were mostly primary abnormalities (>39%) where significant abnormalities were found in head regions (Table-3, Fig. 1,3). Bloom in 1977 proposed that primary defects were representing a failure of spermatogenesis in the seminiferous epithelium which was testicular in origin. Secondary abnormalities represented a failure of maturation and abnormal epididymal functions, where tertiary abnormalities develop in vitro.<sup>33</sup> As *J.repens* developed all kinds of sperm abnormalities, it may be assumed that this extract affected the pathways for sperm production and maturation. Extract induced primary abnormalities might be due to aberrations in the process of spermatogenesis.<sup>34,35</sup> Secondary and tertiary abnormalities found in treated group (Table 3, Fig.1,3) might be due to the defect in maturation stages.<sup>36</sup> Presence of cytoplasmic droplets (Fig-3) supported the altered epididymal functions.<sup>37,38</sup> Now it is known that all types of morphological abnormalities are due to the

defect in spermatogenesis which is under the control of steroidogenesis processes. Abnormal sperm head morphology (Figure 3) could be due to the influence of the extract on the differentiation process of spermatogenesis<sup>39,40</sup> and degenerative changes observed in the current study were deleterious for potential reproductive processes as reduced sperm count, viability and increase of morphological abnormalities of sperm likely to decrease fertility.<sup>17</sup> So, any agent which affects these two pathways like spermatogenesis and steroidogenesis will be the cause of formation of abnormal spermatozoa<sup>41</sup> which was further confirmed by our mating experiment (Table - 4) where significant reduction of mating index and zero fertility rate were observed. In our unpublished study, we have seen that oral administration of aqueous extract of *J.repens* (except root) herb inhibit both spermatogenesis and steroidogenesis pathways by inhibiting the factors responsible for these pathways, i.e., testicular ascorbic acid, cholesterol, fructose, Hydroxy steroid dehydrogenase (HSD), plasma and testicular testosterone level etc. (data communicated). It had also reported by others that the morphology of sperm was regarded to be controlled by genes<sup>42-44</sup> and most of the drugs, insecticides or environmental factors induced morphological alterations of spermatozoa were genotoxic or mutagenic<sup>29</sup>, but non-genetic mechanisms were also known to induce morphological alterations where active metabolites of the extract directly act on germ cells.<sup>45,46</sup> Our withdrawal of treatment on fertility experiment showed that *J.repens* induced infertility was reversible, as rapid restoration of sperm parameters (Table-1,2,3) and fertility rates occurred after withdrawal from treatment (Table - 4). So, as *J. repens* is a non toxic antigonadal herb<sup>16</sup> and it is not supposed to cause any permanent damage to male reproductive tissues and shows reversal effects on sperm parameters and fertility index, this extract can be introduced as a potent non-toxic male herbal contraceptive in future.

## CONCLUSION

From the above studies it may be concluded that the crude aqueous extract of *Jussiaea repens* (except root) in a regulated dose and duration can be used as non-toxic, safe, herbal contraceptive for male in future.

**Acknowledgements:** Authors are thankful to the Department of Physiology, Presidency University, Kolkata, India for providing infrastructural facilities to carry out the this research and also grateful to the University Of Burdwan, West Bengal, India for SEM study and their kind encouragement.

## REFERENCES

1. Shin Young-soo, World Health Organization, Medicinal Plants in Papua New Guinea, Western Pacific Regional Publications, 2009, 153.
2. Swapna MM, Prakashkumar R, Anoop KP, Manju CN, Rajith NP, A review on the medicinal and edible aspects of aquatic



- and wetland plants of India, *Journal of Medicinal Plants Research*, 5(33), 2011, 7163-7176.
3. Marzouk MS, Soliman FM, Shehata IA, Rabee M, Fawzy GA, Flavonoids and biological activities of *Jussiaea repens*, *Nat Prod Res*, 21(5), 2007, 436-443.
  4. Firoz A, Selim MST, Shilpi JA, Antibacterial activity of *Ludwigia adscendens*, *Fitoterapia*, 76(5), 2005, 473-475.
  5. Panda A, Misra MK, Ethnomedicinal survey of some wetland plants of South Orissa and their conservation, *Ind J Trad Knowl*, 10(2), 2011, 296–303.
  6. Sunyapridakul L, Chin Ting Sae, Ratdilokpanich Kitti, Poneprasert Sakchai, Chinese Medicinal Plants in northern Thailand, *Chiang Mai Medical Bulletin*, 1983, 137-157.
  7. Kazukuni Y, Anti-Progestational activity of rutin on the rabbit uterus, *Nature*, 207, 1965, 198-199.
  8. Kumar P, Dixit VP, Khanna P, Antifertility studies of Kaempferol, Isolation and Identification from tissue culture of some medicinally important plant species, *Plantes Medicinales et Phytotherapie*, 23(3), 1989, 193 -201.
  9. Singh D, Sharma SK, Shekhawat MS, Yadav KK, Sharma RA, Yadav RK, Antifertility activity of kaempferol-7-O-glucoside isolate from *Cassia nodosa* Bunch, *Electronic Journal of Environmental, Agricultural and Food Chemistry*, 11(5), 2012, 477-492.
  10. Farnsworth NR, Waller DP, Current Status of plant products reported to inhibit sperm, *Research Frontiers in fertility regulation*, 2 (1), 1982, 1-16.
  11. Czczot H, Podsiad M, Effects of quercetin on the induction of sperm abnormalities in mice, *Medycyna Weterynaryjna*, 62(2), 2006, 227-230.
  12. Rastogi PB, Levin RE, Induction of sperm abnormalities in mice by quercetin, *Environmental Mutagenesis*, 9, 1987, 255–260.
  13. Chaudhary R, Gupta RS, Kachhawa J O B S, Singh D, Verma S K , Inhibition of spermatogenesis by Triterpenes of *Albizia lebeck* (L.) Benth pods in male albino rats, *Journal of Natural Remedies*, 7(1), 2007, 86 – 93.
  14. Saharia S, Sarma CM, Ethno-medicinal studies on indigenous wetland plants in the tea garden tribes of Darrang and Udalguri district, Assam, India, *NeBIO*, 2(1), 2011, 27-33.
  15. Banerjee A, Matai S, Composition of Indian aquatic plants in relation to utilization as animal Forage, *J Aquat Plant Manage*, 28, 1990, 69-73.
  16. Pradhan NK, Ghosal S, Chakraborty I, *Jussiaea repens* is a nontoxic antigonadal herb—A dose dependent study on male rats, *Int J Pharm Bio Sci*, 4(2), 2013, 131-143.
  17. Wong WY, Thomas CM, Merkus JM, Zielhuis GA, Steegers Theunissen RP, Male factor subfertility: possible causes and the impact of nutritional factors, *Fertil Steril*, 73(5), 2000, 435-442.
  18. ICMR Bulletin, National Centre for Laboratory Animal Sciences (NCLAS) – A profile, The Indian Council of Medical Research, Published by Shri J N Mathur, New Delhi, 34, (4), 2004, 21-28.
  19. World Health Organization, WHO Laboratory Manual for the Examination of Human Semen and Sperm–Cervical Mucus Interactions, Cambridge, Cambridge University Press, United Kingdom, 4th ed, 1999.
  20. Bjorndahl L, Soderlund I, Kvist U, Evaluation of the one-step eosin nigrosin staining technique for human sperm vitality assessment, *Hum Reprod*, 18, 2003, 813–816.
  21. Bloom E, The ultrastructure of some characteristic sperm defects, *Nord Veterinary Medicine*, 25, 1973, 283.
  22. Areekijserree M, Thongpan A, Vejaratpimol R, Morphological Features of Porcine Oviductal Epithelial Cells and Cumulus-Oocyte Complex, *Kasetsart J (Nat Sci)*, 39, 2005, 136 – 144.
  23. WHO, A Method for Examination of the Effect of Plant Extracts Administered Orally on the Fertility of Male Rats, APF/IP, 99/4E, MB-50, 1983, 1-12.
  24. Garner DL, Hafez E S E, Spermatozoa and seminal plasma, In Hafez ESE (eds), *Reproduction in Farm animals* (6th ed), Lea and Febiger, Philadelphia, USA, 1993, 165-187.
  25. Igboeli G, Foote R H, Maturation changes in bull epididymal spermatozoa, *J Dairy Sci*, 51(10), 1968, 1703-1705.
  26. Blom E, Pathological conditions in the genital organs and in the semen as grounds for rejection of breeding bulls for import or export to and from Denmark, 1985–1982, *Nord Vet Med*, 35, 1983, 105–130.
  27. Saba AB, Oridupa OA, Oyeyemi MO, Osanyigbe OD, Spermatozoa morphology and characteristics of male wistar rats administered with ethanolic extract of *Lagenaria Breviflora* Roberts, *African Journal of Biotechnology*, 8 (7), 2009, 1170-1175.
  28. Mudry Marta D, Palermo Ana M, Merani Mar'ia S, Carballo Marta A, Metronidazole-induced alterations in murine spermatozoa morphology, *Reproductive Toxicology*, 23, 2007, 246–252.
  29. Oliveira H, Spano M, Santos C, Pereira M de Lourdes, Adverse effects of cadmium exposure on mouse sperm, *Reproductive Toxicology*, 28, 2009, 550–555.
  30. Mukhtar Ahmed, R Nazeer Ahamed, Ravindranath H Aladakatti, Mukhtar Ahmed G Ghodesawar, Effect of benzene extract of *Ocimum sanctum* leaves on cauda epididymal spermatozoa of rats, *Iranian Journal of Reproductive Medicine*, 9 (3), 2011, 177-186.
  31. Zemjanis R, Collection and evaluation of semen, In: *Diagnostic and Therapeutic Techniques in Animal Reproduction*, William and Wilkins company, Baltimore, USA, 1977, 242.
  32. Noarkes D E, Parkinson T J, England G C W, Arthur G H, Normal reproduction in male animals, In: *Arthur's Veterinary Reproduction and Obstetrics*, 8th ed, Edinburgh, Saunders Publishers, United Kingdom, 2004, 673–694.
  33. Blom E, Sperm morphology with reference to bull infertility, First All-India symposium on Animal Reproduction, Ludhiana, 1977, 61–81.
  34. Hafez E S E, Advances in reproductive biology and semen evaluations, In: *Reproduction in farm animals*, 5<sup>th</sup> ed, Lea and Febiger, Philadelphia, USA, 1987, 649.

35. Moss J A, Melrose D R, Reed H C B, Vanderplassche M, Spermatozoa, semen and artificial insemination, Bailliere Tindal, London, 1979, 59-91.
36. Tulsiani D R, Orgebin-Crist M C, Skudlarek M D, Role of luminal fluid glycosyltransferases and glycosidases in the modification of rat sperm plasma membrane glycoproteins during epididymal maturation, *J Reprod Fertil Suppl*, 53, 1998, 85-97.
37. Cummins J M, The effect of artificial cryptorchidism in the rabbit on the transport and survival of spermatozoa in the female reproductive tract, *J Reprod Fertil*, 33, 1973, 469-479.
38. Bedford J M, Adaptations of male reproductive tract and the fate of spermatozoa following vasectomy in the rabbit, rhesus monkey, hamster and rat, *Biol Reprod*, 14(2), 1976, 118-142.
39. Thanga K K S, Sakthidevi G, Muthukumaraswamy S, Mohan V R, Anti-fertility activity of whole plant extract of *Sarcostemma secamone* (L) Bennet on male albino rats, *International research journal of pharmacy*, 3 (11), 2012, 139- 144.
40. Oyedeji K O, Bolarinwa A F, Ojeniran S S, Effect of Paracetamol (Acetaminophen) on Haematological and Reproductive Parameters in Male Albino Rats, *International Journal of Pharmaceutical Sciences Review and Research*, 20(2), 2013, 296-300.
41. Rajan T S, Sarathchandran I, Kadalmani B, Comparative antifertility activity of herbal oral contraceptive suspensions in male Wistar albino rats, *Int J Pharm Biomed Res*, 2012, 3(4), 234-246.
42. Hess R A, Bunick D, Lee K H, Bahr J, Taylor J A, Korach K S, Lubahn D B, A role for oestrogens in the male reproductive system, *Nature*, 390, 1997, 509–512.
43. El-Seedy A S, Taha A T, El-Seehy M A bdel- Baith, Maklouf A A, Ultrastructure sperm defects in male mice during carcinogenicity of urethane and indoxan, *Arab J Biotech.*, 9(1), 2006, 27-40.
44. Mathew G, Vijayalaxmi K K, Rahiman M, Methyl parathion-induced sperm shape abnormalities in mouse, *Mutation Research*, 280, 1992, 169-173.
45. Kim I H, Son H Y, Cho S W, Ha C S, Kang B H, Zearalenone induces male germ cell apoptosis in rats, *Toxicol Lett*, 138(3), 2003, 185-192.
46. Mori K, Kaido M, Fujishiro K, Inoue N, Koide O, Hori H, Tanaka I, Dose dependent effects of inhaled ethylene oxide on spermatogenesis in rats, *British Journal of Industrial Medicine*, 48(4), 1991, 270-274.

**Source of Support:** Nil, **Conflict of Interest:** None.