

Research Article



Evaluation of Nephroprotective Effects of *Foeniculum vulgare* Mill, *Solanum Nigrum* Linn and their Mixture against Gentamicin-induced Nephrotoxicity in Albino Rabbits

^aUzma Shaheen, ^{ab}Zahid Manzoor, ^aTanweer Khaliq, ^aAmama Kanwal, ^aFaqir Muhammad, ^aIjaz Javed Hassan, ^{ab}Shaukat Hussain Munawar, ^cMazhar-ul-Haq

^aDepartment of Physiology and Pharmacology, University of Agriculture, Faisalabad-38040, Pakistan.

^bDepartment of Pharmacology and Pharmacy, Faculty of Medicine, The University of Hong Kong, China.

^cDepartment of Pharmaceutical Biosciences, Faculty of Pharmacy, Uppsala University, Sweden.

*Corresponding author's E-mail: dr_hafizzahid@hotmail.com

Accepted on: 21-05-2013; Finalized on: 28-02-2014.

ABSTRACT

The present study aimed to evaluate the nephroprotective effects of different doses of aqueous extract of *Foeniculum vulgare* seeds, *Solanum nigrum* fruit and their mixture on gentamicin induced nephrotoxicity in albino rabbits. For this purpose, a total of 54 adult healthy male albino rabbits were divided into nine groups comprising 6 animals each. Group-I served as normal control group. All other groups (group-II to group-IX) were administered gentamicin intra-peritoneal at dose rate of 80mg/kg body weight. Group-III was treated with a nephroprotective agent silymarin at dose rate of 200mg/kg/oral. Group-IV, group-V, group-VII and group-VIII were treated with extracts of *Foeniculum vulgare* and *Solanum nigrum* at dose rate of 250 and 500 mg/kg/oral respectively, whereas group-VI and group-IX were treated with mixture of both plants at dose rate of 250 and 500mg/kg/oral. Group-II was kept untreated and served as negative control. All the treatments were continued for 21 days. Blood samples were taken from all groups at day 21 and concentration of serum urea, creatinine, albumin, plasma malondialdehyde and catalase were determined. Histopathological parameters of kidneys were also examined at day 21. Data were analyzed using analysis of variance (ANOVA) and Duncan multiple range test. Gentamicin induced oxidative stress and caused structural changes in the kidneys. The aqueous extract of *Foeniculum vulgare* seeds, *Solanum nigrum* fruit and their mixture significantly prevented renal damage by normalizing increased levels of renal markers. Mixture of both plants at high doses exhibited improved nephroprotective and antioxidant activities. The correction of oxidative stress biomarkers was consistent with amelioration of the histopathological changes induced by gentamicin. Hence, it is suggested that ameliorative effect of aqueous extract of *Foeniculum vulgare*, *Solanum nigrum* and their mixture against gentamicin induced kidney damage may be attributed to their antioxidant properties.

Keywords: *Solanum nigrum*, *Foeniculum vulgare*, Gentamicin, Nephrotoxicity, Rabbits.

INTRODUCTION

Aminoglycoside antibiotics have long been employed as antibacterial remedy, particularly against gram negative bacterial infections since the beginning of twentieth century.^{1,2} Besides their beneficial effects, aminoglycoside possess considerable side effects. The most common adverse effects are nephrotoxicity and ototoxicity.³ Among aminoglycosides, gentamicin (GM) is considered highly nephrotoxic agent.⁴ It damages the tubular cells lacking morphological changes in glomerular structures.¹ The exact mechanism involved with GM-induced cell injury is not clearly understood but it is reported that gentamicin provoke free radical generation that implicates a variety of pathological processes.⁵ Moreover, reactive oxygen species (ROS) is supposed to an important mediator in gentamicin-induced nephrotoxicity.⁶ ROS bind to some macromolecules leading to cellular injury and necrosis through several mechanisms such as protein denaturation, peroxidation of membrane lipids, and DNA damage.^{7,8} Many attempts have been made and a variety of compounds have been used successfully to combat GM-induced nephrotoxicity.^{9,10}

Ancient literature has prescribed various herbs for the treatment of kidney diseases. Global estimates show that

80% of about 4 billion world population cannot afford synthetic pharmaceutical products, hence depend upon traditional medicines derived from plant origins.¹¹ Plants have effectively been used against a variety of diseases worldwide since the start of mankind.¹² Traditional system of medicine continues to practice today. In the past few years, many researchers¹³⁻¹⁵ have investigated a number of plants used traditionally by indigenous healers and herbalists to support renal functions or treat kidney disorders. Several hundred herbs and plants are found helpful against renal disturbances.¹⁶

Foeniculum vulgare (*F. vulgare*) Mill is an aromatic plant belongs to "*Apoieceae*" family, used as culinary spice and traditional medicine. The fennel of the plant primarily contains monoterpenes, fenchone limonene, sterols, coumarines, piperitone, piperitone oxide, chlorogenic acid and caffeic acid. Moreover, *F. vulgare* also possesses camphor and alphapinen with free radical scavenging activity. In addition, essential oils of fennel provide unique aroma, taste and acquire antibacterial, antifungal, relaxant, estrogenic, analgesic and anti-inflammatory actions. Fruits of the plant have diuretic, analgesic, antipyretic and antioxidant activities.¹⁷

Solanum nigrum (*S. nigrum*) Linn is a medicinal branched herb belongs to the family "*Solanaceae*" and have



beneficial effects against cancer, ulcer, and microbial infections. It has the ability to eliminate hydroxyl radicals by preventing oxidative damage and possesses antiseptic, antispasmodic, immunomodulating and anticonvulsant activities. A number of essential phytoconstituents are present in *S. nigrum* that induce biological responses. One of the important phytoconstituent is steroidal saponins; which have antihyperlipidemic action by reducing blood cholesterol. In addition, 150 KDa glycoproteins is another vital constituent and provoke the activities of superoxide dismutase, catalase, glutathione peroxidase. Moreover, some researchers^{18,19} have revealed the cholesterol lowering property of glycol proteins and free radical eliminating activity of this plant.

Several pharmacological uses of the *F. vulgare* and *S. nigrum* have been described in the literature^{17,20,21} but no any study exists regarding its nephroprotective activity. Therefore, the present study has been planned to evaluate the nephroprotective effects of aqueous extracts of seeds (*F. vulgare*, fruits and *S. nigrum*) and their mixture with different doses against gentamicin-induced nephrotoxicity. We attempted to test and compare the possible nephroprotective activity if any, with Silymarin: a known nephroprotective herbal drug. In addition, we have also examined serum urea and creatinine levels in order to estimate renal function and malondialdehyde (MDA) and catalase levels to evaluate oxidative and antioxidative status.

MATERIALS AND METHODS

Collection and identification of plants

The fruits of *S. nigrum* and *F. vulgare* seeds were procured from local market of Faisalabad. Fruits and seeds were identified and authenticated by Dr. A. Rubina, Department of Botany, University of Agriculture, Faisalabad, Pakistan. Certificates of authentication were submitted in the Department of Physiology and Pharmacology, University of Agriculture, Faisalabad. Shade dried fruit's extract were used for the study.

Preparation of Extract

Fruits were cut and shade dried and powdered to 40 mesh and stored in airtight container till further use. Methanolic extract was prepared with the help of Soxhlet apparatus and solvent was evaporated at 40°C in rotary evaporator.

Preliminary phytochemical analysis

The powdered *F. vulgare* seeds and fruits of *S. nigrum* were investigated for qualitative determination of the following phytoconstituents.

Test for Tannins

Alcoholic ferric chloride solution (10%) was added in 2-3ml of methanolic extract as 1:1 ratio. Development of dark blue or greenish grey color of the solution was considered as positive for the presence of tannins.²²

Test for Saponins

0.5ml of filtrate was added in 5ml of distilled water and solution was shaken vigorously. Persistence frothing indicated the presence of saponins.²³

Test for Terpenoids

5ml of aqueous extract, 2ml of chloroform and 3ml of concentrated sulphuric acid was mixed. A reddish brown coloration of the interface formed suggested the presence of terpenoids.²⁴

Test for Phenols

The sample was dissolved in water or a mixture of water and ethanol. Few drops of dilute ferric chloride solution were added to this mixture. Appearance of a red, blue, green or purple coloration indicated the presence of phenols.²⁵

Test for Flavonoids

Flavonoids were tested by heating 1 g powdered sample with 10 ml ethyl acetate over a steam bath (40–50°C) for 5 min; filtrate was treated with 1 ml dilute ammonia. A yellow coloration demonstrated positive test for flavonoids.²⁶

Test for Glycoside

2ml filtrate was mixed with 1ml of glacial acetic acid, 1ml of ferric chloride and 1ml of concentrated sulphuric acid. Indication of green-blue color suggested the presence of glycosides.²³

Test for Ascorbic Acid

2ml of 2% sample solution (w/v) was mixed with 2ml of water, 0.1g of sodium bicarbonate and 20mg of ferrous sulphate. Mixture was shaken and allowed to stand; a deep violet color was appeared; 5ml of 1M sulphuric acid was then added, disappearance of this color confirmed the positive result.²⁷

Test for Reducing Sugars

Fehling solution was added as a test reagent to the sample. Appearance of a radish brown precipitate of cuprous oxide indicated the presence of combine reducing sugars.²⁵

Test for Steroids

2 ml of acetic anhydride and 2 ml of concentrated sulphuric acid was added to 1 ml of extract. Change in color from blue to green indicated the presence of steroids.²⁴

Test for Total Sugars

Molish test was performed for the detection of sugar. 3 ml of the aqueous extract was added to 2 ml of Molisch's reagent and the resulting mixture was shaken properly. 2 ml of concentrated H₂SO₄ was then poured carefully down the side of the test tube. Formation of a red or dull violet color at the interphase of the two layers was indicative of positive test.²⁵

Test for Alkaloids

Alkaloid detection was carried out by extracting 1 g powdered sample with 5 ml methanol and 5 ml of 2N HCl; and then treating the filtrate with Meyer's and Wagner's reagents. The sample was scored positive on the basis of turbidity or precipitation.²⁶

Drug

Commercially available preparation of gentamicin, Gentacin[®] (Gentamicin sulphate, 80mg/2ml) manufactured by Abbott Laboratories was used for the experiment.

Animals

Fifty four adult male healthy albino rabbits were purchased from the local market of Faisalabad. The animals were housed in animal room at the department of Physiology and Pharmacology, University of Agriculture, Faisalabad. The care and use of the laboratory animals were performed in accordance with the guidelines and under the approval from the Animal Ethics Committee (AEC) of the university. Animals were acclimatized to the experimental room of department of Physiology and Pharmacology having ambient temperature (23±2°C), controlled humidity (55±5%) conditions, and 12:12 hour light and dark cycle. Animals were caged individually and fed seasonal fodder till the completion of experiment. Drinking water was provided *ad libitum* and feed was offered twice a day (morning and evening). Except normal control group, all animals of other groups were administered Gentacin[®] @ 80mg/kg body weight intra-peritoneal for 21 days.

Arrangement of animals into groups

Fifty four animals were divided into nine groups; each group consisted of 6 animals and they received the treatment as follows:

Group-I: Normal control group

Group-II: Gentamicin-administered (80mg/kg), untreated control

Group-III: Treated control (Gentamicin 80mg/kg + Silymarin 200mg/kg/oral)

Group-IV: Treated with aqueous extract of *F.Vulgare* 250mg/kg/oral + Gentamicin 80mg/kg

Group-V: Treated with aqueous extract of *S. nigrum* 250mg/kg/oral + Gentamicin 80mg/kg

Group-VI: Treated with aqueous extract of Mixture 250mg/kg/oral + Gentamicin 80mg/kg

Group-VII: Treated with aqueous extract of *F.Vulgare* 500mg/kg/oral + Gentamicin 80mg/kg

Group-VIII: Treated with aqueous extract of *S. nigrum* 500mg/kg/oral + Gentamicin 80mg/kg

Group-IX: Treated with aqueous extract of Mixture 500mg/kg/oral + Gentamicin 80mg/kg

Biochemical estimation

2 ml of blood samples were drawn at 21st day from the jugular vein of rabbits of all experimental groups. Blood samples were centrifuged at 1507g for 15 minutes. Serum were separated in small aliquotes and stored at -20°C. Concentration of creatinine, urea and albumin were determined from serum samples by using commercially available kits (DiaSys Diagnostic Systems GmbH Alte Strasse (9) 65558 Holzheim Germany).

Histopathological analysis

At 21st day, three animals from each group were sacrificed. Parts of kidneys were embedded in formalin, processed in graded ethanolic concentrations and fixed in paraffin blocks. Morphometric measurements were completed on Olympus PM – 10ADS automatic light microscope (Olympus optical Co., Tokyo, Japan) with a 40X objective and calibrated ocular micrometer.

Statistical analysis

The data are reported as means ± standard error of the mean (SEM). Statistical analysis was performed by one way analysis of variance (ANOVA), Duncan Multiple Range Test (DMRT), using SPSS[®] for Windows computing program (version 17.0). *P*<0.01 was considered statistically significant.

RESULTS

Phytochemical investigation of *F. vulgare* seeds and fruits of *S nigrum* revealed the presence of various bioactive constituents (Table-1). Both plants have almost all the major phytoconstituents except glycosides in *S. nigrum* and steroids in *F. vulgare*.

Table 1: Preliminary phytochemical analysis of *F. vulgare* and *S. nigrum*

Phytoconstituents	<i>F. vulgare</i>	<i>S. nigrum</i>
Tannins	+	+
Saponin	+	+
Terpenoids	+	+
Phenols	++	++
Flavonoids	++	++
Glycosides	±	-
Ascorbic acid	++	++
Free reducing sugar	+	+
Steroids	-	+
Total Sugars	++	++
Alkaloids	+	+

**Strong positive, +Trace, - Negative

Serum creatinine

Serum creatinine was significantly increased (1.06±0.07 mg/dl) in the GM-treated renal injury group, when compared to the control group (0.65±0.01 mg/dl; *P*<0.01) (Table 2). The increase induced by GM was completely attenuated by all the treated groups, displaying their

nephroprotective action. However, group-IX had the numerically lowest value of serum creatinine as compared to control group, indicating their improved nephroprotective activity

Table 2: Effect of *Foeniculum vulgare*, *Solanum nigrum* and their mixture on serum levels of urea, creatinine, albumin, plasma malondialdehyde and catalase in albino rabbits

Groups	Creatinine (mg/dl)	Urea (mg/dl)	Albumin (g/dl)	Malondialdehyde (MDA) nmol/L	Catalase (KU/L)
Group-I (Normal Control)	0.65±0.01 ^{BC}	60.63±1.27 ^{CD}	4.70±0.14 ^B	6.02±0.17 ^F	48.14±0.84 ^A
Group-II GN (80mg/kg)	1.06±0.07 ^A	85.67±3.73 ^A	2.80±0.14 ^F	18.36±1.60 ^A	28.23±2.10 ^H
Group-III GN + S (80 +200 mg/kg)	0.75±0.04 ^B	60.00±2.54 ^{CD}	4.50±0.17 ^{BC}	6.19±0.22 ^F	47.93±0.79 ^A
Group-IV GN +FV-I (80 +250mg/kg)	0.75±0.03 ^B	68.04±1.80 ^B	3.50±0.20 ^D	12.07±0.89 ^C	36.12±0.93 ^F
Group-V GN + SN-I (80 +250mg/kg)	0.71±0.02 ^{BC}	67.58±1.60 ^{BC}	3.50±0.19 ^D	14.15±1.16 ^B	34.01±1.55 ^G
Group-VI GN + Mix-I (80 +250mg/kg)	0.68±0.03 ^{BC}	62.75±1.83 ^C	4.68±0.15 ^B	10.25±0.80 ^D	37.87±1.56 ^E
Group-VII GN +FV-II (80 +500mg/kg)	0.65±0.02 ^{BC}	56.50±2.70 ^E	4.29±0.15 ^C	8.02±0.62 ^E	42.04±0.95 ^C
Group-VIII GN + SN-II (80 +500mg/kg)	0.73±0.07 ^B	58.21±2.43 ^D	4.24±0.15 ^C	10.16±0.60 ^D	40.01±1.11 ^D
Group-IX GN + Mix-II (80 +500mg/kg)	0.58±0.02 ^C	56.21±2.45 ^E	5.00±0.20 ^A	7.07±0.36 ^{EF}	45.80±0.99 ^B

^{A-H} Means sharing with superscripts within a column do not differ (P<0.01), GN= Gentamicin, S= Silymarin, FV= *F. Vulgare*, SN= *S. nigrum*, M= Mixture

Serum urea levels

GM treatment for twenty one days resulted in significant increase in serum urea level compared to control rabbits (Table 2). However, elevations in the blood urea were significantly (P<0.01) attenuated by all the treated groups indicating their nephroprotective activities. Group-VII and group-IX exhibited more positive nephroprotective effects having significantly (P<0.01) lower values of urea level when compared to normal values.

Albumin

Albumin concentration was significantly (P<0.01) lower in GM-treated group as compared to normal control group (Table 2). All the treated groups significantly reversed the lowered values of albumin induced by GM indicating their positive effects to renal damage. However, plants mixture at higher doses (group-IX) exhibited substantial higher values of albumin, whereas group-IV and group-V showed significantly (P<0.01) lower values of albumin in comparison to normal control group. Plant extracts alone at higher doses (group-VII) and (group-XIII) also displayed considerable lower concentration of albumin as compared to normal control group though group-III and group -VI did not differ significantly when compared to control values.

MDA

Level of MDA was significantly increased (18.36±1.60 nmol/L) in the GM-treated group, when compared to the control group (6.02±0.17 nmol/L) (Table-2). Higher values of MDA indicate the oxidative stress in GM treated group. The increase in MDA level was completely attenuated by group-III followed by group-VII, group-XIII, group-IV, and group-V respectively. However, group-VI had the similar values as compared to group-VIII and group-IX did not differ considerably (P<0.01) when compared to group-III and group-VII.

Catalase

GM treated group revealed significantly (P<0.01) lower values of catalase as compared to normal control group (Table 2). All the treated groups significantly (P<0.01) reversed the lower values of catalase induced by GM administration indicating their antioxidant activities. Group-III had the considerable higher concentration of catalase, followed by group-IX, group-VII, group-VIII, group-VI, group-IV and group-V respectively as compared to normal control group though group-III did not vary considerably when compared to control values.

Histopathological analysis

The histopathological changes in kidneys in all groups are summarized in Table 3.

Table 3: Histopathological features as seen in the kidney in the gentamicin model

Histopathological features	Group I	Group II	Group III	Group IV	Group V	Group VI	Group VII	Group VIII	Group IX
Glomerular congestion	-	+++	-	-	++	+	-	+	-
Peritubular congestion	-	+++	+	-	+	-	-	+	-
Epithelial desquamation	-	++	-	-	-	+	-	-	-
Blood vessel congestion	-	+++	-	-	-	-	-	-	-
Inflammatory cells	-	+++	-	+	++	-	-	-	-
Necrosis	-	+++	+	+	++	+	+	+	-
Connective tissue proliferation	-	+++	-	+	++	-	-	+	-
Peritubular dilation	-	-	-	-	-	-	++	+	-

*(-): normal; (+): little effect; (++) : appreciable effect; (+++): severe effect

Light microscopic examination of kidneys from control and Mix-II (group-IX) rabbits showed no structural alterations in renal tissues (Fig. A and Fig. D). Massive and diffuse cell necrosis was observed in the proximal tubules of kidneys from rabbits injected with gentamicin. In addition, the lumens of these tubules were filled with degenerate and desquamated epithelial cells and hyaline casts. Pyknotic and karyolytic changes were seen in the nucleus. Severe inflammatory infiltrate in the form of mononuclear cells were observed in the renal sections of this group (Fig. B). Kidney specimens from rabbits treated with GM and Silymarin (group-III) revealed significant improvement in glomeruli and renal tubules, evidenced by preservation of tubular histology with mild coagulative necrosis compared with the GM treated group (Fig. C).

DISCUSSION

In spite of age, race, environmental and geographical variations, nephropathy is one of the important health hazards all over the world. The etiology behind this renal problem is widely ranging from substance induced to physiological and various metabolic complications, grading the nephropathy amongst the 10th leading causes of death throughout the world. Medical literature has described an increase incidence of nephrotoxic acute renal failure (ARF), especially with antibiotics use being the major cause, among which the aminoglycosides are most common. Elevation of urea and creatinine levels in serum was considered as the index of nephrotoxicity. Thus, in the current study, biochemical parameters such as blood urea and creatinine clearance have been estimated to investigate the nephroprotective effects of *F. vulgare*, *S. nigrum* and their mixture against GM-induced nephrotoxicity in animals.

GM nephrotoxicity is manifested clinically as nonoliguric renal failure, with a slow rise in serum creatinine and hypoosmolar urinary output developing after several days of treatment. At physiologic pH, the drug is highly charged and water soluble, and therefore it is practically unable to diffuse through biologic membranes. In addition, suppression of free radical defense mechanism has also been observed because selective accumulation of gentamicin in kidney can induce oxidative stress leading to lipid peroxidation. It can mediate the generation of

reactive oxygen species (ROS) mostly in mitochondria that can induce renal injuries.²⁸ Morphologically, cellular necrosis, large lysosomes and myeloid bodies have been observed in the kidney. Even in the absence of major changes in membrane permeability, the failure of plasma membrane pumps will cause potential changes in the cation homeostasis of the cell e.g. Na-K-ATPase and Ca-ATPase pumps.²⁹

Many researchers^{30,31,32} have reported the renal toxicity of GM at dose rate of 100 mg/kg intra-peritoneal. It is suggested that after glomerular filtration, GM is actively transported into proximal tubules, here it accumulates and damages the tubular cells, hence; alters the renal circulation leading to reduced glomerular filtration rate (GFR).³³ The major etiology behind this complication may be induction of oxidative stress which is the most common pathogenic inducer. In addition, another possible mechanism regarding the action of gentamicin is that gentamicin may increase the production of hydrogen peroxide (H₂O₂), and it is well known that oxygen and H₂O₂ causes the contraction of mesangial cells, modify the filtration surface area and ultimately reduce the GFR. Oxygen radical interacts with nitric oxide (NO): a vasodilator, and forms a cytotoxic oxidant species i.e. peroxynitrite. This inactivation of NO by oxygen might be responsible for decrease in the GFR but the exact mechanism is not well known. However, GM-induced damage confers high level of creatinine in serum.

The results of gentamicin-induced nephrotoxicity in the present study are in line with those documented previously.^{1,34,35} GM activates the platelets activation factor causing local vasoconstriction and thus restricts the renal blood flow and ultimately GFR. Many studies support that oxidative stress is the major contributor in GM-induced nephrotoxicity.^{35,36}

Urea is the nitrogen containing end product of protein catabolism. The concentration of urea is elevated when GFR is markedly decreased in renal pathies. Moreover, urea concentration begins to rise only after parenchymal tissue damage.³⁷ Thus, serum urea concentration is sometimes considered a more reliable renal function predictor than serum creatinine. In this study, urea concentration is significantly (P≤0.01) increased in GM-

treated group as compared to normal control group. The results of present study are in line with those reported previously.^{1,34,35} *F. vulgare* at high doses (group-VII) alone and mixture of *F. vulgare* and *S. nigrum* at high doses (group-IX) exhibited nephroprotective effects by significantly lowering the serum urea level. The possible reason behind the serum urea accumulation may be an increase rate of serum urea production than the clearance rate.

Creatinine derives from endogenous sources by tissue creatinine breakdown and its clearance enables a quite good estimation of the GFR. Plasma creatinine concentration is an important index than the urea concentration in the first phases of kidney disease. In the present study, mean serum concentration of creatinine increased significantly ($P \leq 0.01$) in GM treated group as compared to normal control group. All the medicated groups displayed nephroprotective action by lowering the serum creatinine level when compared to group-II values.

Majority of the medicinal plants have some organic compounds which provide definite physiological functions; these bioactive substances include tannins, alkaloids, flavonoids, saponins, glycosides, carbohydrates, etc. Data revealed the presence of all the bioactive constituents in *F. vulgare* and *S. nigrum* except steroids and glycosides respectively. The phytoconstituents detected in the plant materials may be responsible for their nephroprotective activity. In addition, these bioactive molecules also possess antioxidant activity.³⁹ *F. vulgare* is a source of bioactive compounds (ascorbic acid, phenolics and terpenoids) with potential health promoting actions. Flavonoids are oxidized by radicals resulting in a more stable and less reactive radical. Flavonoids can also inhibit the activity of many enzymes such as xanthine oxidase, peroxidase and nitric oxide synthase, which are supposed to involve in free radical generation, thereby resulting in decreased oxidative damage of macromolecules. Herbal mixture of both plants alone exhibited varying degree of therapeutic effects in renal damage whereas combination of both plants mixture displayed synergistic effect.

Albumin is the main contributor to the plasma osmotic pressure and is synthesized in the liver. It helps in the transport of drugs, hormones and enzymes. Albumin level decreases in kidney disorders, malnutrition, increased fluid loss during extensive burns, and decreased absorption in gastrointestinal diseases.⁴⁰ Hypoalbuminemia may result from impaired synthesis, loss through urine or feces, or increased catabolism.⁴¹ The results of albumin revealed that mean serum concentration of albumin (g/dl) decreased significantly ($P \leq 0.01$) in GM treated group as compared to normal control group. These results are in accordance with the results^{42,43} which states that total protein content decreased possibly due to destruction of protein synthesizing subcellular structures in GM-induced nephrotoxicity. Moreover, increased free radical production and defective protein synthesis may be some

other causes of decreased protein contents. On the other hand, significantly ($P \leq 0.01$) higher values of albumin in group-IX exhibited its nephroprotective effects when compared to normal values. Similar protective studies of different extracts against GM have been reported previously.^{37,44,45}

In the present study, MDA level was significantly increased whereas catalase level was decreased noticeably in GM treated group as compared to control group. It has been proposed that oxidative stress may be responsible for tubular damage. It is well known that the production of ROS causes cell damage due to cytotoxic action of oxygen and nitrogen derived free radical species. Lipid peroxidation (LP) has a relationship with the release of lysosomal enzymes. Hence, LP activates the phospholipases and removes the peroxidized lipid from the membrane.⁴⁶ The oxidation of unsaturated fatty acids in biological membranes by free radical leads to a decrease in membrane fluidity and disruption of membrane structure and function.⁴⁷ The present results confirm the earlier findings⁴⁸ and concluded that GM administration caused severe damage to renal tissues most likely by ROS mediated mechanism as evident by decreased activities of antioxidant enzymes that led to increased lipid peroxidation (LP). In addition, a highly significant increase of lipid peroxidation activity was reported in this study, these observations are in agreement with those reported earlier.⁴⁹

GM exposure to rabbits mediates the generation of ROS that could play a significant role in the progression of renal injuries including array of biomolecules such as membrane lipids, protein and nucleic acids particularly in some organelles like mitochondria and lysosomes of renal tissues. Increased propagation of ROS confers the peroxidation of attached polyunsaturated fatty acids to biomembranes. GM-induced lipid peroxidation impaired the cellular function and provokes necrosis. This evolution of ROS may stimulate the activation or expression of proinflammatory mediators which could contribute to progressive kidney damage induced by GM. Proinflammatory mediators have a critical role in mediating inflammation, apoptosis, and growth in disease. Activation of mediators, in response to oxidative stress may play a role in GM-induced nephrotoxicity by inducing synthesis of inflammatory substances (cytokines, growth factors, and adhesion molecules) that provoke kidney damage. Thus, blockage of proinflammatory mediators will be an effective approach for treatment of nephrotoxicity. GM also causes renal phospholipidosis via inhibition of lysosomal hydroxylase, such as sphingomyelinase and phospholipidase in conjunction with oxidative stress leading to nephrotoxicity.

LP of renal tissues induced with GM was prevented in group-IX by significantly decreased MDA level whereas catalase activities were increased substantially as compared to group-II in dose dependant manner. Both *F. vulgare* and *S. nigrum* exhibited synergistic effect in mixture as compared to when treated alone in dose



related manner. As mixture, having strong antioxidant and cellular anti-inflammatory properties improved the oxidant status. The nephroprotective activity of herbal mixture acting synergistically, may be due to the presence of phytochemicals like flavonoids, also its ability of anti-inflammatory activity and antioxidant status. It is well acknowledged that many phenolic compounds, present in *F. vulgare* and *S. nigrum*, exert powerful antioxidant effects. Therefore, they could inhibit LP by scavenging ROS. The protective effect of *F. vulgare* and *S. nigrum* in the present study, against gentamicin induced nephrotoxicity is in harmony and supports the previous reports indicating the antioxidant potential.

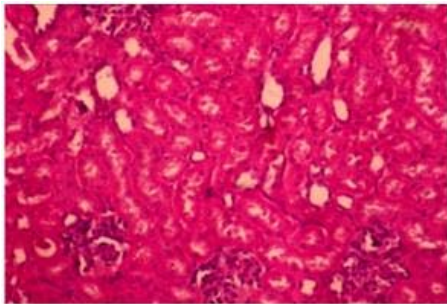


Figure A

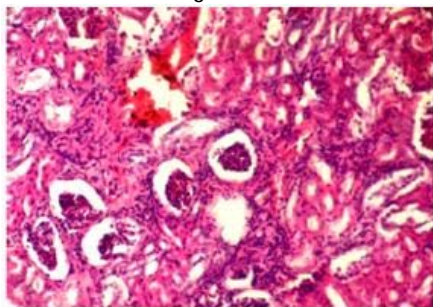


Figure B

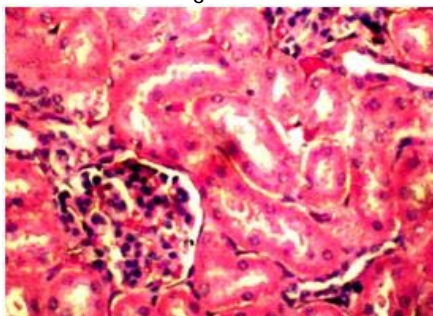


Figure C

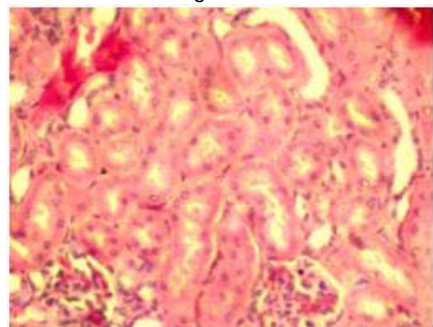


Figure D

Fig.A= Normal control group (group-I), Fig. B= Gentamicin treated group (group-II), Fig.C= Silymarin treated group

(group III), Fig. D= Plant mixture treated group at high doses (group-IX)

GM induces conspicuous and characteristic changes in lysosomes of proximal tubular cells consistent with the accumulation of polar lipids (myeloid bodies). These changes are preceded and accompanied by signs of tubular dysfunctions or alterations (release of brush border and lysosomal enzymes; decreased reabsorption of filtered proteins).⁵⁰ In current study, group II exhibited severe necrotic changes in the proximal convoluted tubule. These include: pyknotic nuclei, hyperchromatic and massive dilation of the capillaries, massive tubular epithelial cell necrosis, karyorehexis and karyolytic changes in the nucleus, severe congestion with massive glomeruli tuft lobulation and necrosis. Increase in intracellular free oxygen radicals can initiate irreversible cellular injury process leading to tubular necrosis and tubular degeneration in renal tissues. Scavenging of free oxygen radicals prevent irreversible renal cell injury and necrosis.

Many studies proposed that mediation of reactive oxygen may have linked with degenerative tubular effects of gentamicin.⁵¹ In a study, reactive oxygen species have been identified as inducers of proximal tubular necrosis and acute renal failure in gentamicin-induced nephrotoxicity.⁵¹ In current study tubular necrosis, as a sign of irreversible injury in most sections examined from group II. *F. vulgare* and herbal mixture as an antioxidant inhibits lipid peroxidation and prevents renal cell injury. The results of the present study showed that *F. vulgare* and mixture treatment affected biochemical values in line to pathological findings.

CONCLUSION

The results of the present study showed that the aqueous extract of *F. vulgare*, *S. nigrum* and their mixture can offer protection against the deleterious renal side effects of gentamicin. According to the biochemical findings, which were supported by histopathological evidences, administration of mixture of *F. vulgare* and *S. nigrum* synergistically abolished nephrotoxic effects of gentamicin as compared to individual plants. The current study also suggests the possible mechanism for renal protection might be attributed for its free radical scavenging and antioxidant activity of its phenolics and flavonoids components. Phenolic compounds from dietary plants are known to be good scavengers of reactive oxygen species. In the past few decades, a considerable and consistent amount of evidences have demonstrated that *F. vulgare* and *S. nigrum* have antioxidant and anti-inflammatory properties. It is well known that all non-steroidal anti-inflammatory drugs inhibit prostaglandin E synthesis. Thus, it may be possible that *F. vulgare* and *S. nigrum* because of its anti-inflammatory activity can inhibit the biosynthesis of prostaglandins. In addition, alkaloids have also been reported to strongly inhibit lipid peroxidation induced in isolated tissues via its antioxidant activity. The presence

of alkaloids could be the reason of protection offered by the plants possibly due to its ability to activate anti-oxidant enzymes. Therefore it is mandatory to conduct the chemical characterization to isolate and evaluate newer active phytoconstituents in order to develop the therapeutics that have a promising role in the treatment of renal dysfunction diseases induced by xenobiotics.

REFERENCES

- Karahan I, Atessahin A, Yılmaz S, Ceribas AOC, Sakin F, Protective effect of lycopene on gentamicin-induced oxidative stress and nephrotoxicity in rats, *Toxicology*, 3(215), 2005, 198–204.
- Mwengee W, Butler T, Mgema S, Mhina G, Almasi Y, Bradley C, Formanik JB, Rochester CG, Treatment of plague with gentamicin or doxycycline in a randomized clinical trial in Tanzania, *Clinical Infectious Diseases*, 5(42), 2006, 614–621.
- Pavle R, Slavimir V, Nenad S, Ljubinka JV, Dusan S, Milan S, Ivan I, Salicylic acid attenuates gentamicin-induced nephrotoxicity in rats, *The Scientific World Journal*, 2012, 1-6.
- Suzuki SS, Takamura J, Yoshida Y, Shinzawa N, Tamatani SR, Comparison of gentamicin nephrotoxicity between rats and mice, *Comparative Biochemistry and Physiology*, 1, 1995, 15-28.
- Conlon BJ, Aran JM, Erre JP, Attenuation of aminoglycoside induced cochlear damage with the metabolic antioxidant alpha-lipoic acid, *Hearing Research*, 128, 1999, 40-44.
- Banday AA, Farooq N, Priyamvada S, Yusufi ANK, Khan F, Time dependent effects of gentamicin on the enzymes of carbohydrate metabolism, brush border membrane and oxidative stress in rat kidney tissues, *Life Sciences*, 9-10(82), 2008, 450–459.
- Baliga R, Zhang Z, Baliga M, Ueda N, Shah SV, In vitro and in vivo evidence suggesting a role for iron in cisplatin-induced nephrotoxicity, *Kidney International*, 2(53), 1998, 394–401.
- Parlakpınar H, Tasdemir S, Polat A, Bay-Karabulut A, Vardi N, Ucar M, Acet A, Protective role of caffeic acid phenethyl ester (CAPE) on gentamicin-induced acute renal toxicity in rats, *Toxicology*, 2(207), 2005, 169–177.
- Ali BH, Agents ameliorating or augmenting experimental gentamicin nephrotoxicity: some recent research, *Food and Chemical Toxicology*, 11(41), 2003, 1447–1452.
- Stojiljkovic N, Stojiljkovic M, Randjelovic P, Veljkovic S, Mihailovic D, Cytoprotective effect of vitamin C against gentamicin-induced acute kidney injury in rats, *Experimental and Toxicologic Pathology*, 1-2(64), 2012, 69–74.
11. Brinda P, Sridharan G, Pradeep V, Sasikumar S, Antitumor activity and In vivo antioxidant status of *Hyptis suaveolens* against *Ehrlich ascites* carcinoma in swiss albino mice, *Investigational New Drug*, 45, 2008, 10-14.
- Ahmed SS, Wahid A, Bukhsh E, Ahmed S, Kakar SR, Antihyperlipidemic properties of *Carthamus oxyacantha*, *Pakistan Journal of Science*, 61(2), 2009, 116-121.
- Yamamura Y, Kotaki H, Tanaka N, Aikawa T, Iga T, Pharmacokinetics of glycyrrhizin and its restorative effect on hepatic function in patients with chronic hepatitis and in chronically carbon tetrachloride intoxicated rats, *Biopharmaceutics and Drug Disposition*, 18, 2010, 717-725.
- Prabakan M, Anandan R, Devaki T, Protective effect of *Hemidesmus indicus* against rifampicin and isoniazid induced hepatotoxicity in rats, *Fitoterapia*, 71, 2000, 55-59.
- Rajeshkumar NV, Kuttan R, *Phyllanthus amarus* extract administration increases the life span of rats with hepatocellular carcinoma, *Journal of Ethnopharmacology*, 73, 2000, 215-219.
- Manjula M, Indina V, Phasarathem P, Phytochemical Characterization and antibacterial activity screening of *Achyranthes aspera*, *Asian Journal of Microbiology, Biotechnology and Environmental Sciences*, 11, 2009, 365-368.
- Ostad SN, Soodi M, Shariffzadeh M, Khorshidi N, Arzban HM, The effects of toxicology study, *Journal of Ethnopharmacology*, 76, 2001, 299-304.
- Lee SJ, Lim, 150-kDa glycoprotein isolated from *Solanum nigrum* Linn stimulates caspase-3-activation and reduces inducible nitric oxide Production in HCT-116 cells, *Toxicology*, 20(7), 2006, 1088-1097.
- Zhou X, He X, Wang G, Gao H, Zhou G, Ye W, Yao X, Steroidal saponins from *Solanum nigrum*, *Journal of Natural Products*, 69(8), 2006, 1158-1163.
- Ozbek H, Ugras S, Dulger H, Hepatoprotective effects of *Foeniculum vulgare* essential oil, *Fitoterapia*, 74, 2003, 317-319.
- Lee SJ, Lim KT, Antioxidative effects of glycoprotein isolated from *Solanum nigrum* Linn on oxygen radicals and its cytotoxic effects on the MCF-7 cell, *Journal of Food Science*, 68, 2003, 466-470.
- Kumar G, Jayaveera K, Kumar C, Sanjay UP, Swamy B, Kumar D, Antimicrobial effects of Indian medicinal plants against acne-inducing bacteria, *Tropical Journal of Pharmaceutical Research*, 6, 2007, 717-723.
- Parekh J, Chanda SV, In vitro antimicrobial activity and phytochemical analysis of some Indian medicinal plants, *Turkish Journal of Biology*, 31, 2007, 53–58.
- Edeoga H, Okwu D, Mbaebie B, Phytochemical constituents of some Nigerian medicinal plants, *African Journal of Biotechnology*, 4, 2005.
- Sofowora A, Medicinal plants and traditional medicine in Africa, Spectrum Books, 1993.
26. Harborne JB, Phytochemical methods, A guide to modern techniques of plant analysis, New Delhi, Springer Private limited, India, 2005, 124.
27. Ganesan S, Bhatt R, Qualitative Nature of some traditional crude drugs available in commercial markets of mumbai, maharashtra, India, *Ethnobotanical Leaflets*, 2008.
- Cuzzocrea S, Mazzon E, Dugo L, Serraino I, Paola RD, Britti D, Sarro DA, Pierpaoli S, Caputi AP, Masini E,



- Salvemini D, A role for superoxide in gentamicin-mediated nephropathy in rats, *European Journal of Pharmacology*, 450, 2002, 67-76.
29. Morin G, Viotte G, Vandewalle A, Hoof FV, Tulkens P, Fillastre JP, Gentamicin induced nephrotoxicity, A cell biology approach, *Kidney International*, 18, 1980, 583-590.
30. Weinberg JM, Humes HD, Mechanisms of gentamicin-induced dysfunction of renal cortical mitochondria, Effects on mitochondrial respiration, *Archives of Biochemistry and Biophysics*, 205, 1980, 222-231.
31. Nagi MN, Mansour MA, Protective effect of thymoquinone against doxorubicin-induced cardiotoxicity in rats, A possible mechanism of protection, *Pharmacological Research*, 41, 2000, 283-9.
32. Kopple JD, Ding H, Letoha A, L-Carnitine ameliorates gentamicin-induced renal injury in rats, *Nephrology Dialysis Transplantation*, 17, 2002, 2122-2131.
33. Ali BH, Gentamicin nephrotoxicity in humans and animals: some recent research. *General Pharmacology*, 26, 1995, 1477-1487.
34. Al-Majed AA, Mostafa AM, Al-Rikabi AC, Al-Shabanah OA, Protective effects of oral arabic gum administration on gentamicin induced nephrotoxicity in rats, *Pharmacological Research*, 46, 2002, 445–451.
35. Ali BH, Al-Wabel N, Mahmoud O, Mousa HM, Hashad M, Curcumin has a palliative action on gentamicin-induced nephrotoxicity in rats. *Fundamental Clinical Pharmacology*, 19, 2005, 473–477.
36. Reiter M, Rupp K, Baumeister P, Zieger S, Harreus U, Antioxidant effects of quercetin and coenzyme Q10 in mini organ cultures of human nasal mucosa cells, *Anticancer Research*, 29, 2009, 33-40.
37. Safa J, Argani H, Bastani B, Nezami N, Ardebili BR, Ghorbanhaghjo A, Kalagheichi H, Amirfirouzi A, Mesgari M, Rad JS, Protective effect of grape seed extract on gentamicin induced acute kidney injury, *Iranian Journal of Kidney Diseases*, 4, 2010, 285-291.
38. Gilbert DN, Wood CA, Kohlhepp SJ, Kohnen PW, Houghton DC, Finkbeiner HC, Polyaspartic acid prevents experimental aminoglycoside nephrotoxicity, *The Journal of Infectious Diseases*, 159(5), 1989, 945-953.
39. Annie S, Rajgopal PL, Malini S, Effect of *C.auriculata* root extract on cisplatin and gentamicin induced renal injury, *Phytomedicine*, (8), 2005, 555-60.
40. Friedman RB, Anderson RE, Entine SM, Hirshberg SB, Effects of diseases on clinical laboratory tests, *Clinical Chemistry*, 26, 1980, 476.
41. Nguyen HT, Transport proteins, In: Loeb WF, Quimby FW (Eds.), *The Clinical Chemistry of Laboratory Animals*, Second Edition, Taylor and Francis, Philadelphia, PA, USA, 1999, 309-335.
42. Kumar G, Banu SG, Vanitha PP, Sundararajan M, Rajasekara PM, Hepatoprotective activity of *Trianthema portulacastrum* L. against paracetamol and thioacetamide intoxication in albino rats, *Journal of Ethnopharmacology*, 92, 2004, 37–40.
43. Natarajan SK, Basivireddy J, Ramachandran A, Thomas S, Ramamoorthy P, Pulimood AB, Jacob M, Balasubramanian KA, Renal damage in experimentally-induced cirrhosis in rats, Role of oxygen free radicals, *Hepatology*, 43(6), 2006, 1248-56.
44. Abdel-Raheem IT, El-Sherbiny GA, Taye A, Green tea ameliorates renal oxidative damage induced by gentamicin in rats, *Pakistan Journal of Pharmaceutical Sciences*, 23, 2010, 21-28.
45. Jain A, Singhai AK, Effect of *Momordica dioica* Roxb on gentamicin model of acute renal failure, *Natural Product Research*, 20, 2010, 1379-1389.
46. Kappus H, *Oxidative stress* Academic Press, London, 1985, 273.
47. Haragushi H, Ishikawa H, Kubo I, Antioxidant action of diterpenoids from *Prodocarpas nagi*, *Planta Medica*, 63, 1997, 213-215.
48. Yazar E, Elmas M, Altunok V, Sivrikaya A, Oztekin E, Effects of aminoglycoside antibiotic on renal antioxidants, malondialdehyde levels and some biochemical parameters, *Canadian Journal of Veterinary Reserch*, 67, 2003, 239–240.
49. Anees A, Banday, Neelam F, Shubha P, Ahad NK, Yusufi, Farah K, Time dependent effects of gentamicin on the enzymes of carbohydrate metabolism, brush border membrane and oxidative stress in rat kidney tissues, 82, 2008, 450-459.
50. Hozayen W, Mouhamed B, Elshafeey H, Effects of Aqueous Purslane (*Portulaca Oleracea*) Extract and fish oil on gentamicin nephrotoxicity in albino rats, *Natural Science*, 9(2), 2011.
51. Walker PD, Barri Y, Shah SV, Oxidant mechanisms in gentamicin nephrotoxicity, *Renal Failure*, 21, 1999, 433–442.

Source of Support: Nil, Conflict of Interest: None.

