

Research Article



Hepatoprotective Effect of Sweet Fennel (*Foeniculum vulgare* L.) Methanol Extract against Carbon Tetrachloride Induced Liver Injury in Rats

Farouk K. El Baz, *Zeinab A. Salama, Hanaa H. Abdel Baky, Alaa A. Gaafar

Department of Plant Biochemistry, National Research Centre, El Behouth St., P.O. Box 12311, Dokki, Cairo, Egypt.

*Corresponding author's E-mail: dr.zeinabsalama70@gmail.com

Accepted on: 03-02-2014; Finalized on: 31-03-2014.

ABSTRACT

Liver is a vital organ play a major role in metabolism and excretion of xenobiotic from the body. Liver cell injury caused by various toxic chemicals (certain anti-biotic, chemotherapeutic agents, carbon tetrachloride (CCl₄), thioacetamide (TAA) etc.). The present study was carried to investigate the hepatoprotective effect of *Foeniculum vulgare* (FV); methanol extract of two cultivars of fennel. 100, 200 mg/kg BW of fennel extract and 100, 200 mg/kg silymarin (standard), were administrated to different groups of rat's prophylactic to CCl₄ administration. The levels of enzymes and non-enzymes liver damage biomarkers in serum of treated rats were compared to both toxicities and negative control groups and the histopathological examination were examined. The hepatotoxicity produced by CCl₄ administration was found to inhibit significantly $p \leq 0.05$ (dose dependently), using both 100 and 200 mg/kg BW of FV methanol extract could inhibit the CCl₄ induced acute hepatotoxicity by decreasing levels of serum aspartate amino transferase (AST), alanine amino transferase (ALT), alkaline phosphatase (ALP) and bilirubin. Fennel leaves extract prevents the development of chronic liver damage. From the histopathological examination, of the present work it could be concluded that silymarin at the two doses is the best treatment of liver intoxicated with CCl₄, followed by F1 and F2. Relieve of the pathological alteration is a dose dependent; as the intoxicated livers are restored to the normal hepatocytes form and function. Thus, the present results indicated that fennel possesses potent hepatoprotective capacity and may have potential therapeutic value in the treatment of liver disorders probably by its anti oxidative effects related to phytochemical constituents.

Keywords: CCl₄, *Foeniculum vulgare*, Hepatoprotective effect, Liver fibrosis.

INTRODUCTION

Liver is a vital organ play a major role in metabolism and excretion of xenobiotic from the body. Liver cell injury caused by various toxic chemicals (certain anti-biotic, chemotherapeutic agents, carbon tetrachloride (CCl₄), thioacetamide (TAA) etc.), Liver injury induced by toxins is more common nowadays. Herbal remedies are focused in the pharmaceutical industry to evolve a safe route for liver disorders.

Foeniculum vulgare Mill. (*Apiaceae* family) commonly known as fennel, is one of the widespread annual or perennial plants with aromatic odor. It was native to Southern Europe and Mediterranean region. The herb has many culinary and traditional medicine uses. Fennel has many biological activities due to its volatile and nonvolatile compounds. It is prescribed as an aromatic stomachic in TCM to treat various conditions, particularly rheumatism, cold pain and stomach. Fennel essential oil could inhibit the CCl₄ induced acute hepatotoxicity by decreasing levels of serum aspartate aminotransferase (AST), alanine aminotransferase (ALT), alkaline phosphatase (ALP) and bilirubin.

Herbal drug preparation, from numerous wild types are active for dyspeptic complains, bloating and flatulence.¹ Diuretic, analgesic and antipyretic and antioxidant activity has been found in the fennel fruits.² The most frequently investigated was the essential oil; which showed antioxidant, antimicrobial and hepatoprotective activity.³

Sweet fennel is still uncommon kind of vegetables and is one of the pronouncing new crops for pharmaceutical purposes, food industry as well as human consumption. Its blanched fleshy basal part (pseudo bulbs) is used for consumption.⁴ The leaves and fruits of sweet fennel are mainly used for flavor and cosmetics. Many herbs are well known to contain large amount of phenolics antioxidants other than well-known vitamin C, E and carotenoids. Phenolic antioxidants in herbs are mainly composed of phenolic acid⁵, flavonoids.⁶ Some phenolic compounds in herbs have the capacities to quench lipid peroxidation prevent DNA oxidative damage and scavenge oxygen species (ROS), such as superoxide hydrogen peroxide and hydrogen radicals.⁵ Little attention has paid to the effect of phenolics compounds extracted from fennel with hepatoprotective activity.

Therefore, the motivation of the present study was undertaken to investigate the hepatoprotective activity of methanol extract of fennel in carbon tetrachloride-induced hepatotoxic model in rats.

MATERIALS AND METHODS

Plant material

Extraction and preparation of plant sample

The edible part of sweet fennel (bulbs) was extracted by liquid nitrogen. Ten grams of frozen tissues were grounded in mortar with pestles using 100 ml of 80% methanol, soaked for 48 hour and then filtered.



Animals

In the present study Male albino rats of Wister strain weighting (155-180 g), were used. The animals were obtained from the Animal House Lab, National Research Centre, Dokki, Giza. The present study was approved by the Ethical Committee of the National Research Center (NRC), Egypt, which provided that the animals will not suffer at any stage of the experiment (Ethical approval No. 1033).

The rats were kept at a constant temperature (25 ± 2 °C), humidity (55 ± 5 %) and light-dark conditions (12/12 h dark / light cycle). The rats were fed with standard rodent basal diet and provided water ad libitum and had free access to water. Animals were given one week to get acclimatized with experiment conditions.

Experimental design

40 Animals were divided into eight groups of five animals each. Group I served as normal control group. Group II served as positive control group, where rats were administered 1ml CCl₄ in liquid paraffin (1:1). Groups III and IV treated prophylactic with silymarin (Zero, 100 and 200 mg/kg BW orally respectively) in the first day followed by 1 ml /kg BW CCl₄ in the second day and continued for 14 days. Groups V -VIII were administrated F1 and F2 extracts (100 and 200 mg/kg BW orally respectively) one dose /day, followed by (1 ml /kg BW) CCl₄ in the second day and continued for 14 days. At the end of the experiment, the animals of different groups were fasted for 12 h, weighted then blood samples were collected from the sublingual vein, then animals sacrificed using diethyl ether anesthesia and liver tissue was rapidly excised and accurately weighed. Blood samples were collected and allowed to clot and serum was separated. The liver was removed and used for biochemical and histopathological assessment.

Collection of serum/liver for estimation of biochemical parameters

Rats from all groups were sacrificed 48 h after CCl₄ administration. Blood was collected via the ocular vein and allowed to stand for 30 min before centrifuged at 3000 rpm for 15 min to collect the serum. Serum was separated for the estimation of the biochemical parameters.

Preparation of liver samples

The liver homogenate samples were prepared according to⁷. After collection of the blood samples, the rats were sacrificed and their livers were excised, rinsed in normal saline solution followed by cold 0.15 M Tris-HCl buffer (pH 7.4), then blotted dry and weighted. 10% (w/v) homogenate was prepared in 0.15 M Tris-HCl buffer with homogenizer and centrifuged at 1500 rpm for 15 min at 4 °C. The supernatant was used for the estimation of antioxidant biomarkers.

Biochemical parameters

Blood samples were collected without any anticoagulant and were allowed to clot for 10 minutes at room temperature. The blood was centrifuged at 2500 rpm for 20 minutes at room temperature. The obtained serum was stored at - 8 °C for the estimation of aspartate and alanine amino transferases (AST and ALT)⁸, alkaline phosphatase (ALP)⁹, lipid peroxidation as malondialdehyde (MDA)¹⁰, bilirubin¹¹, total protein¹², SOD¹³ and Glutathione-S-transferase (GST) activity was determined according to.¹⁴ These estimations were done according to the standard procedures given along with the kits.

Histopathological studies

Liver tissues were collected for histopathological analysis; a portion of the liver was fixed in 10% buffered formalin, processed using routine histology procedures, embedded in paraffin, cut in 5 micro mole sections and mounted on a slide. The samples were stained with hematoxylin and Eosin for histopathological examination according to.¹⁵

Statistics

Data and level of significance was set at ≤ 0.05 ($P \leq 0.05$). Data were statistically analyzed using Costat statistical package according to.¹⁶

RESULTS AND DISCUSSION

Effect of methanol extracts of sweet fennel supplementation on body and liver weights

From the results in Table 1, rats treated with CCl₄-only revealed significant decreases of body weight from 232.67 to 195.00 (-19 %) compared with negative control. The prophylactic supplementation with methanol extract of two sweet fennel cultivars (F1 and F2), showed significant improvement of body weight compared with CCl₄ rat group, where, the loss in weight was (11 and 12 %) at a dose 100 mg/kg BW and (5 and 6 %) at a dose 200 mg/kg BW respectively.

In addition, silymarin as reference drug demonstrated the best effect and did not showed a dramatic change in body weight especially at a dose 200 mg/kg BW compared to both CCl₄ treated and control groups.

The results of body weight were coincided with the results obtained for the liver weight, where, CCl₄ treated group gave a greater liver weight, as an evidence of an inflammation in the liver of this group. CCl₄-treated group exhibited significant raise in liver weight (81% increases) compared to normal group (Table 1). This liver weight increases was reversed with prophylactic administration of methanol extract of two fennel cultivars. The changes in body weights in the rats of the present study which were supported by biochemical serum enzyme markers such as (AST, ALT and ALP), lipid peroxidation as MDA and bilirubin (total, direct and indirect) and histopathological findings which are agreed with^{3,17} who reported that the hepatotoxicity produced by chronic CCl₄ administration was found to be inhibited by fennel essential oil with

evidence of decreased levels of serum GOT, GPT, ALP and bilirubin. Methanol extract of sweet fennel cultivars (F1 and F2) reduced the hepatomegaly, hence the rate of liver weight increase was reduced to 55% and 53% respectively at dose 100 mg/kg BW, and to 16% and 24% at dose 200 mg/kg BW respectively. Silymarin at both doses showed the best recovery and suppressed the enlargement of liver to a great extent which induced by CCl₄ treatment when compared to control.

Table 1: Effect of sweet fennel extracts supplementation on body weight (BW) and liver weight (LW) of rats

Groups	Body weight (g)	BW Decrease (-) %	Liver weight g/100g BW	LW Increases (+) %
Control	232.67 ^d ± 4.73	100	2.83 ^a ± 0.04	100
CCl ₄	195.00 ^a ± 3.00	81	5.12 ^e ± 0.16	181
S ₁₀₀	219.33 ^c ± 1.53	94	3.23 ^{bc} ± 0.16	114
F1 ₁₀₀	209.00 ^b ± 2.00	89	4.40 ^d ± 0.37	155
F2 ₁₀₀	208.67 ^b ± 2.08	88	4.33 ^d ± 0.16	153
S ₂₀₀	228.00 ^d ± 2.00	98	2.98 ^{ab} ± 0.05	105
F1 ₂₀₀	222.00 ^c ± 4.95	95	3.29 ^{bc} ± 0.21	116
F2 ₂₀₀	219.67 ^c ± 3.06	94	3.53 ^c ± 0.10	124
LSD at 0.05	5.95	-	0.30	-

All values are the means of three replicates and are significantly different at $p \geq 0.05 \pm$ standard deviation. Where: S100 = Silymarin at dose 100 mg /Kg BW, S200 = Silymarin at dose 200 mg /Kg BW, B1100 = Methanolic extract of Calabrese at dose 100 mg /Kg BW, B1200 = Methanolic extract of Calabrese at dose 200 mg /Kg BW, B2100 = Methanolic extract of Southern Star at dose 100 mg /Kg BW and B2200 = Methanolic extract of Southern Star at dose 200 mg /Kg BW.

Effect of methanolic extracts of sweet fennel supplementation on serum AST, ALT and ALP enzymes and other biochemical parameters in CCl₄ treated rats

The effect of methanol extracts of *Dolce* (F1) and *Zefa fino* (F2) cultivars at doses (100 and 200 mg/kg BW), compared to silymarin as reference agent at the same doses were evaluated for the hepatoprotective effect using hepatotoxicity induced by CCl₄ in rat model. The results are presented in Table 2.

In the CCl₄ intoxicated group, serum marker enzymes and biochemical parameters such as (AST, ALT and ALP), lipid peroxidation as MDA and bilirubin (total, direct and indirect) were significantly increased compared to control group. Total protein, SOD (as antioxidant enzymes) and GST (as detoxification enzyme) were significantly decreased in CCl₄ rat group compared to control group.

The activities of serum levels AST, ALT, ALP, MDA and bilirubin content were significantly reduced in the animal groups treated with the methanolic extracts of (F1 and F2) at doses (100 and 200 mg/kg BW) respectively. The activities of total protein, SOD and GST were significantly elevated in the groups pretreated with methanol extract of (F1 and F2) at both doses compared to CCl₄-treated group. Silymarin as reference drug exhibited the highest hepatoprotective levels using both doses.

Table 2 indicated significant increase in hepatoprotective effect with methanol extract of sweet fennel cultivars (F1 and F2) at doses 100 and 200 mg/kg BW. These results were supported by histological examination and^{3,17}, as they reported that the hepatotoxicity produced by chronic CCl₄ administration was found to be inhibited by fennel essential oil with evidence for decreased levels of serum GOT, GPT, ALP and bilirubin. Also, histopathological findings of the present study suggested that fennel extract prevents the development of chronic liver damage. The results of this study clearly indicated that fennel extract have a potent hepatoprotective action against CCl₄-induced liver fibrosis in rats.

It has been confirmed¹⁸ that the ethanolic extract of stems of *Calotropis gigantea* (*Asclepiadaceae*), showed the hepatoprotective activity with liver damage induced by CCl₄ in rats. The protective effect of *C. gigantea* extract was compared with the standard drug silymarin. The results revealed that the *C. gigantea* extract significantly decreased AST, ALT levels and lipid peroxide levels. The antioxidant parameters GSH, GPx, SOD and catalase levels were increased considerably as compared to their levels in untreated groups with *C. gigantea* extract.

The rise of the biomarker enzyme might be due to the release of these enzymes from the cytoplasm into the blood circulation rapidly after rupture of the membrane and cellular damage.¹⁹ High levels of AST indicate liver damage, such as that is due to viral as well as cardiac infarction and muscles injury. ALT catalysis the conversion of alanine to pyruvate and glutamate, and is released in a similar manner. Therefore, ALT level is more specific to the liver, and is thus considered a better parameter for detecting liver injury hepatitis.²⁰ This is clearly evidenced from the increase in liver MDA content after the administration of CCl₄ only. MDA level is used to determine early liver oxidative stress.²¹ Treatment of methanol extracts of sweet fennel reverses these changes. Hence it is likely that the mechanism of hepatoprotection of methanol extracts of sweet fennel is due to the inhibition of lipid peroxidation as well as to the enhancement of antioxidant and detoxification enzymes levels. The formation of lipid peroxides which in turn gives product such as malondialdehyde (MDA), that cause damage to the membranes. This lipid peroxidative degradation of biomolecules is one principle cause of hepatotoxicity of CCl₄.²²

Direct bilirubin concentrations was elevated in CCl₄ treated rats, indicated that either due to increased

production, decreased uptake by the liver, decreased conjugation, decreased secretion from the liver or blockage of bile ducts.²³ Increase in the level of unconjugated (indirect) bilirubin in the blood may result from a defect in the function of the liver to conjugate the bilirubin being produced damage. The significant reduction of unconjugated bilirubin level in the serum when CCl₄ was simultaneously administered with the tested extracts of sweet fennel as compared to the administration of CCl₄ alone might indicate that the conjugating function of the liver was improved due to that the extract of fennel increased the bile flow in rats

suggested stimulation of liver secretory capacity.²⁴ The results of the present study demonstrate that pretreatment of rats with fennel extract protects liver against CCl₄ -induced liver injury. Induced hepatotoxicity is in a dose dependent manner as detected by inhibition in serum ALT, AST, ALP.²⁵ It has been found that 100 mg/kg BW of, *morus bombycis* aqueous extract had significant hepatoprotective effect. Moreover, they found that both hepatoprotective and inhibition of oxidative stress in liver may be attributed to the flavonoids as antioxidants and prooxidants, depending on the concentration and free radical source.²⁶

Table 2: Influence of sweet fennel extracts supplementation on blood serum marker enzymes and biochemical parameter against CCl₄-treated rats

Groups	AST (U/ml)	ALT (U/ml)	ALP (IU/L)	MDA (μmol/ml)	Bilirubin			Total protein (g/dL)	SOD (U/ml)	GST (U/L)
					Total (mg/dL)	Direct (mg/dL)	Indirect (mg/dL)			
Control	44.27 ^a ± 0.91	43.76 ^a ± 0.39	75.79 ^a ± 0.59	8.39 ^a ± 0.11	0.45 ^a ± 0.08	0.20 ^a ± 0.04	0.25 ^a ± 0.04	6.00 ^f ± 0.06	2.29 ^{cde} ± 0.09	632.70 ^f ± 8.44
CCl ₄	146.14 ^f ± 0.80	141.42 ^d ± 0.90	178.91 ^d ± 1.21	18.57 ^g ± 0.36	2.17 ^c ± 0.09	0.87 ^d ± 0.09	1.30 ^d ± 0.18	3.97 ^a ± 0.05	1.27 ^a ± 0.08	395.55 ^a ± 9.88
S ₁₀₀	65.04 ^c ± 0.37	61.24 ^c ± 0.54	112.35 ^c ± 0.75	9.99 ^b ± 0.26	0.67 ^a ± 0.13	0.35 ^b ± 0.04	0.32 ^{ab} ± 0.11	5.18 ^d ± 0.11	2.33 ^{de} ± 0.07	576.46 ^d ± 8.44
F ₁₀₀	94.52 ^e ± 0.96	83.80 ^e ± 0.42	126.79 ^f ± 1.51	14.08 ^e ± 0.23	1.07 ^b ± 0.10	0.61 ^c ± 0.07	0.46 ^{abc} ± 0.04	4.72 ^c ± 0.03	2.04 ^b ± 0.10	497.72 ^b ± 5.62
F ₂₀₀	95.53 ^e ± 0.81	85.87 ^f ± 0.65	128.16 ^f ± 1.00	14.69 ^f ± 0.22	1.19 ^b ± 0.18	0.61 ^c ± 0.04	0.58 ^c ± 0.15	4.41 ^b ± 0.05	1.98 ^b ± 0.05	485.54 ^b ± 9.88
S ₂₀₀	62.77 ^b ± 0.92	58.85 ^b ± 0.54	92.10 ^b ± 0.69	8.81 ^a ± 0.28	0.59 ^a ± 0.08	0.30 ^{ab} ± 0.05	0.29 ^{ab} ± 0.05	5.85 ^e ± 0.07	2.47 ^e ± 0.10	606.45 ^e ± 7.08
F ₁₂₀₀	88.85 ^d ± 0.91	79.68 ^d ± 0.74	114.60 ^d ± 1.39	11.90 ^c ± 0.24	1.00 ^b ± 0.06	0.51 ^c ± 0.05	0.49 ^{bc} ± 0.01	5.20 ^d ± 0.13	2.18 ^{bcd} ± 0.10	523.97 ^c ± 8.59
F ₂₂₀₀	90.38 ^d ± 0.97	80.66 ^d ± 0.65	119.76 ^e ± 1.33	12.90 ^d ± 0.24	1.14 ^b ± 0.08	0.54 ^c ± 0.05	0.60 ^c ± 0.03	5.10 ^d ± 0.08	2.12 ^{bc} ± 0.08	529.59 ^c ± 7.08
LSD at 0.05	1.55	1.13	2.02	0.45	0.18	0.10	0.16	0.14	0.12	14.89

All values are the means of three replicates and are significantly different at $p \geq 0.05 \pm$ standard deviation. Where: S₁₀₀ = Silymarin at dose 100 mg /Kg BW, S₂₀₀ = Silymarin at dose 200 mg /Kg BW, F₁₀₀ =Methanolic extract of *Dolce* at dose 100 mg /Kg BW, F₂₀₀ =Methanolic extract of *Dolce* at dose 200 mg /Kg BW, F₁₀₀ = Methanolic extract of *Zefa fino* at dose 100 mg /Kg BW and F₂₀₀ =Methanolic extract of *Zefa fino* at dose 200 mg /Kg BW.

It has been suggested^{27,28} that fennel leaves extract may interfere with free radical formation which may conclude the hepatoprotective action.

Effect of methanol extracts of sweet fennel supplementation on antioxidant biomarkers of liver tissues

The assessment of lipid peroxidation as (MDA), superoxide dismutase (SOD), glutathione-S- transferase (GST) as a detoxification enzymes and total protein content as an evidence of liver cell regeneration were evaluated Table 3.

Rats treated with CCl₄ alone significantly reduced the concentration of total protein (from 4.26 to 3.11 g/dL), in the liver homogenates as compared to negative control group. Prophylactic administration of methanol extracts of F1 and F2 at doses 100 and 200 mg/kg BW significantly

raised the content of total protein as evidence of the restoration of liver.

MDA content in the liver tissue of CCl₄ treated rats, showed a significant elevation (20.37 μmol/g tissue), as compared to control (9.30 μmol/g tissue). Prophylactic administration of methanol extracts of F1 and F2 at doses 100 and 200 mg/kg BW reduced the MDA content in the liver cells from 20.37 to 15.07 and 16.11 μmol/g tissues respectively. Moreover, administration of extract at a dose of 200 mg/kg BW reduced MDA content in liver tissues (12.40 and 13.75 μmol /g tissue), for the same cultivars compared with rats administrated CCl₄ only (20.73 μmol /g tissue).

Silymarin treated rats, however (as a reference drug), exhibited the highest inhibition of MDA (11.77 and 10.24 μmol/g tissue), when compared with rats administered CCl₄ only. However the results of the present study indicate that the administration of methanol extracts of

F1 and F2 caused increase antioxidant enzymes activities compared to CCl₄ rat group. These results were found to be in accordance with the results reported by.²⁹ This is explained on the basis that malondialdehyde is a major reactive aldehyde that appears during the peroxidation of biological membrane polyunsaturated fatty acid.³⁰ Therefore, the hepatic content of MDA is already used as an indicator of liver tissue damage. In the present study, a significant increase in the MDA concentration indicates increased lipid peroxidation induced by CCl₄.

Table 3: Effect of sweet fennel extracts supplementation on total protein content and MDA, GST activities in the liver tissues of rats.

Groups	Total protein (g/dL)	MDA (μmol/g tissue)	SOD (U/g tissue)	GST (U/g tissue)
Control	4.26 ^{cd} ± 0.05	9.30 ^a ± 0.25	2.03 ^{bc} ± 0.08	5.84 ^e ± 0.05
CCl ₄	3.11 ^a ± 0.04	20.37 ^h ± 0.22	1.08 ^a ± 0.08	3.22 ^a ± 0.04
S ₁₀₀	4.02 ^b ± 0.04	11.77 ^c ± 0.21	2.19 ^{cd} ± 0.08	4.94 ^d ± 0.16
F1 ₁₀₀	4.37 ^{de} ± 0.05	15.07 ^f ± 0.27	1.96 ^b ± 0.08	3.92 ^b ± 0.13
F2 ₁₀₀	4.18 ^c ± 0.08	16.11 ^g ± 0.21	1.89 ^b ± 0.08	3.88 ^b ± 0.12
S ₂₀₀	4.24 ^{cd} ± 0.01	10.24 ^b ± 0.20	2.31 ^d ± 0.08	5.72 ^e ± 0.10
F1 ₂₀₀	4.43 ^e ± 0.06	12.40 ^d ± 0.22	2.06 ^{bc} ± 0.05	4.83 ^d ± 0.12
F2 ₂₀₀	4.28 ^{cd} ± 0.06	13.75 ^e ± 0.25	2.01 ^{bc} ± 0.07	4.32 ^c ± 0.13
LSD at 0.05	0.10	0.39	0.14	0.19

All values are the means of three replicates and are significantly different at $p \geq 0.05 \pm$ standard deviation. Where: S₁₀₀ = Silymarin at dose 100 mg /Kg BW, S₂₀₀ = Silymarin at dose 200 mg /Kg BW, F1₁₀₀ =Methanolic extract of *Dolce* at dose 100 mg /Kg BW, F1₂₀₀ =Methanolic extract of *Dolce* at dose 200 mg /Kg BW, F2₁₀₀ = Methanolic extract of *Zefa fino* at dose 100 mg /Kg BW and F2₂₀₀ =Methanolic extract of *Zefa fino* at dose 200 mg /Kg BW.

It was found that SOD activity of the liver total homogenate in CCl₄ treated group (1.08 U/g tissue) to be lower than that in normal group (2.03 U/g tissue) Table 3. The enzyme activity of SOD was increased to 1.96 and 1.89 U/g tissues by the administration of methanol extracts of F1 and F2 at a dose of 100 mg kg/kg BW and to 2.06 and 2.01 U/g tissues at dose of 200 mg/kg BW, respectively. Silymarin at the same doses have caused increasing the SOD levels values to 2.19 and 2.31 U/g tissues respectively. SOD and hepatic GST activities have been reported as the most important enzymes in the enzymatic antioxidant defense system. Methanol extract of fennel in the present study caused a significant increase in both hepatic SOD and GST. The inhibition of GST activity was observed in CCl₄ treated rats (3.22 U/g tissue), as compared to the normal control group (5.84

U/g tissue). Pretreatment of intoxicated rats with methanol extract of F1 and F2 enhanced GST activity significantly at a dose of 100 mg/kg BW (3.92 and 3.88 U/g tissue), and 200 mg/kg BW (4.83 and 4.32 mg/kg BW) respectively. Moreover, the hepatic GST activity increased remarkably was to be d (4.94 and 5.72 U/g tissues) due to treatment with silymarin at the same doses.

Histopathological evaluation

Histopathological evaluation revealed that, CCl₄ administration produced generally liver morphological changes and necrosis, severe centrilobular vacuolar degeneration and mononuclear cell aggregation as shown in Figure 2 in comparison to the normal liver morphology in Figure1. Pretreatment of rats with SF extract revealed moderate and apparently normal organ having very few hepatocytes with tiny cytoplasmic vacuoles (Figures 6 and 8). Thus, SF pretreatment greatly inhibited liver morphological changes and necrosis due to CCl₄ hepatotoxicity.

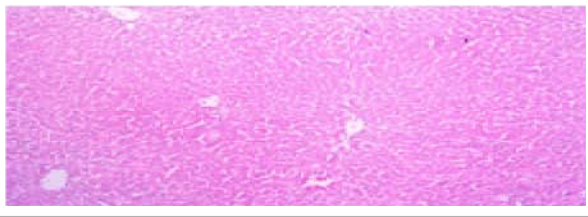
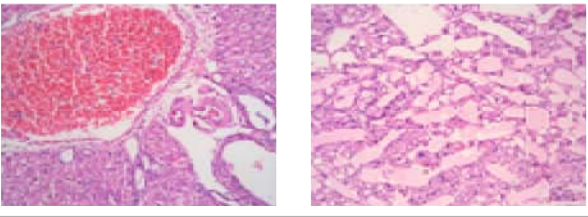
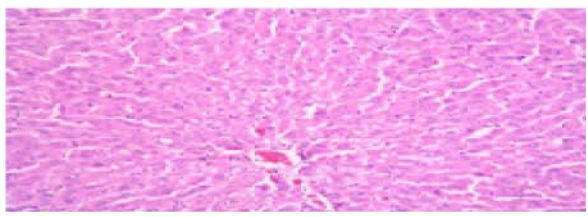
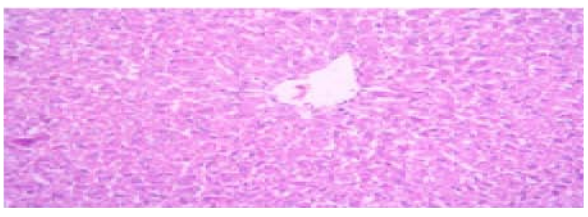
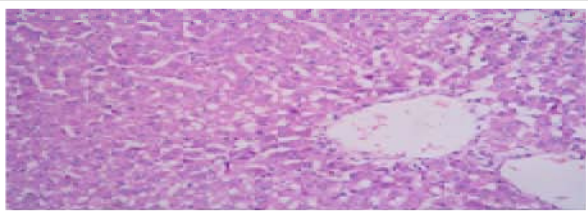
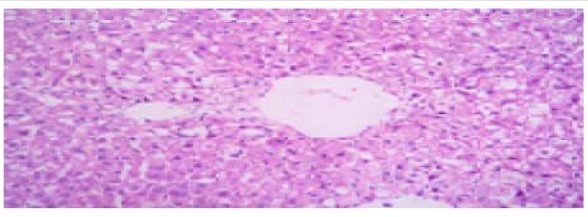
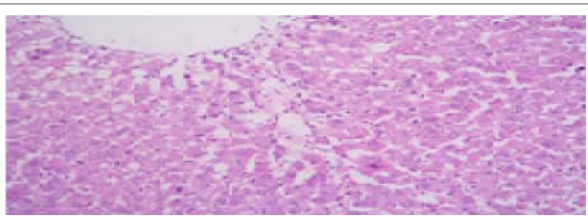
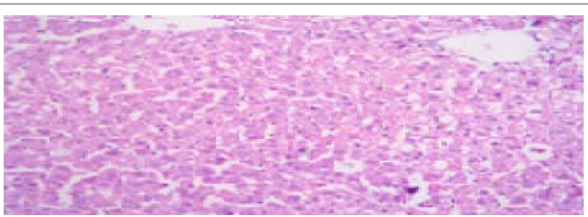
The histopathological examination revealed that the liver of rats which treated with CCl₄ showed severe congestion of blood vessels, edema, and necrosis of hepatocytes. Some cases showed severe vascular degenerative changes as well as mononuclear inflammatory cells infiltrations Figure 2.

Liver of rats administrated CCl₄ and treated with silymarin at a dose of 100 mg/kg BW, showed slight hepatocytes Figure 3. However, liver of rats treated by silymarin at dose 200 mg / kg body weight showed amelioration in hypatocytes appearance as well as less vascular degenerative changes which was detected Figure 4.

Prophylactic administration of intoxicated rats with F1 at 100 and 200 mg/kg BW decreased the pathological alteration and produced recovery in a dose dependent manner. Liver of rats treated with F1 at a dose of 100 mg/kg BW showed slight edema dispersed hepatocytes Figure 5. While, liver of rats treated with the dose of 200 mg/kg BW showed infiltration with mononuclear inflammatory cells around the blood vessels. Moreover, hepatocytes showed necrosis with slight edema Figure. 6. Similarly pathological alteration was noticed in intoxicated rats prophylactically administrated F2 at a dose of 100 and 200 mg/kg BW, where few vacuolar degenerative changes and slight edema were observed Figures 7and 8. It has been found Nan et al. (2003)³¹ that, CCl₄ causes necrosis, mono nuclear cell infiltration, steatosis foamy degeneration of hepatocytes. It was found also that *Ziziphus mauritiana* fruit extract protected the liver against CCl₄ induced liver morphological changes, fatty liver development and cellular degeneration. It is possible that the extract might have blocked adipogenesis. Similar results were obtained by³¹, who evaluated the hepatoprotective effect of turnip juice (*Brassica rapa* L.), at the doses of 8 and 16 ml/kg BW and compared with silymarin as a standard drug at the dose of 10 mg/ kg BW on CCl₄-induce hepatotoxicity.

The intoxicated rats treated with 8 and 16 ml/kg BW of turnip juice showed significant reduction of the elevated levels AST, ALT, ALP and bilirubin and the effect was increased with the elevation of dose (dose dependent relationship). The preliminary phytochemical screening showed the presence of flavonoids, anthocyanins and sulfur containing constituents in turnip juice. These compounds indicated that turnip juice administration prevents CCl₄-induced liver damage in rats, possibly through its antioxidants action. The same observation was noticed with (TFLA), which revealed hepatoprotective activity on CCl₄-induced hepatic injury in rats. Also, histopathological examinations showed that liver damage were improved when treated with total flavonoids of *Leggera alata* (TFLA). The major ingredients offered

significant protection against various liver microsomal activities and the hepatoprotective action of TFLA is likely related to its potent antioxidative and anti-inflammatory activities.³² It has been shown Lodhi et al. (2009)¹⁸ that the liver treated with CCl₄- showed massive fatty changes, gross necrosis; broad infiltration of lymphocytes; Kupffer cells around the central vein and loss of cellular boundaries. Histopathological observations of the rats liver pretreated with ethanol extract of *Calotropis gigantea* (*Asclepiadaceae*), and subsequently given CCl₄ showed a more or less normal architecture of the liver and reversed to a large extent the hepatic lesions produced by the toxin as comparable to the normal control and silymarin group.

	
<p>Figure 1. Normal liver with hepatic cord and central vein (H and E, X: 200).</p>	<p>Figure 2. Liver of rats administrated CCl₄ showing severe congestion of blood vessels in portal area, perivascular edema, the hepatocytes were suffering from vacuolar degenerative changes, and some hepatocytes were necrosis (H and E, X: 400).</p>
	
<p>Figure 3. Liver of rats treated with silymarin 100 mg/kg body weight after CCl₄ showing slight congestion of the hepatic vein with fewer cells suffered from vacuolar degenerative change (H and E, X: 200).</p>	<p>Figure 4. Liver of rats treated with silymarin 200 mg/kg body weight after CCl₄ showing few hepatocytes suffered from vacuolar degenerative changes (H and E, X: 200).</p>
	
<p>Figure 5. Liver of rats treated with F1 100 mg/kg body weight after CCl₄ showing focal areas of hepatocytes suffered from vacuolar degenerative changes with infiltration of mononuclear inflammatory cells (H and E, X: 200).</p>	<p>Figure 6. Liver of rats treated with F1 200 mg/kg body weight after CCl₄ showing large focal areas of hepatocytes suffered from vacuolar degenerative changes especially around the central vein (H and E, X: 400).</p>
	
<p>Figure 7. Liver of rats treated with F2 100 mg/kg body weight after CCl₄ showing focal areas of hepatocytes suffered from vacuolar degenerative changes with activation of Kupffer cells (H and E, X: 200).</p>	<p>Figure 8. Liver of rats treated with F2 200 mg/kg body weight after CCl₄ showing focal areas of hepatocytes suffered from vacuolar degenerative changes (H and E, X: 200).</p>

The histopathological findings of fennel essential oil were found to prevent the development of chronic liver damage.^{3,17}

Therefore, the result of the present study clearly indicates that fennel extract has a potent hepatoprotective action against CCl₄-induce liver fibrosis in rats.

CONCLUSION

The fennel has potential beneficial therapeutic actions. From the histopathological examination, of the present work it could be concluded that silymarin at the two doses is the best treatment of liver intoxicated with CCl₄, followed by F1 and F2. The relieve of the pathological alteration is a dose dependent; as the intoxicated livers are restored to the normal hepatocytes form and function. Thus, the present results indicated that fennel possesses potent hepatoprotective capacity and may have potential therapeutic value in the treatment of liver disorders probably by its anti oxidative effects related to phytochemical constituents.

REFERENCES

- Forster HB, Niklaus H, Lutz S, Antispasmodic effects of some medicinal plants, *Planta Med*, 40, 1980, 309-319.
- Oktay M, Gülcin I, Küfrevioğlu OI, Determination of *in-vitro* antioxidant activity of fennel (*Foeniculum vulgare*) seed extracts, *LWT*, 36, 2003, 263-271.
- Özbek H, Uğraş S, Dülger H, Bayram I, Tuncer I, Öztürk G, Öztürk A, Hepatoprotective effect of *Foeniculum vulgare* essential oil, *Fitoterapia*, 74, 2003, 317-319.
- El-Desuki M, Amer AH, Sawan MO, Khattab MA, Effect of irrigation and organic fertilization on the growth, bulb yield and quality of sweet fennel under Shark El-Owinat condition, *J Agric Sci Mans Univ.*, 26, 2001, 4465-4481.
- Cao YH, Cao RH, Angiogenesis inhibited by drinking tea, *Nature*, 398, 1999, 381.
- Madsen HL, Bertelesn G, Spices as antioxidants, *Trends Food Sci Technol*, 6, 1995, 271-277.
- Senthilkumar N, Badami S, Dongre SH, Bhojraj S, Antioxidant and hepatoprotective activity of the methanol extract of *Careya arborea* bark in Ehrlich ascites carcinoma-bearing mice, *J Nat med.*, 62, 2008, 336-339.
- Reitman S, Frankel A, Colorimetric method for the determination of serum glutamic oxaloacetic and glutamic pyruvic transaminase, *Am J Clin Pathol*, 28, 1957, 53-58.
- Belfield A, Goldberg DM, Revised assay for serum phenyl phosphatase activity using 4- amino-antipyrine, *Enzyme*, 12, 1971, 561-573.
- Ohkawa H, Ohishi W, Yagi K, Assay for lipid peroxides in animal tissue by thiobarbituric acid reaction, *Anal Biochem*, 95, 1979, 351-358.
- Walter M, Gerade H, A colorimetric method for determination of total bilirubin, *Microchem J*, 15, 1970, 231-236.
- Gornal AC, Bardawill CJ, David MM, Determination of serum proteins by means of the biuret reaction, *J Biol Chem.*, 177, 1949, 751-766.
- Nishikimi M, Roa NA, Yogi K, The occurrence of superoxide anion in the reaction of reduced phenazine mehosulphate and molecular oxygen, *Biochem Biophys Res Commun.*, 46, 1972, 849-854.
- Habig WH, Pabst MJ, Jakoby WB, Glutathion-S-transferase: the first enzymatic step in mercapturic acid formation, *J Biol Chem.*, 249, 1974, 7130-7139.
- Bancraft JD, Stevens A, Turner DR, Theory and Practice of Histological Techniques, Churchill Livingstone, New York, 4th Ed, 1996, 309-339.
- Snedecore WC, Cochran WG, Statistical methods, The Iowa State Univ. Press, 7th Ed, 1980, Ames, Iowa, USA.
- Özbek H, Uğraş S, Bayram I, Uygan I, Erdoğan E, Öztürk A, Huyut Z, Hepatoprotective effect of *Foeniculum vulgare* essential oil: A carbon-tetrachloride induced liver fibrosis model in rats, *Scand J Lab Ani Sci.*, 31, 2004, 9-17.
- Lodhi G, Singh HK, Pant KK, Hussain Z, Hepatoprotective effects of *Calotropis gigantea* extract against carbon tetrachloride induced liver injury in rats, *Acta Pharmaceutica*, 59, 2009, 89-96.
- Sallie R, Tredger JM, Williams R, Drugs and the liver, *Biopharm Drug Dispos*, 12, 1991, 251-259.
- Gupta M, Mazumdar UI, Kumar TS, Gomathi P, Kumar RS, Antioxidant and hepatoprotective effects of *Bauhinia racemosa* against paracetamol and carbon tetrachloride induced liver damage in rats, *Iranian J Pharmacol Therapeutics (IJPT)*, 3, 2004, 12-20.
- Tokyay R, Kaya E, Gur ES, Tuncel P, Ozbek R, Oztuk E, Prostaglandin synthetase Inhibition reduces peritonitis induced early liver oxidant stress, *Surg Today*, 29, 1999, 42-46.
- Cotran RS, Kumar V, Robbins SL, Cell injury and cellular diseases, Prism Book. Pub. Ltd., 5th edition, 1994, 379-430.
- Bun SS, Bun H, Guedon C, Rosier C, Ollivier E, Effect of green tea extracts on liver functions in wistar rats, *Food Chem Toxicol.*, 44, 2006, 1108-1113.
- Rafatullah S, Al-Yahya M, Mossa J, Galal A, El-Tahir K, Preliminary phytochemical and hepatoprotective studies on Turinp *Brassica rapa* L, *Int J of Pharmacol.*, 2, 2006, 670-673.
- Guti'errez RMP, Solis RV, Hepatoprotective and inhibition of oxidative stress in liver of Prosteche amichuacana, *Rec. Nat. Prod.*, 3, 2009, 46-51.
- Gupta M, Mazumdar UI, Kumar TS, Gomathi P, Kumar RS, Antioxidant and hepatoprotective effects of *Bauhinia racemosa* against paracetamol and carbon tetrachloride induced liver damage in rats, *Iranian J Pharmacol Therapeutics (IJPT)*, 3, 2004, 12-20.
- Gupta AK, Chitme H, Dass SK, Misra N, Antioxidant activity of Chamomile recutita capitula methanolic extracts against CCl₄-induced liver injury in rats, *J Pharmacol Toxicol.*, 1(6), 2006, 101-107.
- Sanaa Ali, Maha Rizk, Nabawia Ibrahim, Mohga Abdallah, Hayat Sharara, Magda Moustafa, Protective role of *Junipe phoenicea* and *Cupressus sempervirens* against CCl₄, *World J Gastrointest Pharmacol Ther.*, 6, 2010, 123-131.



29. Vaca CE, Wilhelm J, Harms-Ringdahl M, Interaction of lipid peroxidation products with DNA. A Review, Mutat. Res., 195, 1988, 137–149.
30. Nan JX, Jiang YZ, Park EJ, Ko G, Kim YC, Sohn DH, Protective effect of *Rhodiola sachalinensis* extract on carbon tetrachloride induced liver injury in rats, J. Ethnopharmacol., 84, 2003, 143-148.
31. Wu Y, Wang F, Zheng Q, Lu L, Yao H, Zhou C, Wu X, Zhao Y, Hepatoprotective effect of total flavonoids from *Laggera alata* against carbon tetrachloride-induced injury in primary cultured neonatal rat hepatocytes and in rats with hepatic damage, J Biomed Sci., 13, 2006, 569-578.

Source of Support: Nil, **Conflict of Interest:** None.

