



Factor V Leiden Mutation – A Rare Case of Young Stroke

¹Dr. B. Shanthi, Dr. T. Rajini Samuel^{2*}, Dr. Manjula Devi³

¹Professor of Biochemistry, Sree Balaji Medical College and Hospitals, Chromepet, Chennai, India.

²Dr. T. Rajini Samuel, Final Year Postgraduate in Biochemistry, Sree Balaji Medical College and Hospitals, Chromepet, Chennai, India.

³Dr. Manjula Devi Professor and HOD, Department of Biochemistry, Sree Balaji Medical College and Hospitals, Chromepet, Chennai, India.

*Corresponding author's E-mail: Samuel.biochemistry@gmail.com

Accepted on: 28-10-2014; Finalized on: 31-12-2014.

ABSTRACT

Factor v leiden thrombophilia is a genetically inherited disorder of blood clotting. Factor v leiden is a variant (mutated form) of human factor v that causes an increase in blood clotting. In this disorder, the leiden variant (form) of factor v cannot be inactivated (switched off) by activated protein c, and so clotting is encouraged. Here we present a case report of a 23 year male patient who was admitted on 8th June 2014 in Sree Balaji Medical college and hospital with the complaints of two episodes of generalized tonic clonic seizures as noticed by attenders that morning. Patient had no significant past history and family history. Patient was examined thoroughly and detailed investigation was done to find out the cause for young stroke and seizure disorder. His ct scan-brain revealed a case of dural venous and cortical venous thrombosis. He had highly elevated aPTT with slightly increased PT. Then tests for bleeding and clotting disorders are done which revealed he had decreased anti-thrombin and factor v leiden homozygous mutant detected. The condition is less common in latin americans and african-americans and is extremely rare in people of asian descent.

Keywords: Leiden Mutation, Hypercoagulability, Seizure Disorder, PCR

INTRODUCTION

Here we present a case report of 23 year male patient who was admitted on 8th June 2014 in Sree Balaji Medical college and hospital, Chromepet, Chennai with the complaints of two episodes of generalized tonic clonic seizures (GTCS) as noticed by his parents and relatives on that morning. He had jerky movements of the right side upper limb and lower limb associated with tingling sensation in right upper limb and not associated with loss of consciousness, ear discharge, headache, vomiting, visual defect, giddiness. He had weakness of the right upper limb with numbness of the hand. Patient had no significant past history and family history. Patient was examined thoroughly and detailed investigation was done to find out the cause for young stroke and seizure disorder. His muscle tone and bulk is normal in both the upper and lower limbs. His muscle power is 3/5 in right upper limb and 4/5 in right lower limb and it is 5/5 in other limbs. His ct scan-brain revealed a case of dural venous and cortical venous thrombosis.

He was treated with injection fosolin infusion 150 mg in normal saline infusion and injection heparin infusion was started. Initially 5000 units of heparin was given followed by maintenance dose of 1000 units per hour based on the measurement of aPTT values. All his initial lab investigations are almost normal except some with decreased magnesium (1.69, normal is 1.7 to 2.55 mg/dl) and he had highly elevated aPTT with slightly increased PT.

Then tests for bleeding and clotting disorders are done which revealed he had normal protein c activity, normal

protein s activity, normal homocysteine levels, negative for both phospholipid ab igm and phospholipid ab igg, lupus anticoagulant not detected, but with decreased anti-thrombin (66% normal (80 to 120 %) and factor v leiden homozygous mutant detected.

MATERIALS AND METHODS

Investigations - Ct – Brain

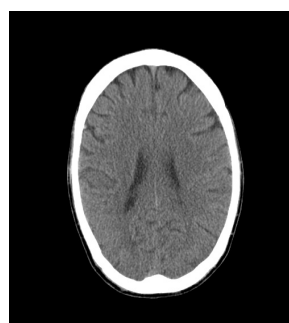


Figure 1: CT scan Picture 1 of patient

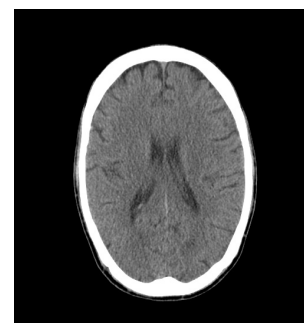


Figure 2: CT scan Picture 2 of patient

- Sulcal and Gyral pattern appears Normal.
- Grey and White matter differentiation Maintained.
- Subtle Hypodense Lesion measuring 2.8 X 2.1 cm noted In Left frontal sub cortical white matter (Pre central region).
- Mid portion of the superior Sagittal Sinus appears hyperdense. Few cortical veins in the Bilateral Frontal and Left Parietal region appear hyperdense.
- Basal Ganglia and Thalami appear Normal.

- Brain Stem and Cerebellum appear Normal.
- Ventricles and Cisterns appear Normal. No Evidence of Midline Shift seen.
- Sellar, Suprasellar and Parasellar regions appear Normal.
- No Evidence of Abnormal Extradural/Subdural collections seen.

Hematology	
Wbc	8,900
Neut	90%
Lymph	10%
ESR:1/2	02 mm
1 Hr	04 mm
Hb	15.5 g/dl
RBC	4.68 Million / mm ³
PCV	47%
Platelet	1.56 Lakh/mm ³
MCV	101 Ft (80 To 95 Ft)
MCH	33 Pg (27 To 32 Pg)
MCHC	32 % (32 To 38 %)
Peripheral Smear	Normocytic, Normochromic, No Hemoparasites, No Immature Cells
Platelets	Normal In Number And Distribution And Adequate
Biochemistry	
RBS	75 mg/dl
Urea	20 mg/dl
Creatinine	0.8 mg /dl
Calcium	8.6 mg/dl
Phosphorus	3.0 mg/dl
Magnesium	1.69 (1.7 To 2.55 mg/dl)
Serum Electrolytes	
Sodium:	135.8 Meq/L
Potassium:	3.59 Meq/L
Chloride:	106.2 Meq/L
Liver Function Test	
Total Bilirubin	1.1 mg/dl
Direct Bilirubin	0.4 mg/dl
Indirect Bilirubin	0.7 mg/dl
Total Protein	6.9 g/dl
Albumin	3.7 g/dl
Globulin	3.2 g/dl
A/G	1.2
SGOT	47 IU/L
SGPT	15 IU/L
ALP	53 IU/L
GGT	35 IU/L
Urine Routine	
Protein	Nil
Sugar	Nil

Rbc	Nil
Pus	6 To 8
Epithelial Cells	3-4
Casts And Crystals	Nil
Serology	
Hiv 1 And 2 With P24 Antigen	Negative
Hbs Ag (Australia Antigen)	Negative
Anti-Hcv	Negative
RPR	
Tests For Bleeding/Clotting Disorders	(Non-Responsive)
Protein C-Activity	
108 % (Normal 70 to 130 %)	
Protein S-Activity	
119% (Males: 93.5 to 126.5, Females: 72 to 116%)	
Anti-Thrombin	
60 % (Normal 80 To 20 %)	
Factor V Leiden	
(homozygous mutant detected)	
Factor v leiden detecting and genotyping of a single point mutation G to A at Position 1691 of the human factor v gene, known as factor v leiden mutation .The test was performed on the light cycler 2.0 instrument with real time PCR for the Amplification and fluorogenic target-specific hybridization for the detection and Genotyping of the amplified factor V DNA.	
Lupus Anticoagulant	
La1 (Screen)	36.4 Sec
Control	37.8 Sec
Ratio	0.96
Lupus Anticoagulant	(Not Detected)
Normal Males: (5.46 to 16.20) Females: (4.74 to 13.56)	
Phospholipid Ab Ig M	
Normal (Less Than 12.0 – Negative, 12-18 – Equivocal, More Than 18 – Positive)	
Phospholipid Ab Ig G	
Normal (Less Than 12.0 – Negative, 12-18 – Equivocal, More Than 18 – Positive)	

Prothrombin Time and International Normalized Ratio

Date June 2014	PT	INR	aPTT
9 th	Test: 21.6 control: 13.0	2.25	
10 th	Test: 15.1 control: 13.0	1.27	Test: 75.7 Control: 30.0
14 th	Test : 18.0 control: 13.0	1.47	Test: 127.4 Control: 30.0
17 th	Test: 63.1 control: 13.0	12.5	



DISCUSSION

Factor v leiden is an autosomal dominant genetic condition that exhibits incomplete dominance i.e. many people carrying the mutation do not suffer any consequences. The condition results in a factor v variant that cannot be as easily degraded by APC (activated protein c).

The gene that codes the protein is referred to as F5. Mutation of this gene—a single nucleotide polymorphism (SNP) is located in exon 10. As a missense substitution it changes a proteins amino acid from arginine to glutamine depending on the chosen start the position of the nucleotide variant is either at position 1691 or 1746. It also affects the amino acid position for the variant, which is either 506 or 534. Since this amino acid is normally the cleavage site for APC, the mutation prevents efficient inactivation of factor v.

When factor v remains active, it facilitates overproduction of thrombin leading to generation of excess fibrin and excess clotting. In the normal person, factor v functions as cofactor to allow factor xa, to activate an enzyme called thrombin. Thrombin in turn cleaves fibrinogen to form fibrin, which polymerizes to form the dense meshwork that makes up the majority of a clot. Activated protein c (APC) is a natural anticoagulant that acts to limit the extent of clotting by cleaving and degrading factor v.

Studies have found that about 5 percent of Caucasians in North America have factor v leiden. The condition is less common in Latin Americans and African-Americans and is extremely rare in people of Asian descent.

The excessive clotting that occurs in factor v leiden thrombophilia is almost always restricted to the veins, where the clotting may cause a deep vein thrombosis (DVT).⁶⁻⁸ If the venous clots break off, these clots can travel through the right side of the heart to the lung where they block a pulmonary blood vessel and cause a pulmonary embolism. It is extremely rare for this disorder to cause the formation of clots in arteries that can lead to stroke or heart attack, though a "mini-stroke", known as a transient ischemic attack, is more common. Given that this disease displays incomplete dominance, those who are homozygous for the mutated allele are at a heightened risk for the events detailed above versus those that are heterozygous for the mutation.

Up to 30 percent of patients who present with deep vein thrombosis (DVT) or pulmonary embolism have this condition.^{1,2,5} The risk of developing a clot in a blood vessel depends on whether a person inherits one or two copies of the factor v leiden mutation. Inheriting one copy of the mutation from a parent (heterozygous) increases by fourfold to eightfold the chance of developing a clot.

People who inherit two copies of the mutation

(homozygous), one from each parent, may have up to 80 times the usual risk of developing this type of blood clot. Considering that the risk of developing an abnormal blood clot averages about 1 in 1,000 per year in the general population, the presence of one copy of the factor v leiden mutation increases that risk to between 4 in 1,000 to 8 in 1,000.

Having two copies of the mutation may raise the risk as high as 80 in 1,000. It is unclear whether these individuals are at increased risk for recurrent venous thrombosis. While only 1 percent of people with factor v leiden have two copies of the defective gene, these homozygous individuals have a more severe clinical condition.^{10,11}

The presence of acquired risk factors for venous thrombosis including smoking, use of estrogen-containing (combined) forms of hormonal contraception, and recent surgery—further increase the chance that an individual with the factor v leiden mutation will develop DVT.⁷⁻⁹

Women with factor v leiden have a substantially increased risk of clotting in pregnancy (and on estrogen - containing birth control pills or hormone replacement) in the form of deep vein thrombosis and pulmonary embolism.⁵⁻⁸ They also may have a small increased risk of preeclampsia, may have a small increased risk of low birth weight babies, may have a small increased risk of miscarriage and still birth due to either clotting in the placenta, umbilical cord, or the fetus (fetal clotting may depend on whether the baby has inherited the gene) or influences the clotting system may have on placental development. Note that many of these women go through one or more pregnancies with no difficulties, while others may repeatedly have pregnancy complications, and still others may develop clots within weeks of becoming pregnant.¹²

CONCLUSION

Suspicion of factor v leiden being the cause for any thrombotic event should be considered in any Caucasian patient below the age of 45, or in any person with a family history of venous thrombosis. There are a few different methods by which this condition can be diagnosed.^{3,4} There is also a genetic test that can be done for this disorder. Here we diagnosed this patient based on a genetic test with real time PCR done in hi-tech laboratories. We presented this case since factor v leiden mutation is extremely rare in Asian descent and is a rare cause for stroke in young individuals.

REFERENCES

1. Folsom A, Cushman M, Tsai M. A Prospective Study of Venous Thromboembolism in relation to factor V Leiden and related factors. *Blood*. 99, 2002, 2720–2725.
2. Goldhaber S, Morrison R. Pulmonary Embolism and Deep Vein Thrombosis. *Circulation*. 106, 2002, 1436–1438.
3. Goldhaber S, Grasso-Correnti N. Treatment of Blood Clots. *Circulation*. 106, 2002, E138–E140.



4. Green D. Genetic Hypercoagulability: Screening should be an Informed Choice. *Blood*. 98, 2001, 20.
5. Herrington D, Vittinghoff E, Howard T. Factor V Leiden, Hormone Replacement Therapy and the Risk of Venous Thromboembolic events In Women with Coronary Disease. *Arterioscler Thromb Vasc Biol*. 22, 2002, 1012–1017.
6. Rosendaal F. Venous Thrombosis: A Multicausal Disease. *Lancet*. 353, 1999, 1167–1173.
7. Rosendaal F, Vessey M, Rumley A. Hormonal Replacement Therapy, Prothrombotic Mutations and the Risk of Venous Thrombosis. *Br J Haematol*. 116, 2002, 851–854.
8. Tsai A, Cushman M, Rosamond W. Cardiovascular Risk Factors and Venous Thromboembolism Incidence. *Arch Intern Med*. 162, 2002, 1182–1189.
9. Press R, Bauer K, Kujovic J. Clinical Utility of Factor V Leiden (R506q) for the Diagnosis and Management of Thromboembolic Disorders. *Arch Pathol Lab Med*. 126, 2002, 1304–1318.
10. De Stefano V, Leone G. Resistance to Activated Protein C due to Mutated factor V As a Novel Cause of Inherited Thrombophilia" *Haematologica*, 80(4), 1995, 344–356.
11. Bertina Rm, Koeleman Bp, Koster T. "Mutation in Blood Coagulation Factor V Associated with Resistance to Activated Protein C". *Nature*, 369(6475), 1994, 64–67.
12. Rodger Ma, Paidas M, Mclintock C. "Inherited Thrombophilia and Pregnancy Complications Revisited". *Obstetrics and Gynaecology* 112(2 Pt 1), 2008, 320–324.

Source of Support: Nil, **Conflict of Interest:** None.

