



A Fast and Reliable Method for Early Detection of Glaucoma

T.R.Ganesh Babu¹, R.Sathishkumar², S.Padmavathi³, Rengaraj Venkatesh⁴

^{1,3} Electronics and Communication, Shri Andal Alagar College of Engineering, India.

² Electronics and Communication, Sri Venkateswara College of Engineering, India.

⁴ Chief Medical Officer, Aravind Eye Hospital, India.

*Corresponding author's E-mail: vrsthishkumar07@gmail.com

Accepted on: 30-11-2014; Finalized on: 31-12-2014.

ABSTRACT

Glaucoma is a serious ocular disease and leads to blindness if it is not detected and treated. Hence, it is important to develop various detection techniques to assist clinicians to diagnose at early stage. In this paper, we propose methods for an automatic CDR determination. The optic disc region is segmented by using active contour model and optic cup is segmented by using fuzzy c mean clustering. The segmented contour of optic disc and optic cup has been smoothed by circular fitting and CDR is calculated for 50 normal images and 100 fundus images. The ISNT (Inferior Superior Nasal Temporal) ratios for the neuro retinal rim area and the blood vessels in the optic disc region are considered. The blood vessels are segmented by morphological method and the neuro retinal rim (NRR) is the area between the optic disc and optic cup. For these two features, values of ISNT ratio are computed. The features namely CDR, ISNT ratio for blood vessels NRR area and texture features are used for classifying by Support Vector Machine (SVM). The results show sensitivity, specificity and accuracy of SVM classifier as 96%, 93.33% and 95.38% respectively.

Keywords: Glaucoma, Image texture, Feature extraction, ISNT, SVM.

INTRODUCTION

Glaucoma is a general term for a family of eye diseases, which, in most cases, leads to increased pressure within the eye and as a result, damages the optic nerve. It affects people of all ages and initially marginal vision is lost. If proper treatment is not taken the vision loss will continue that leads to total blindness. A watery material called aqueous humor is produced by the ciliary body and is drained through the Canal of Schlemm. If the aqueous humor does not drain out correctly, then pressure will build up in the eye. The optic nerve head is the location connecting the optic nerve and retina. The optic nerve head consists of an optic disc, cup and neuro retinal rim (NRR). The optic cup is the excavation of nerve fibers in the center, and the NRR is formed by nerve fibers and glial cells. Glaucomatous changes in the optic nerve head are related to decreased number of the nerve fibers. While the size of the optic cup increases, the NRR decreases. The ratio of the area of the optic cup to disc, that is cup to disc ratio (CDR) and neuroretinal rim surface are important structural indicators for assessing the presence of glaucoma.

Prior works

A variation level set method to automatically extract the optic disc with the 97% accuracy in the determined CDR results and 18% improvement over the color intensity method has been produced¹. A level set segmentation, convex hull and ellipse fitting boundary smoothing has been achieved with the accuracy of optic cup boundary of 97.2% in their experimental results². The level set methods for segmenting the optic cup and optic disc from retinal images, to determine the CDR with SVM having a

greater consistency over the NN, suggesting potential for SVM as a viable option³. An automatic optic disc parameterization technique based on segmented optic disc and cup regions obtained from monocular retinal images with the estimated error of the vertical cup-to-disc diameter ratio is 0.09/0.08 (mean/standard deviation) while for cup-to-disc area ratio is 0.12/0.10 also has been achieved⁴. The active contour method is also used to determine the CDR from the color fundus images to determine pathological process of glaucoma with improved preprocessing steps⁵. An automated method for analyzing the optic disc, optic cup and measuring the CDR on stereo retinal fundus images is obtained for classification of the glaucomatous and non-glaucomatous eyes⁶. A method to measure the CDR using a vertical profile on the optic disc is also presented⁷. An optic disc and optic cup segmentation using super pixel classification for glaucoma screening results show an average overlapping error of 9.5% and 24.1% in optic disc and optic cup segmentation respectively⁸.

DETECTION SYSTEM [METHODOLOGY-I]

Automated detection of glaucoma system is shown in Figure 1 as a block diagram. It begins with the identification of maximum brightest pixel point as centre. The image is then analyzed in terms of red, green and blue planes in order to segment the optic disc and cup. Optic disc segmentation is carried out in the red plane and cup is in the green plane. The optic disc is also the entry point for the major blood vessels that supply the retina. The optic disc is placed 3 to 4 mm to the nasal side of the fovea. It is vertically oval, with average dimensions of 1.76mm horizontally by 1.92mm vertically. There is a central depression in the optic disc of variable size called



the optic cup. During glaucomatous progression, the death of the ganglion nerve cells leads to increased excavation of the optic cup, and a corresponding increase in the CDR. The CDR is thus a vital indicator of glaucomatous neuropathy. The normal cup to disc ratio range is from 0.1 to 0.3. If the cup to disc ratio exceeds 0.3 then it indicates the abnormal condition that is, the presence of glaucoma. Figure 2 (a) shows the OD boundary detected and Figure 2(b) shows the OD segmented image. The centroid is found and the optic disc boundary is smoothed by circle fitting using least squares method and the radius is found accordingly.

Figure 2(d) and 2 (e) shows the overlapped image and circle fitted image. In this work fuzzy C-mean Clustering (FCM) is applied for optic cup segmentation and is a data clustering technique in which a dataset is grouped into n clusters with every data point in the dataset belonging to every cluster to a certain degree. It takes a data set and a desired number of clusters and returns optimal cluster centers and membership grades for each data point. The number of clusters selected is three, which contains optic disc, optic cup and background area. The Algorithm steps are given below:

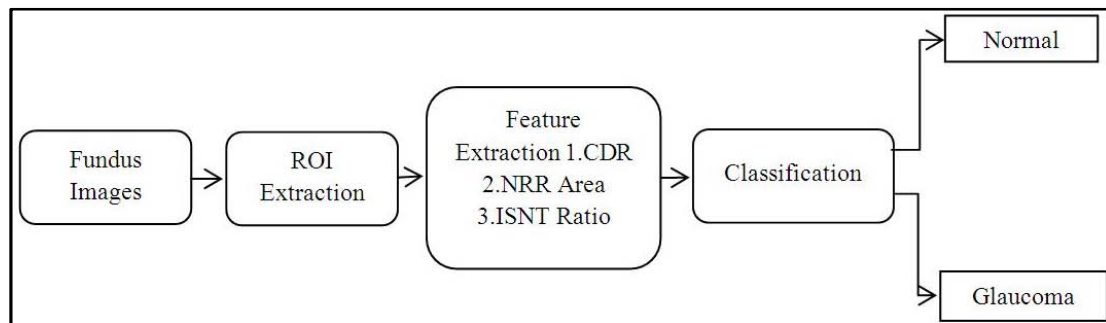


Figure 1: Block diagram




Figure 2: Result of Images a) OD boundary b) Segmented c) OD centroid d) Overlapped e) Circle fitted

Step 1: Choose the no of clusters as three (optic disc, optic cup and background)

Step 2: Initialize the Fuzzy Partition matrix and calculate the cluster centers for each step which is given in equation 1

$$c_j = \frac{\sum_{i=1}^N u_{ij}^m \cdot x_i}{\sum_{i=1}^N u_{ij}^m} \quad (1)$$

Where m is any real number greater than 1, u_{ij} is the degree of membership of x_i in the cluster j , x_i is the i th of d -dimensional measured data, c_j is the d -dimension center of the cluster.

Step 3: In each step of the iteration, the cluster centers and the membership grade point are updated and the objective function is minimized to find the best location for the clusters. The membership grade function is

$$u_{ij} = \frac{1}{\sum_{k=1}^c \left(\frac{\|x_i - c_j\|}{\|x_i - c_k\|} \right)^{\frac{2}{m-1}}} \quad (2)$$

The objective function

$$J_m = \sum_{i=1}^N \sum_{j=1}^c u_{ij}^m \|x_i - c_j\|^2 \quad 1 \leq m < \infty \quad (3)$$

Where $\|*\|$ is a norm expressing the similarity between any measured data and the center.

Step 4: Stop the process when the maximum number of iterations is reached, or when the objective function improvement between two consecutive iterations is less than the minimum amount of improvement specified.

Step 5: In the optic cup segmented image, maximum diameter is found and a circle is fitted to find the optic

cup area and radius accordingly. The optic cup segmented using Fuzzy c-mean clustering is shown in Figure 3 (a,b,c). In the optic cup detected image, maximum diameter is found and a circle is fitted to obtain the optic cup radius and the optic cup area is found accordingly. The superimposed image and the circle fitted image are shown in Figure 3 (d) and (e).

Neuro Retinal Rim (NRR) area

A measurement of CDR alone is insufficient and may be misleading as small discs will have smaller cups and hence a smaller CDR. The retinal nerve fibre are spread unevenly across the surface of the retina in a thin layer which has a ‘feathery’ appearance, best seen immediately above and below the disc. As the nerve fibres converge on the edge of the disc they pour over the scleral ring (which marks

the edge of the disc) and then down its inner surface. This dense packing of nerve fibres just inside the scleral ring is visualized as the NRR which indirectly indicates the presence and progression of glaucomatous damage. NRR is calculated by subtracting the area of the optic cup from area of optic disc. The resulting image is then converted in to binary image. The NRR is found by counting the number of white pixels in the binary image obtained. The resulting image is shown in Figure 4 (a). It is converted in to a binary image and the area is calculated by counting the number of white pixels obtained. It is shown in Figure 4 (b). The result shows that Neuro-Retinal Rim area values for the set of normal images range from 4809 pixels to 7193 pixels and for abnormal images the range is from 2944 to 4689 pixels.

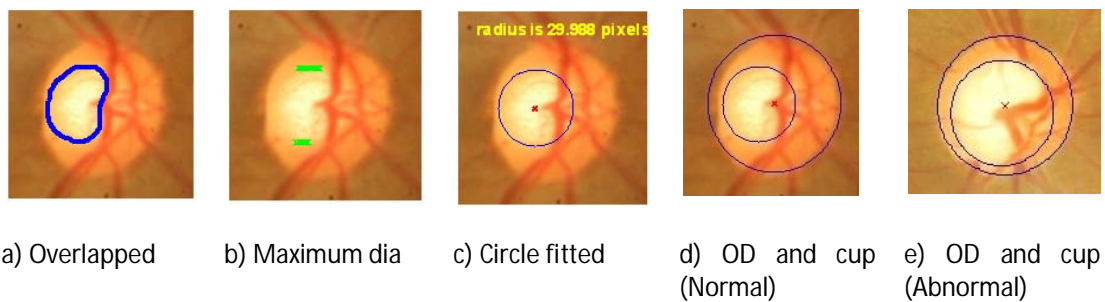


Figure 3: Result of Images a) Overlapped b) Maximum Dia c) Circle fitting d) OD and Cup (Normal) e) OD and Cup (Abnormal)




Figure 4: Neuro-Retinal Rim area for an abnormal subject

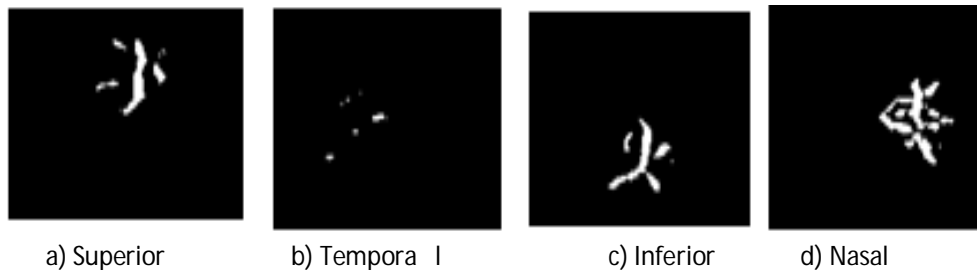


Figure 5: Images of ISNT regions

Ratio of blood vessel area

The blood vessels cover about 27% of the optic disk area⁹. The major blood vessels are concentrated in the inferior and the superior regions and smaller blood vessels are concentrated in the nasal and temporal regions of the optic disc. The ISNT rule is given by, Inferior > Superior >

Nasal > Temporal. A shift in the optic nerve head causes a slight increase in the area covered by blood vessels in the nasal temporal region and decreases the area covered in superior and inferior regions. Hence the ratio of the sum of blood vessel area in inferior and superior regions to nasal and temporal regions can be taken for glaucoma

detection. The optic disc centered image of size 151x151 pixels in the green plane is taken and the contrast of the image is enhanced by adaptive histogram equalization. Bottom-hat filtering with a disk shaped structuring element is then used in this image to highlight the optic nerves within the disk area. Bottom-hat filtering is the equivalent of subtracting the input image from the result of performing a morphological closing operation on the input image. Otsu's thresholding is then applied on the bottom-hat filtered output image to get the binary image of the blood vessels. A mask of size 151x151 pixels is used to filter one quadrant. The mask is rotated by 90° each time and is used on the binary blood vessel image to obtain the area covered by blood vessels in each quadrant. The ratio of blood vessel area covered by inferior and superior regions to area covered by nasal and temporal regions is taken. The ratio is lower for glaucomatous cases and is higher for normal cases. The green plane image of the optic disc is taken and the contrast of the image is enhanced using adaptive histogram equalization. The segmented blood vessels in the inferior, superior, nasal and temporal regions are shown in Figure 5. The result shows that ISNT ratio values for normal images 1.1342 to 2.5295 and the abnormal image show is from 0.6557 to 1.113

Detection System Methodology-II

The CDR range lies between 0.1 to 0.3 confirm the same as a normal image¹⁰. But for the normal images proceed, many images have CDR value more than 0.3. As the feature CDR overlaps for normal and glaucoma images, and also the feature ISNT overlap for the normal and glaucoma images, the another feature texture is also to be analyzed for glaucoma detection as shown in Figure 6. By applying a nonlinear transform to the wavelet coefficients, a better characterization can be obtained for many natural textures, leading to increased classification performance when using first and second order statistics of these coefficients as features. In the present work Daubechines wavelet (db3), Symlets wavelet (sym3), Reverse biorthogonal wavelet, Biorthogonal wavelet, coiflet wavelet are used. The algorithm the steps are given below.

Step 1: First the colour fundus image of size 1504X1000 pixels is loaded.

Step 2: Then the image is resized to 576X768 pixels and Region of Interest (ROI) is taken by resizing the image.

Step 3: The ROI image is then converted to the gray-scale image.

Step 4: The gray scale image is then subjected to the 2D-DWT. It will decompose the image into four sub-bands.

Step 5: Wavelet families (db3, sym3, rbio3.3, rbio3.5, rbio3.7, bior5.5 and coif1) are then applied to the sub-bands to calculate the mean and average of the features.

Step 6: The extracted features are then given to train the classifiers to identify the normal and glaucomatous images.

Step 7: Then the testing images are given to the SVM classifier to obtain normal and glaucoma images.

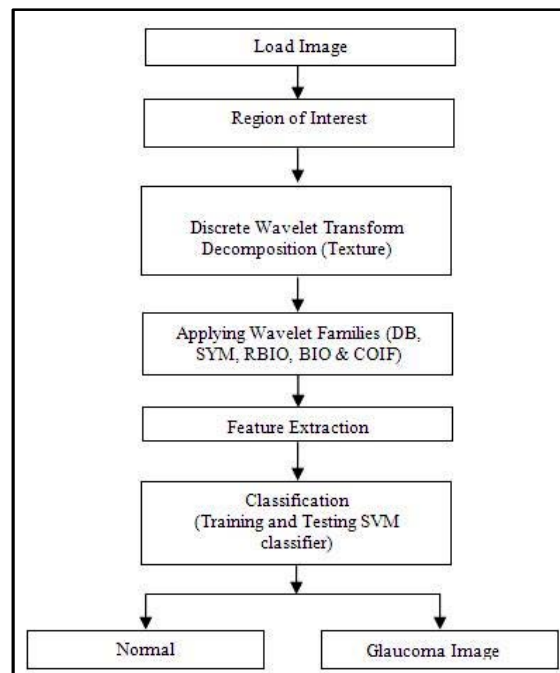


Figure 6: Block Diagram for the proposed method

The features are extracted using various wavelet filters for normal and glaucoma images. From the Figure 7 (a), it is observed that the abnormal image features are no overlaps with the normal image features. Also the Figure 10 (b) shows the mean analysis graph.

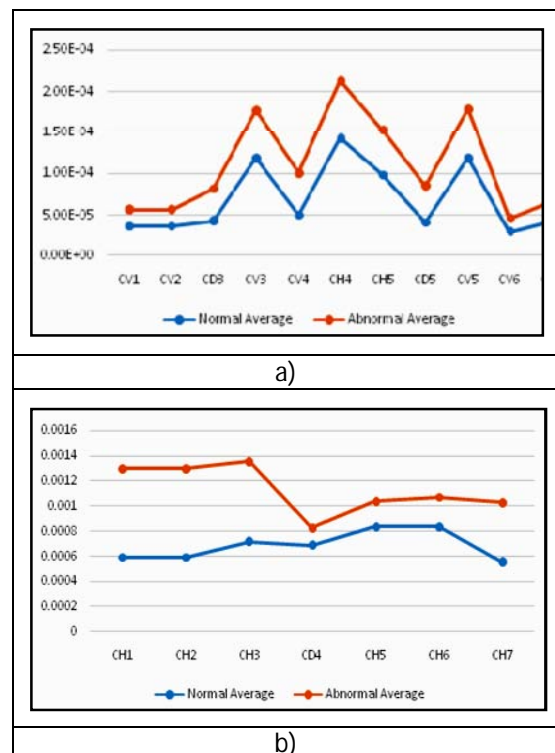


Figure 7: Average Analysis Graph

Classification

In this work, the total fundus images of 100 patients have been used, in which 50 are normal and 50 are glaucoma patients. Features such as CDR, ISNT ratio for blood vessels, ISNT ratio for NRR and texture features are computed. Since normal and the feature values for glaucoma condition are overlapping, simple thresholding technique cannot be applied for detection of glaucoma. Hence support vector machine (SVM) is used for classification. The linear kernel is used to map the training data into the kernel space. Quadratic programming is used to find the separating hyper plane. Table 1 shows the results of the SVM classifier. Out of the 50 normal and 100 glaucoma images, 85 in each are used for training the network and remaining 65 in each are used for testing the network. In the analysis of SVM classifier, the results show sensitivity, specificity and accuracy as 96%, 93.33% and 95.38% respectively.

Table 1: Analysis of SVM classifier

Type of Image	Number of samples used for Training	Number of samples Used for Testing	Correctly Classified Test Data	Percentage Correctly Classified (%)
Normal	35	15	14	93.33%
Glaucoma	50	50	48	96%
Average				94.66%

CONCLUSION

A fast and reliable detection method for finding the optic disc, optic cup, Retinal Blood vessels and NRR area has been presented in this work. Optic disc and optic cup is found using active contour model and fuzzy C – mean clustering algorithm respectively. Circular fitting is applied to smooth the optic disc and optic cup boundary. Morphological method is used to extract the blood vessels inside the optic disc and four different masks are used to calculate the ISNT ratio. The method of considering the ISNT rule is applied to NRR can be used as an additional feature for distinguishing between normal and glaucoma aspects. Progressive loss of NRR tissues gives as accurate result to detect early stage of glaucoma. The method has been applied to nearly hundred and fifty images and the result was correctly identified. The additional features textures are used to detection of glaucoma. The features such as CDR, ISNT rule applied to blood vessels ISNT rule applied to neuro retinal RIM area texture features are computed automatically and the performance of the proposed algorithm is tested in SVM classifier. Experiments results show that the maximum

classification rate is 95, 38% for glaucoma is achieved. In the future, it might give a first low cost glaucoma indication to route the patients to more elaborate clinical trials.

REFERENCES

- Liu, J, Wong, DWK, Lim, JH, Jia, X, Yin, F, Li, H, Xiong, W. Wong, TY 2008, "Optic Cup and Disk Extraction from Retinal Fundus Images for Determination of Cup-to-Disc Ratio", 3rd IEEE Conference on Industrial Electronics and Applications, 1, 2008, 1828 – 1832.
- Zhuo Zhang, Jiang Liu, Wing Kee Wong, Ngan, MengTan, JooHwee Lim, Shijian Lu & Huiqi Li, 2009, "Convex Hull Based Neuro-Retinal Optic Cup Ellipse Optimization in Glaucoma Diagnosis", 3 IEEE International Conference on EMBS, 1, 2009, 1441 – 1444.
- Wong, DWK, Liu, JH & Tan "Intelligent fusion of cup to disc ratio determination methods for glaucoma detection in ARGALI", IEEE International Conference on Engineering in Medicine and Biology, 1, 2009, 5777 – 5780.
- Joshi, G.D.; Sivaswamy, J.; Karan, K.; Krishnadas, S.R., "Optic disk and cup boundary detection using regional information," IEEE International Symposium on Biomedical Imaging: From Nano to Macro, 1, 2010, 948 – 951.
- Madhusudan Mishra, Malaya Kumar Nath and Samarendra Dandapat, "Glaucoma Detection from Color Fundus Images", International Journal of Computer and Communication Technology, 2, 2011, 7–10.
- Chisako Muramatsu, Toshiaki Nakagawa, Akira Sawada, Yuji Hatanaka, Tetsuya Yamamoto, Hiroshi Fujita, "Automated determination of cup-to-disc ratio for classification of glaucomatous and normal eyes on stereo retinal fundus images", Journal of Biomedical optics, 16, 2011, 1–7.
- Yuji Hatanaka, Atsushi Noudo, Chisako Muramatsu, Akira Sawada, Takeshi Hara, Tetsuya Yamamoto & Hiroshi Fujita 2012, "Vertical cup-to-disc ratio measurement for diagnosis of glaucoma on fundus images", Proc. of SPIE Medical Imaging, 7624C, 2012, 1 – 8.
- Jun Cheng, Jiang Liu, Yanwu Xu, Fengshou Yin, Damon Wing, Kee Wong, Ngan-Meng Tan, Dacheng Tao, Ching-Yu Cheng, Tin Aung & Tien Yin Wong, "Superpixel Classification Based Optic Disc and Optic Cup Segmentation for Glaucoma Screening", IEEE Transactions on Medical Imaging, 32, 2013, 1019 – 1032.
- Greaney, M. J., Hoffman, D. C., Garway-Heath, D. F, Nakal, M, Coleman, AL & Caprioli, J., 'Comparison of optic nerve imaging methods to distinguish normal eyes from those with glaucoma', Invest Ophthalmol. Visulal Sci. 43, 2002, 140-145.
- Hossam El-Din MA Khalil, Mohamed Yasser Sayed Saif, Mohamed Osman Abd El-Khalek & Arsany Maker, 'Variations of Cup-to-Disc Ratio in age group (18-40) years old', Research in ophthalmology, vol.2, no.1, 2013, 4-9.

Source of Support: Nil, Conflict of Interest: None.

