

Research Article



Evaluation of Wound Healing Activity of Radona® Tablet in Wistar Rats.

Nitin Mundhe*, Venu Gopal Jonnalagadda, Mukesh Chawda, Kapil Thakur, Mahesh Vahalia, Shekhar Shitut
Shree Dhootpapeshwar Ayurvedic Research Foundation (SDARF), Panvel, Navi-Mumbai, Maharashtra, India.

*Corresponding author's E-mail: mundhenitin2@gmail.com

Accepted on: 22-01-2015; Finalized on: 28-02-2015.

ABSTRACT

Wound healing is an important aspect in surgical procedures. Only antibiotics and local management may not be sufficient for proper wound healing. Skin care has always been the strength of Ayurveda and management of wounds has been described in depth in Ayurvedic texts. This study was aimed to evaluate the wound healing potential of Radona® Tablets in the excision and incision model in Wistar Rats. 36 Wistar Rats of either sex weighing around 150-200g were divided equally for excision and incision models. Animals in each model were divided into three groups of 6 animals per each viz. Normal control (1 ml/kg, p.o.), Radona® Tablet (648 mg/kg, p.o.) and Soframycin (1 % w/w, topical). The test drug was administered for 21 days in excision model and for 9 days in incision model. In excision model, a wound area of about 250 mm² and about 2 mm in depth was studied by tracing the raw wound area on the subsequent days 1, 4, 8, 12, 16 and 21 on graph paper for wound contraction. The scar area and time for complete epithelization was also evaluated. In incision model, on 10th day the tensile strength was measured. The results showing *p* values < 0.05 were considered significant and all values are expressed as mean ± S.E.M. Significant decrease in epithelization period (*p*<0.05 and *p*<0.01), scar width (*p*<0.05 and *p*<0.01) and wound contraction (*p*<0.05 and *p*<0.01) on 21st day in excision model and significant increase in tensile strength (*p*<0.05 and *p*<0.01) in incision model was observed in treated groups (Radona® Tablet and Soframycin) as compared to control group. The result suggests that Radona® Tablet has significant wound-healing activity nearly equal to standard Soframycin ointment.

Keywords: Wound healing, Radona® Tablet, Tensile strength, wound contraction, Epithelization etc.

INTRODUCTION

The wound is an injury that results in the breaking of cellular and anatomical continuity of living tissues¹. The lesions caused by environmental abuse, mechanical or chemical injuries, may extend from epidermis deep into the muscle depending upon the severity of injuries. They may include cuts, scrapes, scratches, and punctured skin². Wound Healing Society, describes that, wounds are physical injuries that result in an opening or break of the skin that cause interruption in the normal skin anatomy and function³. It is an intricate and dynamic physical process to supersede devitalized and missing cellular structures and tissue layers i.e. scar formation⁴. This is protect live biological process, which occur via different phases namely, coagulation, epithelization, granulation, collogenation and tissue remodeling⁵. But in developing countries wound infection may occur due to poor hygenic conditions. Microbial organisms like *Staphylococcus aureus*, *Corynebacterium* spp., *Escherichia coli*, *Pseudomonas aeruginosa* and *Streptococcus pyogenes* are the organism that causes wound infection⁶. Nowadays, various antibiotic drugs are in market for treatment of wound infection but unlikely, along with resistance developed by pathogen against them, many of antibiotics have adverse effect in the human body⁶.

India has great natural flora that are widely distributed in biodiversity of Indian territory. India is a repository of Ayurveda and a paradise for traditional medicinal system⁷. Nowadays developed countries are also turning

towards a traditional medicinal system that involves the use of herbal drugs and remedies. According to WHO reports more than 80% of the world's population still depends upon the traditional medicinal system for treatment of various diseases. Moreover, 25% of modern drugs are based on medicinal plants and its derivatives⁸. Since ancient time in India, herbal medicines have been the basis of treatment and cure for various diseases physiological conditions in traditional methods practiced such as Ayurveda, Unani and Siddha^{9,10}.

Radona® Tablet is a herbomineral preparation in tablet form, marketed by Solumiks Herbaceuticals Limited, Mumbai. It consists of Khadira (*Acacia catechu*)¹¹, Musta (*Cyperus rotundus*)¹², Daruharidra (*Berberis aristata*)¹³, Vidanga (*Embelia ribes*)¹⁴, Manjishtha (*Rubia cordifolia*)¹⁵, Nimba (*Azadirachta indica*)¹⁶, Shveta Sariva (*Hemidesmus indicus*)¹⁷, Trivrut (*Ipomoea turpethum*)¹⁸, Rakta Chandana (*Pterocarpus santalinus*)¹⁹, Katuka (*Picrorhiza kurroa*)²⁰, Shveta Chandana (*Santalum album*)²¹, Gandhak Rasayan²², Vanga Bhasma²³ and Yashada Bhasma²⁴ as active ingredients, which have been investigated for wound healing activity in various animal models. Most of the ingredients have been rich source of anti-oxidant and astringent in action. In addition to symptomatic relief the ingredients in Radona® Tablets are known to strengthen the skin's ability to heal and also improve the skin complexion.

Currently, various topical agents are used for treatment for wound healing. But most of them are contraindicated with a particular condition. So, prevention or treatment



of the wound healing is one of the challenging problems because currently, available therapy due its less effectiveness and severe side effects^{25,26}. Health professionals looking towards compounds with no or minimal side effects to treat wound healing. In this context, ayurvedic system has the potential to treat a number of diseases with many herbal plants and products².

MATERIALS AND METHODS

Animals

A total 36 healthy inbred Wistar rats of either sex (150-200gm, 6-8 weeks) were obtained from Laboratory of Animal house facility of Shree Dhootapapeshwar Ayurvedic Research foundation (SDARF-Panvel). Animals were kept in standard conditions like 22 °C ± 2 °C and relative humidity 55 ± 15 %. The rats were housed in polypropylene cages on normal food and water ad libitum with a 12 hour light and dark cycle. All animals were acclimatized for at least 1 week before start of study. Animals were periodically weighed before and after experiments. The rats were anaesthetized prior to infliction of the experimental wounds.

The surgical interventions were carried out under sterile conditions using ketamine anaesthesia (10 mg/kg). Animals were closely observed for any infection; those which showed signs of infection were separated and excluded from the study. All the experimental protocols were approved by Institutional Animal Ethics Committee and performed according to the CPCSEA guidelines for the care and use of animals (SDARF/PC/2014/02).

Chemicals

Radona® Tablets were collected from the Solumiks Herbaceuticals Limited, (SHL) Mumbai. And all other drugs were purchased from Sigma Aldrich Mumbai.

Wound Healing Activity

Excision and incision wound models were used to evaluate the wound–healing activity of Radona® Tablets.

Excision Wound

The rats were inflicted with excision wounds as described by Morton and Malon²⁵. The animals were anaesthetized prior to creation of wounds, by using Sodium Pentobarbital (40 mg/kg i.p).

An impression was made on the dorsal thoracic region 1 cm away from the vertebral column and 5 cm away from ear on the anaesthetized rats. The particular skin area was shaved 1 day prior to the experiment. The skin of impressed area was excised to the full thickness to obtain a wound area of about 250 mm². Hemostasis was achieved by blotting the wound with a cotton swab soaked in normal saline. The wound contraction was studied by tracing the raw wound area on the subsequent days 1st, 4th, 8th, 12th, 16th, 18th and 21st on graph paper. Scar area and time for complete epithelisation were

measured²⁵. The percentage of wound contraction were recorded as:

$$\text{wound contraction} = \left(\frac{\text{area on day zero} - \text{area on day of measurement}}{\text{area on day zero}} \right) \times 100$$

The period of epithelisation was calculated as per the number of days required for falling of the dead tissue remnants without any residual raw wound. The animals were divided into three groups of 6 each. The group I animals were treated with simple ointment and considered as the control. Animals of group II were treated with Radona® Tablet (648 mg/kg body weight p.o) and simple ointment base topically. Group III animals served as reference standard and treated with Soframycin ointment daily at once.

Incision Method

The rats were anaesthetized prior to and during creation of the wounds, the animals were anaesthetized by using sodium pentobarbital (40 mg/kg i.p). Para vertebral stright incisions of 6 cm length were made through the entire thickness of the skin, on either side of the vertebral column with the help of a sharp scapel. After complete haemostasis, the wound were closed by means of interrupted sutures placed at equidistant points about 1 cm apart. Animals were treated once a day with drug from 0 day to 9 day. Tensile strenght were determined on 10th day.

$$\text{Tensile Strength} = \left(\frac{\text{Breaking strength in gm}}{\text{cross sectional area of skin (mm}^2\text{)}} \right)$$

The animals were divided into three groups of 6 each. The group I animals were treated with simple ointment and considered as the control. Animals of group II were treated with Radona® Tablet (648 mg/kg body weight) and simple ointment base. Group III animals served as reference standard and treated with Soframycin ointment once daily².

Statistical Analysis

Results expressed as Mean ± SE were evaluated using the t-test. Values of p < 0.05 were considered statistically significant.

Effect of Radona® Tablet on Excision Wound

The result of wound healing activity by excision wound model were represented in Table 1: the values presented in table represent the percentage of wound healing at 1st, 4th, 8th, 12th, 16th, and 21st days for control (simple ointment base), Radona® Tablet treated (Radona® Tablet + Simple ointment base), and Standard control (Soframycin ointment). In present study it was observed that, wound contracting ability of animals treated with Radona® Tablet showed the significantly higher (p<0.05), faster the epithelization period and scar formation in Radona® Tablet treated animals as comparison to normal control animals.

Graph I represents the wound healing index which was found to be significantly decreased in Radona® Tablet



treated rats with comparison to normal control animals (p<0.05).

Effect of Radona® Tablet on Incision Wound

The results of tensile strength were represented in graph II. The result showed that tensile strength was found to be significantly increased in Radona® Tablet treated rats with comparison to normal control animal (p<0.05).

DISCUSSION

Wound healing is a complex biological process which undergoes a cascade of biochemical and cellular reactions initiated in response to an injury that restore the function and integrity of broken tissues^{27,28}. However, it is a repair process of injured tissues occurring as a sequence of events, which includes inflammation, proliferation and maturation²⁹. But the extent of healing is mostly based on the repairing ability of the tissue, rigour of damage and full general state of physical health of the tissue²⁹.

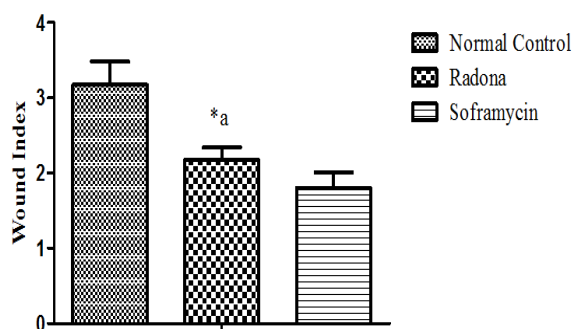
Also, it requires the cooperative efforts from many different tissues and cell lineages, it may comprise platelet aggregation, blood clotting, formation of fibrin, an inflammatory response to injury, angiogenesis and re-epithelialization³⁰.

After the completion of all the phases of healing, the wound under goes contraction resulting into formation of a small apparent scar tissue³¹. Herbal medicines have been used since time immemorial for the prevention and

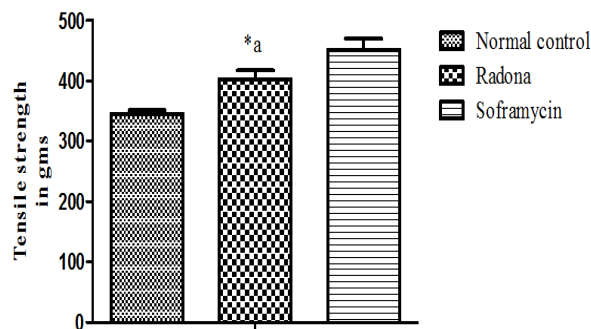
treatment of various ailments^{32,33}. Various studies showed that constituents of plants are potential agent for treatment of wound healing.

In present study, the excision and Incision wound healing by granulation, collagenation and tensile strength measured indirectly to assess the collagen content and maturation. The wound healing property of Radona® Tablet is attributed to constituents present in Radona® Tablet. In the excision model the animal treated with Radona® Tablet showed significantly increased wound contraction on day 8th, 12th, 16th, and 21st with comparison to simple ointment treated normal control animals. The increased level of wound contraction clearly revealed that Radona® Tablet having ability to induce cellular proliferation. Likewise, the rate of epithelization was found to increased in Radona® Tablet treated rats as compared to normal control animals. However, the scar area formation was found to be decrease in Radona® Tablet treated rats. The result reveals that the animals treated with Radona® Tablet showed faster rate of epithelization as comparison to simple ointment treated normal control animals.

The increased in tensile strength of wounded skin indicated the promotion of collagen fibers. In incision wound method, the tensile strength of Radona® Tablet treated rats showed significantly increased in when comparison to normal control animals and nearly same as standard soframycin ointment in rats.



Graph I: Effect of Radona® Tablet on wound index



Graph-II: Effect of Radona® Tablet on tensile strength

All data were expressed in Mean ± SEM where (n=6), Normal control animal and Radona® Tablet treated rats were treated with simple ointment base and Radona® Tablet + simple ointment base respectively and Soframycin ointment consider as standard treatment. Where Radona® Tablet group compared with normal control group by student t test. ^{*a}p <0.05.

Table 1: Effect of Radona® Tablet on wound contraction.

S. No.	Groups	Wound contraction (%) in days						Epithelization in days	Scar area (mm ²)
		1 st	4 th	8 th	12 th	16 th	21 st		
1	Normal control	0	2.27 ± 0.51	28.33 ± 3.57	60.05 ± 2.34	68.16 ± 2.89	86.72 ± 2.31	24.17 ± 0.48	126.5 ± 4.43
2	Radona	0	3 ± 0.86	43.11 ± 3.49 ^{*a}	66.77 ± 1.32 ^{*a}	77.28 ± 1.52 ^{*a}	94.11 ± 2.22 ^{**a}	21.83 ± 0.87	94.83 ± 2.5
3	Soframycin	0	4.16 ± 0.56	46.38 ± 3.02	66.99 ± 1.38	80.55 ± 2.34	95.78 ± 2.61	20.5 ± 0.34	78.67 ± 5.83

All data were expressed in Mean ± SEM where (n=6), Normal control animal and Radona® Tablet treated rats were treated with simple ointment base and Radona® Tablet + simple ointment base respectively and Soframycin ointment consider as standard treatment. Where Radona® Tablet group compared with normal control group by student t test. ^{*a}p < 0.05, ^{**a}p < 0.01.

Table 2: Constituents of Radona[®] Tablet having their roles in wound healing.

S. No.	Radona [®] Tablet Constituents	Mechanism of action in wound-Healing	Reference
1.	Khadira (Acacia catechu)	It has strong astringent and antimicrobial property, which seems to be responsible for wound contraction and increased rate of epithelialization.	(¹¹⁻³⁵)
2.	Musta (Cyperus rotundus)	It is act in inflammatory phase and reduceses the swelling.	(¹²⁻³⁶)
3.	Daruharidra (Berberis aristata)	It enhance wound contraction, shortened epithelialization period, and increases tensile strength.	(¹³)
4.	Vidanga (Embelia ribes)	Increases tensile strength and faster rate of epithlisation.	(¹⁴)
5.	Manjishtha (Rubia cordifolia)	It increases the granulation tissue formation and subsequent epithelization.	(¹⁵)
6.	Nimba (Azadiracta Indica)	Promoting contraction of the wound and proliferation of dermal fibroblasts.	(¹⁶)
7.	shveta Sariva (Hemidesmus indicus)	It has strong astringent and antimicrobial property, which seems to be responsible for wound contraction and increased rate of epithelialization	(¹⁷)
8.	Trivrut (Ipomoea Turpethum)	Antimicrobial and antioxidant activity of Trivrut which seems to be promote faster epithelization.	(¹⁸)
9.	Rakta Chandana (Pterocarpus Santalinus)	It has strong astringent and antimicrobial property, which seems to be responsible for wound contraction and increased rate of epithelialization	(¹⁹)
10.	Katuka (Picrorhiza Kurroa)	It improves re-epithelialization, neovascularization and migration of endothelial cells, dermal myofibroblasts and fibroblasts into the wound bed.	(²⁰)
11.	Shveta chandana (Santalum album)	It has strong astringent and antimicrobial property, which seems to be responsible for wound contraction and increased rate of epithelialization	(²¹)
12.	Gandhak Rasayan	The anti-bacterial activity of Gandhak Rasayan promote wound contraction.	(²²)
13.	Vanga Bhasm	Tin is the principle constituent of Vanga Bhasm and it acts as antimicrobial, it explorates wound-Healing by enhancing wound contraction.	(²²)
14.	Yashada Bhasm (zinc complex)	It is a rich source of Zinc and acts as cofactor in synthesis of collagen fibre.	(²⁴)

Thus, wound healing possession of Radona[®] Tablet may be attributed to phytoconstituents and minerals present in it, which may be due to their additive effect that fastens the process of wound healing.

CONCLUSION

However the result of present study clearly demonstrated the exploratory wound healing potential of Radona[®] Tablet. According to present findings, the wound-healing activity of Radona[®] Tablet might be due to production of collagen fiber in the skin.

The result suggests that Radona[®] Tablet having significant wound-healing activity nearly equal to standard soframycin ointment.

Source of Support

Solumiks Herbaceuticals Ltd. India.

REFERENCES

1. Ayello, E.A. What does the wound say? Why determining etiology is essential for appropriate wound care. *Adv Skin Wound Care* 18, 2005, 98-109, quiz 110-101.
2. Sheeba M., E.E., Revthi K., Ignacimutthu S., Wound healing activity of Cassia Occidentalis L. in albino wistar rats. *International journal of Intregative biology*, 1, 2009.
3. F. S. Physiology of wound healing. *Newborn Infant Nurs. Rev*, 1, 2001, 43-45.
4. Jain V., P.V.a.P.R. Wound healing activity of Desmodium gangeticum in Different Wound Model. *Journal of Plant Sciences*, 1, 2006, 247-253.
5. Maxson S., Lopez E.A., Yoo D., Danilkovitch-Miagkova A. & Leroux M.A. Concise review: role of mesenchymal stem cells in wound repair. *Stem Cells Transl Med*, 1, 2012, 142-149.
6. Senthil Kumar M., Sripriya R., Vijaya Raghavan H. & Sehgal P.K. Wound healing potential of Cassia fistula on infected albino rat model. *J Surg Res*, 131, 2006, 283-289.
7. Perumal S., I.S., Patric R., Preliminary screening of ethnomedicinal plants from India. *Eur Rev Med Pharmacol Sci*, 12, 2008, 1-7.
8. P. P. Monetising the pharmacological benefits of plants. *US Environmental protection Agency, Washington*, 2005.



9. Priya K.S., Gnanamani A., Radhakrishnan N. & Babu M. Healing potential of *Datura alba* on burn wounds in albino rats. *J Ethnopharmacol* 83, 2002, 193-199.
10. Steenkamp V., Mathivha E., Gouws M.C. & Van Rensburg, C.E. Studies on antibacterial, antioxidant and fibroblast growth stimulation of wound healing remedies from South Africa. *J Ethnopharmacol*, 95, 2004, 353-357.
11. Lakshmi.T, G.R., Anitha R. *In Vitro* Anti Bacterial Activity Of Ethanolic Bark Extract Of *Acacia Catechu* Willd Against Enteric Pathogens. *Int. J. Drug Dev. & Res.*, 3, 2011, 328-334.
12. Puratchikody A., D.C., Nagalakshmi G. Wound healing activity of *Cyperus rotundus* Linn. *Indian J Pharm Sci*, 68, 2006, 97-101.
13. Sharma K., B.R., Chauhan N., Shrivastava B., Neeraj K. *Berberis Aristata*: A REVIEW. *IJRAP* 2, 2011, 383-388.
14. Souravi K., a.R.P. Ethnopharmacological Uses of *Embelia ribes* Burm. F. - A Review. *Journal of Pharmacy and Biological Sciences*, 9, 2014, 23-30.
15. Anil K., S.P., Shukla V. Evaluation of Nimba Taila and Manjistha Churna in Non Healing Ulcer *IRJP*, 2, 2011, 201-210.
16. Palak V., P.P., Shukla J. An Herbal Wound Healing Gel Prepared with Pachavalkala Kwatha, Nimba Kwatha and Kumari Swarasa with their Physico Chemical Parameters. *Dis Colon Rectum*, 54, 2011, 495-500.
17. Shishira Bharadwaj, S.N. Experimental evaluation of prophylactic and curative effect of a herbal drug *Hemidesmus indicus* R.Br. in drug induced ulcers in wistar albino rats. *Int J Res Med Sci*. 54, 2011, 495-500.
18. Kolhe R., A.R., Harisha C. Comparative Pharmacognostical Evaluation of Three Source Drugs of *Trivrut* Ayurpharm. *Int J Ayur Alli Sci.*, 3, 2014, 195-202.
19. kankanange K., A.I., Walpola B., Subhasinghe S., and Yoon M. *Pterocarpus Santalinus* Linn f. (Rath Handun) : a review of its botany, use, phytochemistry, and pharmacology. *J.Korean Soc.appl. Biol.chem*, 54, 2011, 495-500.
20. Banerjee D., Maity B., Nag S.K., Bandyopadhyay S.K. & Chattopadhyay S. Healing potential of *Picrorhiza kurroa* (Scrofulariaceae) rhizomes against indomethacin-induced gastric ulceration: a mechanistic exploration. *BMC Complement Altern Med*, 8, 2008, 3.
21. Ranasinghe R., E.E. A Critical Analysis of Properties of Mahadalu Anupana in Ayurvedic and Modern Aspect in the Management of Vata Vyadhi. *JAHM* 2, 2014, 31-35.
22. Sarkar P.K., Das S. & Prajapati P.K. Ancient concept of metal pharmacology based on Ayurvedic literature. *Anc Sci Life*, 29, 2010, 1-6.
23. Pandya K., S.B., Shah B., Parekh D., Soni H., Maniar K., Gurav N., Patel P. Phyto-chemical Screening & Evaluation of Antibacterial Activity of Polyherbal Formulation. *Indo-Global Journal of Pharmaceutical Sciences*, 1, 2011, 206-218.
24. Hema Sharma Datta, S.K., and Bhushan Patwardhan. Volume 2011 Wound Healing Activity of Topical Application Forms Based on Ayurveda. *Evidence-Based Complementary and Alternative Medicine*, 2011.
25. Morton J.J. & Malone M.H. Evaluation of vulnerary activity by an open wound procedure in rats. *Arch Int Pharmacodyn Ther*, 196, 1972, 117-126.
26. Bodnar R.J. Anti-Angiogenic Drugs: Involvement in Cutaneous Side Effects and Wound-Healing Complication. *Adv Wound Care (New Rochelle)*, 3, 2014, 635-646.
27. Bhutani K.K. & Gohil V.M. Natural products drug discovery research in India: status and appraisal. *Indian J Exp Biol*, 48, 2010, 199-207.
28. Agarwal P.K. Evaluation of wound healing activity of extracts of plantain banana (*Musa sapientum* var. *paradisiaca*) in rats. *Indian J Exp Biol*, 47, 2009, 32-40.
29. Roy P. *In vivo* antioxidative property, antimicrobial and wound healing activity of flower extracts of *Pyrostegia venusta* (Ker Gawl) Miers. *J Ethnopharmacol*, 140, 2012, 186-192.
30. Kumar B., Vijayakumar,M., Govindarajan R. & Pushpangadan P. Ethnopharmacological approaches to wound healing-exploring medicinal plants of India. *J Ethnopharmacol*, 114, 2007, 103-113.
31. Kumar R., Katoch S.S. & Sharma S. Beta-adrenoceptor agonist treatment reverses denervation atrophy with augmentation of collagen proliferation in denervated mice gastrocnemius muscle. *Indian J Exp Biol*, 44, 2006, 371-376.
32. Kokane D.D. Evaluation of wound healing activity of root of *Mimosa pudica*. *J Ethnopharmacol*, 124, 2009, 311-315.
33. Chah K.F., Eze C.A., Emuelosi C.E. & Esimone C.O. Antibacterial and wound healing properties of methanolic extracts of some Nigerian medicinal plants. *J Ethnopharmacol*, 104, 2006, 164-167.
34. K., H.S.a.A. A Recent Update of Botanicals for Wound Healing Activity. *IRJP*, 3, 2012.
35. Naik G.H. Comparative antioxidant activity of individual herbal components used in Ayurvedic medicine. *Phytochemistry*, 63, 2003, 97-104.
36. Kilani S., A.A., Chraief I., Ben R., Hayder N., Hammami M., Ghedira K., Chekir-Ghedira L. Chemical composition, antibacterial and antimutagenic activities of essential oil from (Tunisian) *Cyperus rotundus*. *J.Essent. Oil Res*, 17, 2005, 695-700.

Conflict of Interest: None.

