



## Effect of Metronidazole on Reproductive Parameters in Male Wistar Rats

Oyedeeji K.O.<sup>1</sup>, Oshatimi Abayomi<sup>2</sup>, Abidoje Dele<sup>3</sup>, Adeleke K.O.<sup>4</sup>

<sup>1</sup>Department of Physiology, College of Medicine and Health Sciences, AfeBabalola University, Ado-Ekiti, Nigeria.

<sup>2</sup>Department of Physiology, College of Health Sciences, Ladoké Akintola University of Technology, Ogbomoso, Nigeria.

<sup>3</sup>Department of Physiology, College of Medicine, Lagos State University, Lagos, Nigeria.

<sup>4</sup>Department of Pharmacognosy, Faculty of Pharmacy, University of Ibadan, Nigeria.

\*Corresponding author's E-mail: [sinaoyedeeji@yahoo.com](mailto:sinaoyedeeji@yahoo.com)

Accepted on: 02-10-2015; Finalized on: 31-10-2015.

### ABSTRACT

This study aims at investigating the effect of metronidazole on reproductive parameters in male rats. Ten male rats (120 – 150 g) were divided into control (distilled water) and metronidazole – treated (400 mg/kg) groups (5 per group) for hormonal assay, andrological and histopathological studies. The animals were orally treated on daily basis for 30 days. Plasma testosterone level was assayed using Enzyme – Linked Immuno-Sorbent Assay (ELISA) and semen analysis was done microscopically. Histology of testes was also done. Data were analyzed using descriptive statistics and ANOVA at  $p=0.05$ . Treatment of rats with metronidazole caused no significant ( $p>0.05$ ) changes in body weight relative to the control. Metronidazole caused significant ( $p<0.05$ ) decrease in testosterone level, sperm motility and sperm count relative to the control. Metronidazole caused no significant ( $p>0.05$ ) change in sperm viability relative to the control but produced significant ( $p<0.05$ ) increase in percentage abnormal sperm morphology relative to the control. It also caused mild erosion of the germinal epithelia. These findings revealed that metronidazole probably cause deleterious effect on the reproductive parameters in male albino rats.

**Keywords:** Metronidazole, Testosterone, Sperm motility, Sperm count, Rats.

### INTRODUCTION

Metronidazole is one of those chemotherapeutic agents that had been used in treatment of ailments caused by anaerobic bacteria and certain anaerobic protozoa such as *Trichomonas vaginalis*, *Entamoeba histolytica*, and *Giardia lamblia*<sup>1</sup>. Metronidazole has been reported to induce a reversible bone marrow depression in male mice<sup>2</sup>. It has been reported to induce neoplasia<sup>3</sup>. It is both tumorigenic in rodents and mutagenic in bacteria<sup>4</sup>.

Long term treatment with metronidazole has been reported to induce significant increase in the frequency of chromosomal aberrations in rats<sup>5</sup>. It has been reported to interfere with early fascial wound healing in rats<sup>6</sup>. Metronidazole has been reported to have some beneficial effects on hematological functions and blood chemistry in male rats<sup>7</sup>.

However, due to paucity of information from literature on the effect of metronidazole on reproductive parameters in male rats, this study aims at investigating its effect on these aforementioned parameters.

### MATERIALS AND METHODS

#### Experimental Animals

Adult male rats weighing between 120 g – 150 g bred in the Pre-Clinical Animal House of the College of Medicine and Health Sciences, AfeBabalola University were used.

They were housed under standard laboratory conditions and had free access to feed and water.

They were acclimatized for two weeks to laboratory conditions before the commencement of the experiments.

All experiments were carried out in compliance with the recommendations of AfeBabalola University Ethics Committee on guiding principles on care and use of animals.

#### Drug

Metronidazole tablets (Ecomed Pharm Ltd) were brought from Danax Pharmacy, Ibadan, Nigeria.

Two hundred milligram (200 mg) of metronidazole was dissolved in 20 ml of distilled water to give a concentration of 10 mg/ml.

#### Body Weight

Body weight was monitored on weekly basis throughout the duration of the experiment for each rat.

#### Experimental Design

Ten animals (120 – 150g) were randomly divided into two groups with each group consisting of five rats.

The two groups of rats were subjected to the following oral treatments once a day for thirty days and the dosage of metronidazole used in this study was in accordance with that reported by<sup>7</sup>.

Group I: rats received 0.5 ml of distilled water as the control group.

Group II: rats received 400 mg/kg of metronidazole.



### Collection of Blood Samples

Twenty four hours (day 31) after the last dosing of the groups, blood samples were collected from all the animals through the medial cantus for the determination of plasma testosterone level. All the animals were later sacrificed by cervical dislocation and the testes were removed along with the epididymis for semen analysis.

### Hormonal Assay

Plasma samples were assayed for testosterone using the Enzyme-Linked Immunosorbent Assay (ELISA) technique using the Fortress kit.

### Semen Collection

The testes were removed along with the epididymides. The caudal epididymides were separated from the testes, blotted with filter papers and lacerated to collect the semen.

### Semen Analysis

#### Progressive sperm motility

This was done immediately after the semen collection. Semen was squeezed from the caudal epididymis onto a pre-warmed microscope slide (27°C) and two drops of warm 2.9% sodium citrate was added, the slide was then covered with a warm cover slip and examined under the microscope using x 400 magnification. Ten fields of the microscope were randomly selected and the sperm motility of 10 sperms was assessed on each field. Therefore, the motility of 100 sperms was assessed randomly. Sperms were labeled as motile, sluggish, or immotile. The percentage of motile sperms was defined as the number of motile sperms divided by the total number of counted sperms (i.e. 100)<sup>8</sup>.

#### Sperm viability (Life/dead ratio)

This was done by adding two drops of warm Eosin/Nigrosin stain to the semen on a pre-warmed slide, a uniform smear was then made and dried with air; the stained slide was immediately examined under the microscope using x400 magnification. The live sperm cells were unstained while the dead sperm cells absorbed the stain. The stained and unstained sperm were counted and the percentage was calculated<sup>9</sup>.

#### Sperm morphology

This was done by adding two drops of warm Walls and Ewas stain (Eosin/Nigrosin stain can also be used) to the semen on a pre-warmed slide, a uniform smear was then made and air-dried; the stained slide was immediately examined under the microscope using x400 magnification<sup>9</sup>. Five fields of the microscope were randomly selected and the types and number of abnormal spermatozoa were evaluated from the total number of spermatozoa in the five fields; the number of abnormal spermatozoa were expressed as a percentage of the total number of spermatozoa.

### Sperm count

This was done by removing the caudal epididymis from the right testes and blotted with filter paper. The caudal epididymis was immersed in 5ml formol-saline in a graduated test-tube and the volume of fluid displaced was taken as the volume of the epididymis.

The caudal epididymis and the 5ml formol- saline were then poured into a mortar and homogenized into a suspension from which the sperm count was carried out using the Improved Neubauerhemocytometer under the microscope.

### Testicular Histology

After removing the testes, they were immediately fixed in Bouin's fluid for 12 hours and the Bouin's fixative was washed from the samples with 70% alcohol.

The tissues were then cut in slabs of about 0.5cm transversely and were dehydrated by passing through different grades of alcohol: 70% alcohol for 2 hours, 95% alcohol for 2 hours, 100% alcohol for 2 hours, 100% alcohol for 2 hours and finally 100% alcohol for 2 hours. The tissues were then cleared to remove the alcohol, the clearing was done for 6 hours using xylene.

The tissues were then infiltrated in molten Paraffin wax for 2 hours in an oven at 57°C, thereafter the tissues were embedded. Serial sections were cut using rotary microtone at 5 microns (5µm). The satisfactory ribbons were picked up from a water bath (50– 55°C) with microscope slides that had been coated on one side with egg albumin as an adhesive and the slides were dried in an oven. Each section was deparaffinized in xylene for 1 minute before immersed in absolute alcohol for 1 minute and later in descending grades of alcohol for about 30 seconds each to hydrate it.

The slides were then rinsed in water and immersed in alcoholic solution of hematoxylin for about 18 minutes.

The slides were rinsed in water, then differentiated in 1% acid alcohol and then put inside a running tapwater to blue and then counterstained in alcoholic eosin for 30 seconds and rinsed in water for a few seconds, before being immersed in 70%, 90% and twice in absolute alcohol for 30 seconds each to dehydrate the preparations. The preparations were cleared of alcohol by dipping them in xylene for 1 minute.

Each slide was then cleaned, blotted and mounted with DPX and cover slip, and examined under the microscope. Photomicrographs were taken at x40, x100 and x400 magnifications.

### Statistical Analysis

The mean and standard error of mean (S.E.M.) were calculated for all values. Comparisons between the control and the treated groups were done using one-way analysis of variance (ANOVA) with Duncan's Multiple

Range Test. Differences were considered statistically significant at  $p < 0.05$ .

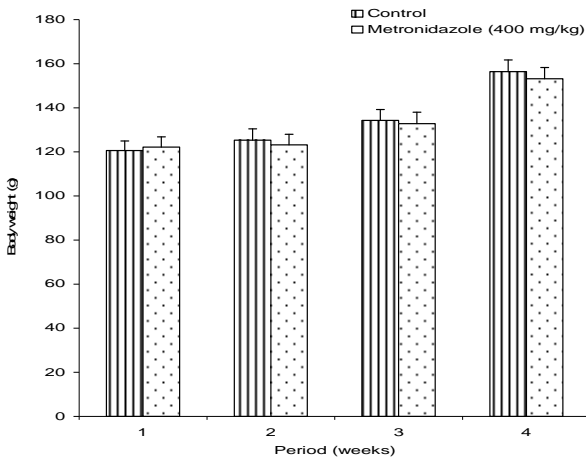
**RESULTS**

Treatment of rats for 30 days with metronidazole (400 mg/kg) produced no significant ( $p > 0.05$ ) changes in body weight of treated rats relative to the control (Figure 1).

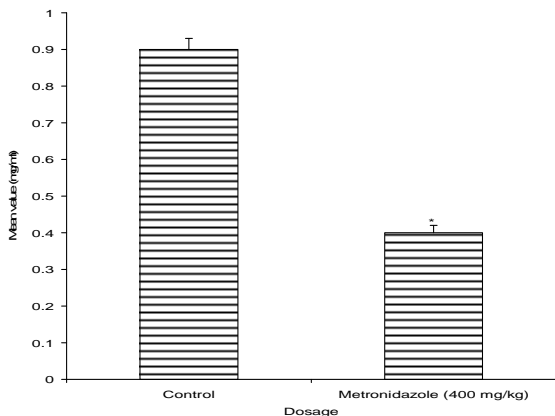
Treatment of rats for 30 days with 400 mg/kg metronidazole caused significant ( $p < 0.05$ ) decrease in testosterone level relative to the control (Figure 2).

Treatment of rats for 30 days with metronidazole (400 mg/kg) caused significant ( $p < 0.05$ ) decrease in sperm motility relative to the control, but caused no significant ( $p > 0.05$ ) change in sperm viability relative to the control. Treatment of rats with metronidazole (400 mg/kg) caused significant ( $p < 0.05$ ) increase in the percentage of abnormal sperm cells relative to the control. Treatment of rats with metronidazole (400 mg/kg) also caused significant ( $p < 0.05$ ) decrease in sperm count relative to the control (Figures 3 and 4).

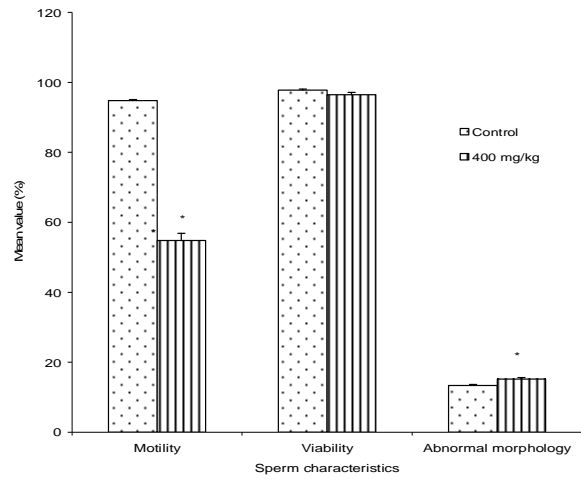
Treatment of rats with metronidazole caused mild erosion of the germinal epithelia, while no visible lesions were observed in the control rats (Plates 1 and 2).



**Figure 1:** Body weight changes in control rats and rats treated with metronidazole (400 mg/kg) for 30 days ( $n=5$ ,  $*p < 0.05$ )

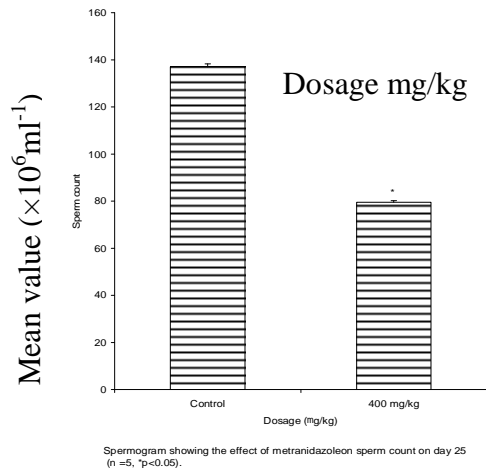


**Figure 2:** Effect of treatment of rats for 30 days with metronidazole (400 mg/kg) on plasma level of testosterone ( $n=5$ ,  $*p < 0.05$ )



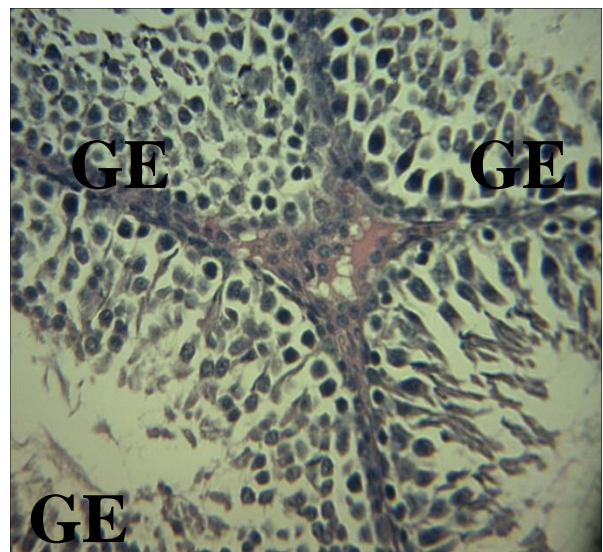
Spermogram showing the effect of metronidazole on sperm characteristics on day 25 ( $n=5$ ,  $*p < 0.05$ ).

**Figure 3:** Spermogram showing the effect of metronidazole on sperm characteristics after treatment of rats for 25 days ( $n=5$ ,  $*p < 0.05$ )



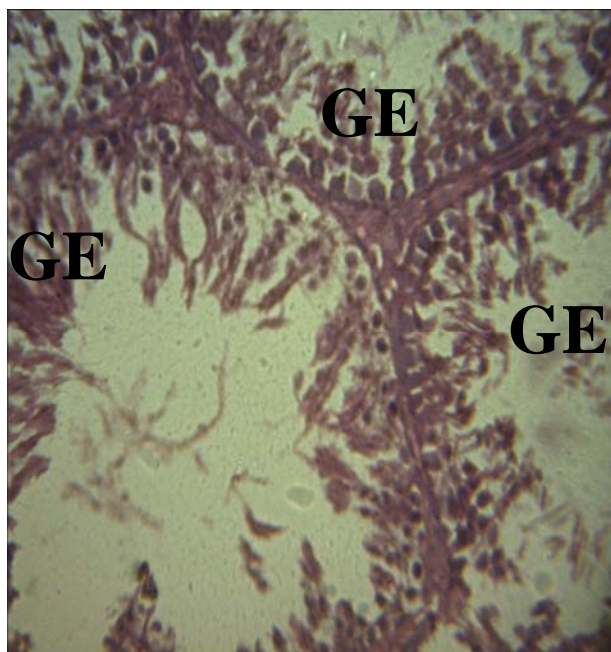
Spermogram showing the effect of metronidazole on sperm count on day 25 ( $n=5$ ,  $*p < 0.05$ ).

**Figure 4:** Spermogram showing the effect of metronidazole on sperm count after treatment of rats for 25 days ( $n=5$ ,  $*p < 0.05$ )



**Plate 1:** Effect of 0.5 ml distilled water (control) on rat testis after treatment for 30 days ( $x 400$ ).

Photomicrograph showing normal viable germinal epithelium (GE) with no visible lesion.



**Plate 2:** Effect of metronidazole (400 mg/kg) on rat's testis after treatment of rat for 30 days (x 400).

Photomicrograph showing eroded or scanty germinal epithelia (GE).

## DISCUSSION

This study has shown that the treatment of rats with metronidazole for thirty days produced no significant changes in body weight of rats. This could be due to the absence of androgenic property in this drug, since it has been reported that androgens possess anabolic activities<sup>10</sup>. It could also be due to absence of anorectic and lipolytic properties in this drug<sup>11</sup>. Similar result was reported by<sup>12</sup> in *Vernoniaamygdalina* extract treated rats.

Metronidazole caused significant decrease in testosterone levels. This could indicate that the drug inhibit the mechanism intervening in the process of hormone synthesis in the Leydig cells. Similar report was given by<sup>13</sup> in rats treated with *Aeglemermelos* extract.

Metronidazole caused significant decrease in sperm motility. This suggest that the drug was able to permeate the blood- testis barrier with a resultant alteration in the micro environment of the seminiferous tubules, since it has been reported that the decrease the in sperm motility caused by chemical agents was due to their ability to permeate the blood-testis barrier<sup>14</sup> and thus creating a different microenvironment in the inner part of the wall of the seminiferous tubules from the outer part<sup>15</sup>. Similar report was given by<sup>16</sup> in rats treated with *sarcotemmaacidum* extract.

There was an insignificant decrease in sperm viability as well as a significant increase in the percentage of morphologically abnormal sperm cells induced after treatment of rats with the drug. This could be due to the

ability of metronidazole to either interfere with the spermatogenic processes in the seminiferous tubules, epididymal functions or activities of testosterone on hypothalamic release factor and anterior pituitary secretion of gonadotropins which may result in alteration of spermatogenesis<sup>17,18</sup>. Similar result was reported by<sup>19</sup> in isolated tetracyclic steroid treated rats.

Sperm count is considered to be an important parameter with which to access the effect of chemicals on spermatogenesis<sup>20</sup>. Spermatogenesis is influenced by the hypothalamic adenohipophysial –Leydig cell system relating gonadotropin releasing hormone, luteinizing hormone and androgen. This implies that the decrease in sperm count caused by the drug in the treated rats might be as a result of decrease in plasma level of testosterone, because this hormone has been reported to be important in the initiation and maintenance of spermatogenesis<sup>21</sup>. Similar report was given by<sup>22</sup> in *Terminaliachebula* extract treated rats.

Photomicrographs of the metronidazole treated rats have revealed that the drug suppressed sperm production as evidenced by the mild erosion of germinal epithelia. This scanty germinal epithelium population may be due to insufficient amount of testosterone, since it has been reported that spermatogenesis is activated by testosterone which is synthesized by Leydig cells and act on Sertoli cells and peritubular cells<sup>23</sup>. Similar result was reported by<sup>24</sup> in *colebrookiaopositifolia* extract treated rats.

## CONCLUSION

In conclusion, this study has suggested that metronidazole has spermatotoxic or antispermatogenic effect in male rats.

However, its effect on human reproductive function are unknown.

Nevertheless, considering these findings in animal model, it is recommended that moderation should be exercised by those taking it for antibiotic purpose.

## REFERENCES

1. Dean H.J, Cornacoff BJ, Rosenthal JG, Luster I, Immune System: Evaluation of Injury, In; Hayes AW, Editor, Principles and Methods of Toxicology, New York: Raven Press, 1989.
2. El-Nahas AF, El-Ashmawy, Reproductive and cytogenetic toxicity of metronidazole in male mice, PharmacolToxicol, 5, 2004, 226-31.
3. Elizondo G, Montero R, Herrera JE, Hong E, Ostrosky-Wegman P, Lymphocyte proliferation kinetics and sister-chromatid exchanges in individuals treated with metronidazole, Mutat Res, 2,1994, 133-7.
4. Rustia M, Shubik P, Induction of lung tumors and malignant lymphomas in mice by metronidazole, J. Natl Cancer Inst, 48, 1972, 721-9.

5. Mitelman F, Levan G, Nilsson PG, Brandt L, Non - radomkaryotypic evolution in chronic myeloid leukemia, *Int J Cancer*, 18, 1976, 24-30.
6. Borden EB, Smartano RJ, Dembe C, Boley SJ, The effect of metrodanizole on wound healing in rats. *Surg*, 97, 1985, 331-6.
7. Oyedeji KO, Bolarinwa AF, Effect of metronidazole on hematological parameters in male albino rats, *IOSR J Dent Med Sci*, 3, 2013, 61-3.
8. Mohammad – Reza P, Farzaneh D, Taherch TK, Zoherb PP, The effects of hydroalcoholic extract of *Actinidiachinensis* sperm count and motility, and blood levels of estradiol and testosterone in male rats, *Achv Iranian Med*, 8, 2005, 211-6.
9. Laing JA, Fertility and infertility in domestic animals, 3<sup>rd</sup> edition Bailliere Tindall, a division of Cassell Lt, 1979.
10. Johnson MH, Everitt BJ, Essential reproduction Great Britain: BlackWell Scientific Publication, 1998.
11. Carvajal, Zarrabal O, Hayward Jone PM, Orta Flores Z, NolascoHipolito C, Effect of *Hibiscus sabdariffa l.* dried calyx Ethanol Extract on fat absorption, excretion and body weight implication in rats, *J Biomed Biotech*, 2009, 2009, 394592.
12. Oyedeji KO, Bolarinwa AF, and Azeez AA, Effect of effect of methanolic extract of *Vernoniaamygdalina* on reproductive parameters in male rats, *Asian J Pharm Clinic Res* 6, 2013, 1-4.
13. Das UK, De D, Chatterjee K, Mallick C, Bera TK, Ghosh D, Antigenadal effect induced by hydro-methanolic extract of leaf of *Aelglemermelos* in male rat: Effect of hcgc-administration, *J Med Plants Res*, 3, 2009, 728-35.
14. Baldessarini RJ, In drugs and the treatment of psychiatriod disorders. The pharmacological basis of therapeutics Ed, By Goodman and Gilman. Macmillan Pub.Co. Inc., 1980, 301-417.
15. Bloom W, Fawcett DW, Male reproductive system. In the textbook of Histology. Saunders Company, Philadelphia, 1975.
16. Verma PK, Sharma A, Annu M, Prachi S, Gupta RS, Joshi SC, Dixit VP, Effect of *Sarcostemmaacidum* stem extract on spermatogenesis in male albino rats, *Journal of andrology*, 4, 2002, 43-7.
17. William KW, Hormones and Hormone antagonists. In: Remington, The Science and Practise of Pharmacy, 11, 20th edition 77, 2000, 1390-1.
18. Bowman WC, Rand MJ, The reproductive system and drugs affecting the reproductive systems, Textbook of pharmacology, 2nd edition, 20, 1985, 1-8.
19. Oyedeji KO, Bolarinwa AF, Oladosu IA, Effect of isolated tetracyclic steroid constituent of *Portulacaoleracea* on reproductive parameters in male rats, *Asian Journal of Pharmaceutical and Clinical Research*, 6, 2013, 222-6.
20. Reddy PS, Pushpalatha T, Reddy PS, Reduction of spermatogenesis and steroidogenesis in mice after fentin and fenbutatin administration, *Toxicology Letter*, 166, 2006, 53–9.
21. Christensen AC, Leydig cell: In: Handbook of Physiology, edited by P.O. Greep and E.B. Astwoods, Washington D C, American Physiological Society, 1975.
22. Krishnamoorthy P, Vaithinathan S, Rani V, Bhuvanewari A, Effect of *Terminalia chebula* fruit extract on lipid peroxidation and antioxidative system of testis of albino rats, *African Journal of Biotechnology*, 6, 2007, 1888–91.
23. Sharpe RM, Testosterone and spermatogenesis, *Journal of Endocrinology*, 113, 1987, 1-2.
24. Gupta RS, Yadav R, Dixit VP, Dobhal MP, Antifertility studies of *Colebrookia oppositifolia* leaf extract in male rats with special reference to testicular cell population dynamics. *Fitoterapia*, 72, 2001, 236-45.

Source of Support: Nil, Conflict of Interest: None.

