

## Research Article



## Protective Role of Piperine and Metformin on Gentamicin Induced Hepatorenal Toxicity

Nazia Begum\*<sup>1</sup>, Vasudha Bakshi<sup>2</sup>, Vijayalaxmi A<sup>1</sup>, Devender Gaud P<sup>1</sup>, K Sunand<sup>1</sup>, K Sharath Kumar<sup>1</sup>, Sana<sup>3</sup>

<sup>1</sup>Dept of Pharmacology, School of Pharmacy, Anurag group of Institutions, Ghatkesar, Ranga Reddy Dist, Hyderabad, Telangana, India.

<sup>2</sup>Principal and Head of the Department, Dept. of Pharmacology, School of Pharmacy, Anurag group of Institutions, Hyderabad, India.

<sup>3</sup>Department of Clinical Pharmacy, School of Pharmacy, Anurag group of institutions, Hyderabad, Telangana, India.

\*Corresponding author's E-mail: [naziabegum2003@gmail.com](mailto:naziabegum2003@gmail.com)

Accepted on: 12-10-2015; Finalized on: 30-11-2015.

### ABSTRACT

Gentamicin is an aminoglycoside antibiotic commonly used for the treatment of severe Gram-negative bacterial infections. A major complication of Gentamicin treatment is nephrotoxicity and hepatotoxicity. Nephrotoxicity induced by Gentamicin is a complex phenomenon characterized by an increase in serum creatinine (Cr), blood urea nitrogen (BUN) concentration and severe proximal renal tubular necrosis, followed by deterioration and renal failure. Presently, the study investigated the effect of Piperine and Metformin alone and in combination in gentamicin induced renal and hepatotoxicity. Animals were divided into 6 groups of 6 each, Renal and Hepatotoxicity was induced in rats with Gentamicin 100 mg/kg i.p for 8 days and treatment groups received Piperine (50mg/kg and 100mg/kg), Metformin (100mg/kg) and Combination (Piperine 50mg/kg and Metformin 50mg/kg) for 8 days along with Gentamicin. At the end of the study serum Creatinine, Albumin, Blood Urea Nitrogen, Total Bilirubin, Triglycerides, Aspartate transaminase, Alanine transaminase, and Lactate dehydrogenase levels were measured. Administration of Piperine, Metformin and combination of piperine and metformin exhibited a significant decline in oxidative stress and lipid peroxidation levels in a dose dependent manner. BUN, Creatinine and TG levels were lowered. Similarly, LDH, Total bilirubin, ALT and AST were also attenuated in serum. Apart from biochemical parameters the administration of Piperine, Metformin and combination also showed significant improvement in architecture of liver and kidney under histopathological study. From this study, results suggest that the Piperine, Metformin and their combination proves beneficial in treating Gentamicin induced renal and hepatotoxicity.

**Keywords:** Renal toxicity, Hepatotoxicity, Piperine, Metformin, Gentamicin.

### INTRODUCTION

Aminoglycoside antibiotics are commonly used for the treatment of severe Gram-negative bacterial infections.<sup>1</sup> Perhaps the most widely used drug in this category is gentamicin (GEN).<sup>2</sup> A major complication of GEN treatment is nephrotoxicity, which accounts for 10-20% of all cases of acute renal failure (ARF) according to experimental results.<sup>3</sup> Although its exact role in kidney dysfunction is not apparent, it is suggested that the selective accumulation of gentamicin in kidney cortex can induce oxidative stress and cause lipid peroxidation. The toxicity of GEN seems to relate to the generation of destructive reactive oxygen species (ROS) in kidney cells.<sup>2,4</sup> Previous studies have revealed that ROS has been proposed as a causative agent of cell death in many different pathological states including glomerular disease and renal ischemia reperfusion injury.<sup>5-7</sup>

The main side effects of gentamicin include liver damage that is one of the major factors of liver inefficiency in a significant number of people taking this medication.<sup>8,9</sup>

Black pepper (*Piper nigrum*) is used as a medicine, a preservative, and a perfume. An extract of the active phenolic component, piperine, is well known to provide beneficial physiological effects.<sup>10</sup>

It stimulates the digestive enzymes of pancreas, protects against oxidative damage, lowers lipid peroxidation, and

enhances the bioavailability of a number of therapeutic drugs. In addition, its anti-inflammatory activities have been demonstrated in rat models of carrageenan-induced rat paw edema, cotton pellet-induced granuloma, and a croton oil-induced granuloma pouch.<sup>11</sup> Constituents of the piper species have shown *in vitro* inhibitory activity against the enzymes responsible for leukotriene and prostaglandin biosynthesis, 5-lipoxygenase and COX-1 respectively.<sup>12</sup>

Apart from superiorities of Metformin (MET) to other anti-diabetic drugs various investigations strongly suggests that this antidiabetic agent prevents oxidative stress induced death in several cell types through a mechanism dependent on the mitochondrial permeability transition pore (PTP) opening.<sup>3,14,15</sup> The present work was designed to study the effect of piperine and metformin alone and in combination in gentamicin induced hepatorenal toxicity.

### MATERIALS

#### Experimental animals

Male Wistar rats weighing 150-250g were used and were procured from National Center for Lab Animal Sciences, National Institution of Nutrition, Hyderabad, India. The rats were maintained at a stable temperature (22±2 °C) and humidity (55±5%) under a 12-h light/dark cycle and had free access to food and water. After seven days of



acclimatization period, they were randomly selected for different experimental groups.

All the experimental procedures were carried out in accordance with Committee for the Purpose of Control and Supervision of Experiments on Animal (CPCSEA) guidelines. All the experimental procedures were approved by the Institutional Animal Ethical Committee.

IAEC- I/IAEC/LCP/009/2014/WR-36 ♂

#### Chemicals and drugs:

- Piperine was procured from Sami labs, Bangalore, India.
- Metformin was procured from Disto Pharmaceuticals Pvt Ltd, Cherlapally, Hyderabad.
- Gentamicin was procured from Alpa Laboratories, Pigdamber, India.
- Hydrogen peroxide, 5,5'-dithios-bis-2-nitrobenzoic acid (DTNB) and Bovine serum albumin were purchased from Sigma Chemical Co., Saint Louis, MO USA.
- All other chemicals were ordered from sd fine chemicals.

## METHODS

### Experimental animal models and study design

In order to study the effect of piperine and metformin alone and in combination in hepatorenal toxicity, In the present study, Gentamicin induced renal and hepatotoxicity in male Wistar rats is used as an animal model.

#### Induction method

To induce Renal and Hepatotoxicity, rats were administered with Gentamicin 100 mg/kg i.p for 8 days.<sup>16</sup>

#### Experimental Study Design

Experimental animals are randomly divided into six groups of each six animals.

Group-I (Control): Animals given oral dose of 0.5% Na CMC and injected with normal saline.

Group-II (GEN): Animals injected with Gentamicin 100mg/kg, i.p.

Group-III (GEN + PP 50): Animals injected with Gentamicin(100mg/kg,i.p) and Piperine (50mg/kg, p.o.).

Group-IV (GEN + PP 100): Animals injected with Gentamicin(100mg/kg,i.p) and Piperine (100 mg/kg, p.o.).

Group-V (GEN+MET 100): Animals injected with Gentamicin(100mg/kg,i.p) and Metformin (100mg/kg,p.o).

Group-VI (GEN+MET 50+PP 50): Animals injected with Gentamicin (100mg/kg,i.p), Piperine(50mg/kg,p.o.) and Metformin(50mg/kg,p.o).

Group-I received 0.5% Na CMC and injected with normal saline i.p.. Group-II, III, IV,V &VI were injected with Gentamicin 100mg/kg i.p for 8 days. Group-III & IV received Piperine p.o. from 1<sup>st</sup> day to 8<sup>th</sup> day.

During the study, rats' body weights were measured daily. At the end of experimental period blood samples were collected from orbital plexus, and serum was collected for biochemical estimations. Then animals were sacrificed by cervical dislocation and kidney and liver were isolated for further histopathological studies.

#### Histopathology of tissues

Tissues fixed in 10% formalin and bouin's solution were dehydrated in 95% ethanol and then cleared in xylene before embedded in paraffin. Micro sections were prepared and stained with haematoxylin and eosin (H&E) dye, and were examined under a light microscope by a Histopathologist who was ignorant of the treatment groups.

#### Liver function tests

Analysis of serum was carried out for alanine transaminase (ALT), aspartate transaminase (AST), lactate dehydrogenase (LDH) and Total bilirubin with standard ERBA diagnostic kits.

#### Renal function tests

Level of blood urea nitrogen (BUN), creatinine, albumin and triglycerides in serum were determined by using standard ERBA diagnostic kit.

#### Antioxidant enzyme assays in hepatic and renal tissues

Hepatic and renal tissues were homogenized in 10 volume of phosphate buffer (100 mM) having EDTA (pH 7.4; 1 mM), centrifuged (12000 × g) at 4°C for 30 min. Supernatant was used to estimate the protein contents by using bovine serum albumin as standard.<sup>17</sup> Catalase was estimated by using hydrogen peroxide and ammonium molybdate as described by Aebi H, 1974 in liver and renal homogenates. In this experiment hydrogen peroxide was used as substrate for catalase activity. However, superoxide dismutase activity was determined according to the procedure described by Marklund and Marklund 1974.<sup>18,19</sup>

#### Estimation of Reduced glutathione (GSH) and lipid peroxidation (TBARS)

Hepatic and renal glutathione contents were determined according to the method described previously by using DTNB (5, 5-dithiobis-2-nitrobenzoic acid) as substrate. Level of lipid peroxidation in renal homogenates was determined according to the method described by Ohkawa using thiobarbituric acid as reacting substrate.

#### Statistical Analysis

All data are presented as Mean ± S.E.M. The significance of difference among the groups were assessed using one way analysis of variance (ANOVA) followed by Tukey's

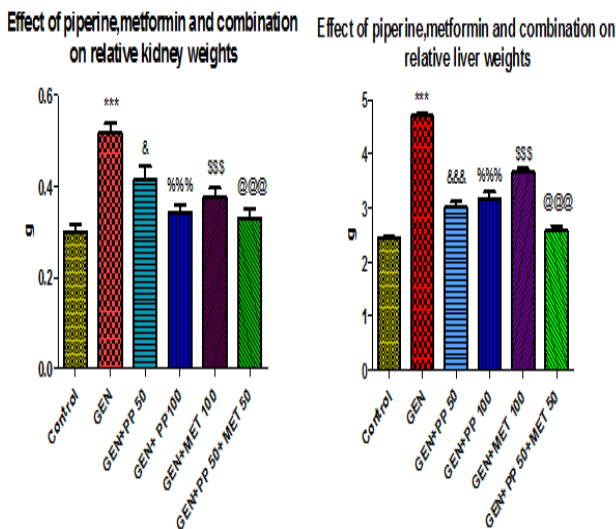


test using Graph pad PRISM software and  $p \leq 0.05$  was considered significant.

**RESULTS**

**Relative liver and kidney weight**

From the data in Fig 1, there was a significant increase ( $p < 0.001$ ) in relative kidney and liver weight in Gentamicin (GEN) group when compared to control group. Relative kidney and liver weights were significantly reduced in treatment groups.



**Figure 1:** Effect of piperine, metformin and combination on relative kidney and liver weights

Data are expressed as Mean  $\pm$  S.E.M

\*\*\*  $p < 0.001$  Control v/s GEN

&  $p < 0.05$  GEN v/s GEN+PP 50, &&&  $p < 0.001$  GEN v/s GEN+PP 50

%%  $p < 0.001$  GEN v/s GEN+PP 100

\$\$\$  $p < 0.001$  GEN v/s GEN+MET 100

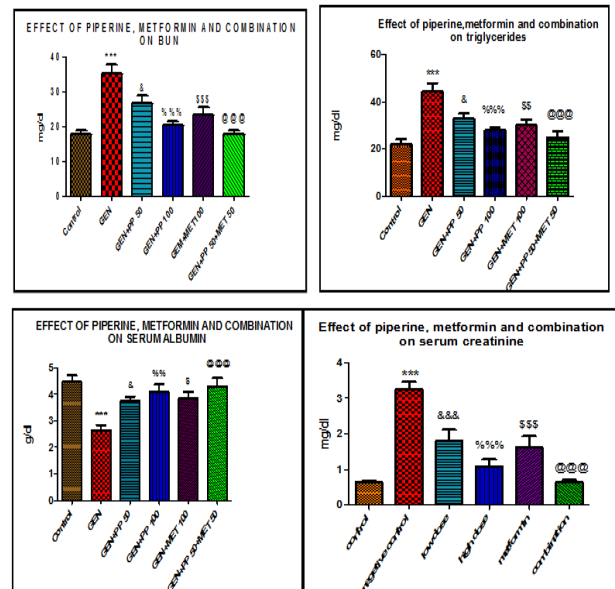
@@@  $p < 0.001$  GEN v/s GEN+PP 50+MET 50

**Effect of Piperine and Metformin on renal function tests**

Injection of gentamicin to rats for eight days significantly ( $p < 0.001$ ) decreased the serum levels of albumin while the level of triglycerides, BUN, Creatinine increased than that of control group (Fig 2). In addition, altered level of these parameters induced with gentamicin in serum was restored, with the simultaneous treatment with piperine (50mg and 100mg), metformin (100mg) and combination (Piperine and metformin) to different groups of rats.

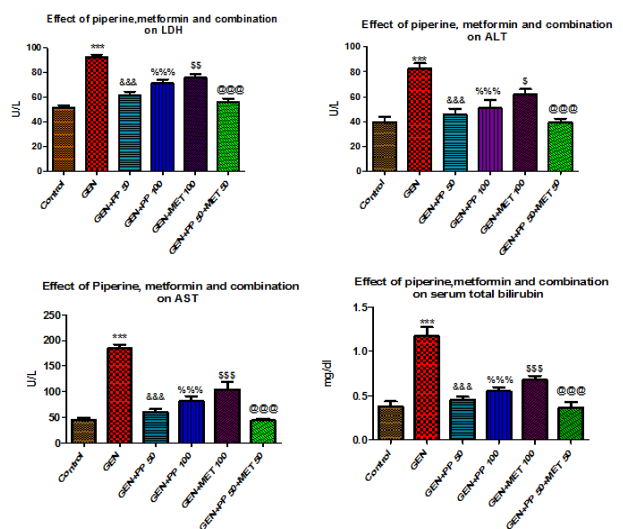
**Effect of Piperine and Metformin on Liver function tests**

Gentamicin increased the level of biochemical parameters; AST, ALT, LDH and Total bilirubin significantly ( $p < 0.001$ ) as compared to that of control group (fig 3). Treatment with Piperine (50mg and 100mg), Metformin (100mg) and combination of Metformin and Piperine to different groups along with gentamicin reduced the serum level of AST, ALT, LDH and Total bilirubin to that of the gentamicin treated group.



**Figure 2:** Effect of Piperine and Metformin on renal function tests

Data are expressed as Mean  $\pm$  S.E.M \*\*\*  $p < 0.001$  Control v/s GEN &  $p < 0.05$  GEN v/s GEN+PP 50, &&&  $p < 0.001$  GEN v/s GEN+PP 50 %%  $p < 0.01$  GEN v/s GEN+PP 100, %%%  $p < 0.001$  GEN v/s GEN+PP 100 \$  $p < 0.05$  GEN v/s GEN+MET 100, \$\$\$  $p < 0.001$  GEN v/s GEN+MET 100 @@@  $p < 0.001$  GEN v/s GEN+PP 50+MET 50



**Figure 3:** Effect of Piperine and Metformin on Liver function tests

Data are expressed as Mean  $\pm$  S.E.M \*\*\*  $p < 0.001$  Control v/s GEN &&&  $p < 0.001$  GEN v/s GEN+PP 50 %%%  $p < 0.001$  GEN v/s GEN+PP 100 \$  $p < 0.05$  GEN v/s GEN+MET 100, \$\$\$  $p < 0.001$  GEN v/s GEN+MET 100 @@@  $p < 0.001$  GEN v/s GEN+PP 50+MET 50

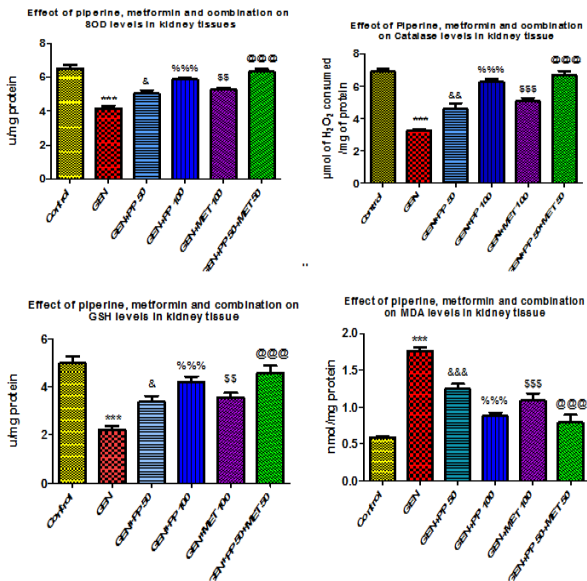
**Effect of Piperine and Metformin on hepatorenal antioxidant enzymes of rat**

Effect of gentamicin and gentamicin plus treatment (Piperine low and high dose/Metformin/Combination of Piperine and Metformin) on hepato-renal antioxidant defense system such as CAT, POD AND SOD is shown in fig. 4 and fig. 5. Administration of gentamicin significantly ( $p < 0.001$ ) decreased the activities of both hepatic and renal CAT, SOD and GSH where as it increased the level of



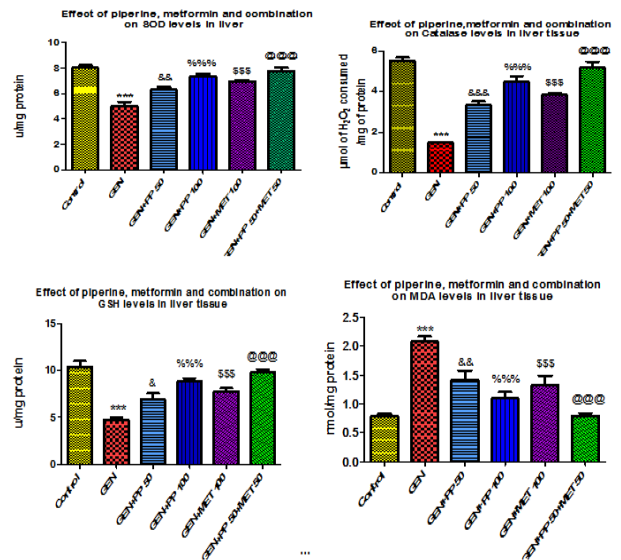


MDA as compared to control group. Treatment of Piperine in low and high dose, Metformin and Combination of both to different groups along with gentamicin increased the activity level of CAT, SOD and GSH and decreased the activity of MDA as compared to gentamicin group.



**Figure 4:** Effect of Piperine, Metformin and combination on SOD, Catalase, GSH and MDA levels in kidney tissue

Data are expressed as Mean ± S.E.M \*\*\*p<0.001 Control v/s GEN &p<0.05 GEN v/s GEN+PP 50, &&&p<0.001 GEN v/s GEN+PP 50 %%%p<0.001 GEN v/s GEN+PP 100 \$\$\$p<0.001 GEN v/s GEN+MET 100 @@@p<0.001 GEN v/s GEN+PP 50+MET 50

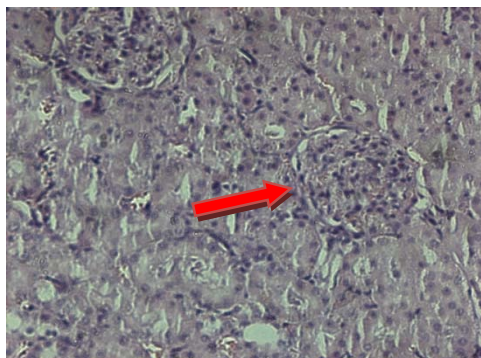


**Figure 5:** Effect of Piperine, Metformin and Combination on SOD, Catalase, GSH and MDA levels in Liver tissue

Data are expressed as Mean ± S.E.M \*\*\*p<0.001 Control v/s GEN &&&p<0.001 GEN v/s GEN+PP 50 %%%p<0.001 GEN v/s GEN+PP 100 \$p<0.05 GEN v/s GEN+MET 100, \$\$\$p<0.001 GEN v/s GEN+MET 100 @@@p<0.001 GEN v/s GEN+PP 50+MET 50

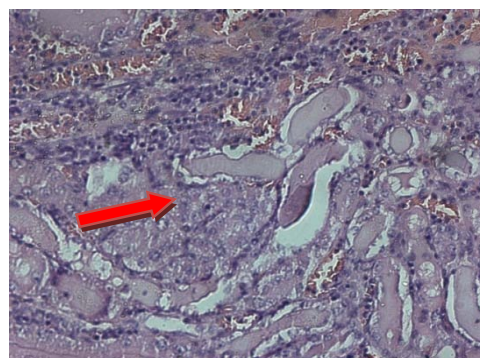
**Histological profile of kidney**

Histological profile of kidney from GEN group reveals moderate to severe tubular degeneration in tubular region of kidney. Mostly degeneration is vacuolar type and cystic degeneration types. Protective effect of treatment drugs was confirmed by histopathological examination of kidney section.



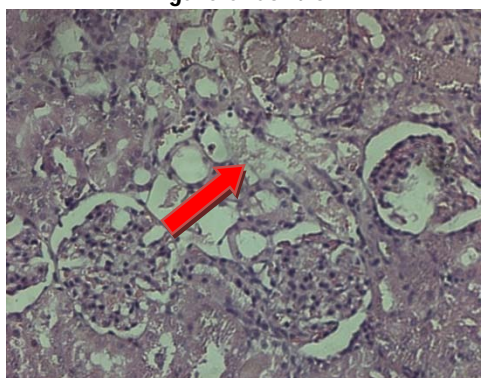
(Glomerulus appeared normal)

**Figure 6:** Control



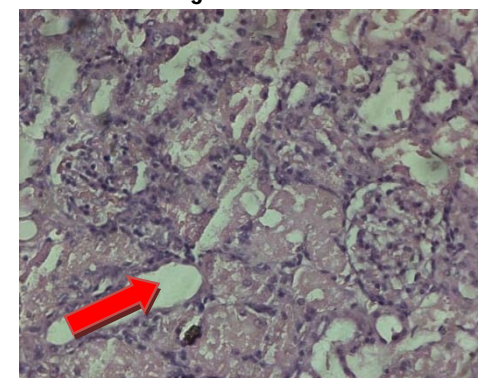
(Moderate to severe tubular degeneration)

**Figure 7:** GEN



(Mild to moderate tubular degeneration)

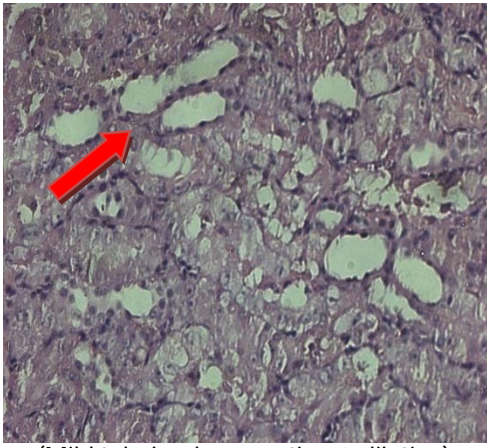
**Figure 8:** GEN+PP 50



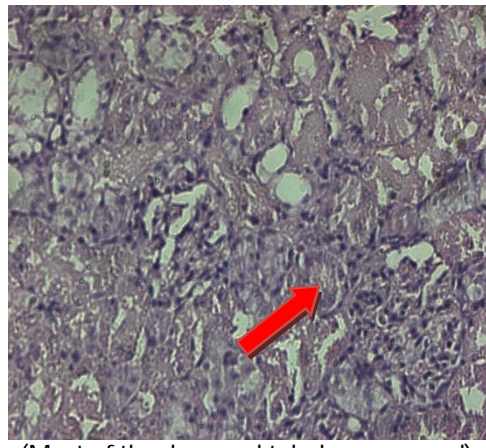
(Moderate tubular regeneration)

**Figure 9:** GEN+PP 100





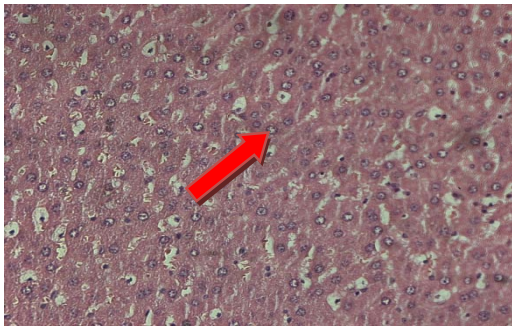
(Mild tubular degeneration & dilation)  
**Figure 10: GEN+MET 100**



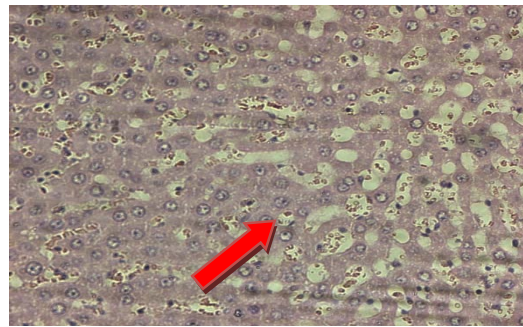
(Most of the damaged tubules recovered)  
**Figure 11: GEN+PP 50+MET 50**

### Histopathological profile of liver

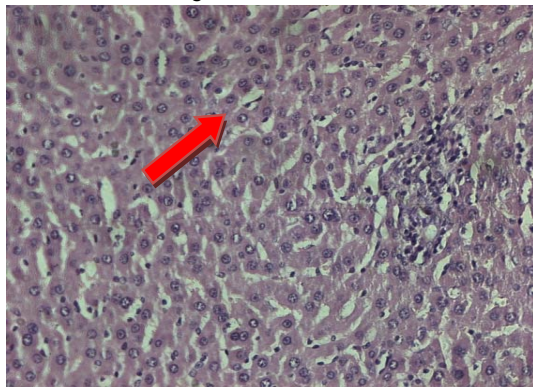
Histological profile of liver from GEN group reveals moderate to severe sinusoidal haemorrhages which may further lead to liver toxicity. Also dilatation of sinusoidal space was observed and no necrosis and inflammation was observed in the liver.



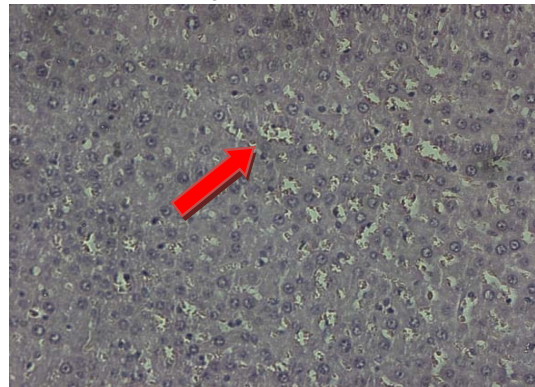
(Sinusoidal space appeared normal)  
**Figure 12: Control**



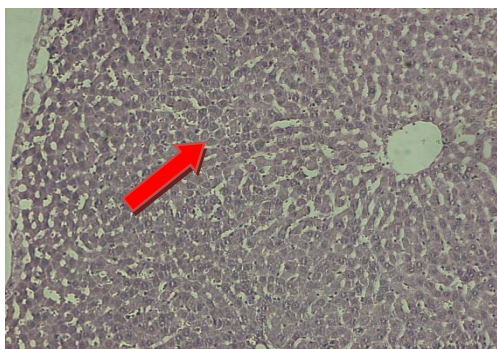
(Moderate to severe sinusoidal haemorrhage and sinusoidal dilatation)  
**Figure 13: GEN**



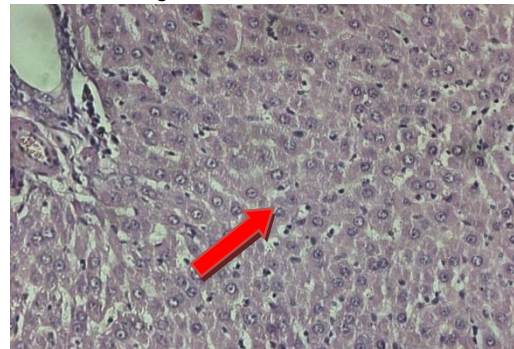
(Sinusoidal spaces appeared normal)  
**Figure 14: GEN+PP 50**



(Mild sinusoidal haemorrhage but mild foci of inflammation is seen)  
**Figure 15: GEN+PP 100**

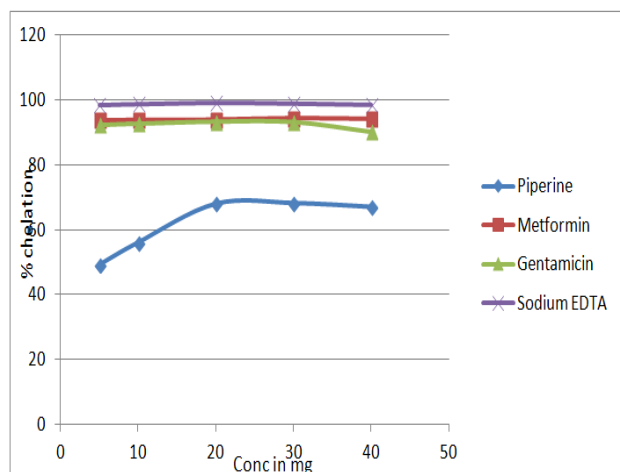


(Mild sinusoidal dilatation and sinusoidal haemorrhage)  
**Figure 16: GEN+MET 100**



(Sinusoidal space appeared normal)  
**Figure 17: GEN+PP 50+MET 50**

## Iron Chelation Assay



**Figure 18:** Percentage iron chelation by Piperine, Metformin, Gentamicin and sodium EDTA

The  $\text{Fe}^{2+}$  chelating ability of the Piperine was determined using a modified method described by Puntel 2005. Freshly prepared 2mM/L  $\text{FeSO}_4 \cdot 7\text{H}_2\text{O}$  (150 $\mu\text{l}$ ) was added to a reaction mixture containing 168 $\mu\text{l}$  of 0.1M Tris Hcl (pH 7.4), 218  $\mu\text{l}$  saline and the ethanolic solubilised piperine (10-100 $\mu\text{l}$ ). The reaction mixture was incubated for 5 min, before the addition of 13 $\mu\text{l}$  of 0.25% 1, 10-phenanthroline (w/v). The absorbance was subsequently measured at 510nm in a spectrophotometer.

Formula:

Chelating ability (%) =  $(A_{\text{control}} - A_{\text{sample}}) / A_{\text{control}} \times 100$

Where,

A control = the absorbance of the control (reaction mixture in the absence of sample) ( $\text{FeSO}_4$  alone).

A sample = the absorbance of the reaction mixture (sample,  $\text{FeSO}_4$  and 1, 10-phenanthroline)

## DISCUSSION

Gentamicin is an aminoglycoside antibiotics which is commonly used for the treatment of severe Gram-negative bacterial infections.<sup>1</sup>

A major complication of GEN treatment is nephrotoxicity and hepatotoxicity.<sup>3,8,9</sup> Increased production of Reactive Oxygen Species (ROS), which can be seen after the use of gentamicin, is effective in inducing toxic impacts of this drug on the structure and function of tissues.<sup>20,21</sup>

In the present study, the animals were injected with Gentamicin 100mg/kg i.p. for 8 days to induce renal and hepatotoxicity and we investigated whether oral administration of Piperine (in low and high dose), Metformin and their combination could show protective effect on Gentamicin induced renal and hepatotoxicity. In the study, results showed a remarkable kidney and liver damage compared to GEN group.

Results showed significant increase in the relative weights of kidney and liver when compared to GEN group, where as treatment with Piperine, Metformin and combination of both resulted in decrease in relative kidney and liver weights showning that the given treatment have activity against kidney and liver toxicity.

Studies associated with Gentamicin causes kidney toxicity and hence serum creatinine, albumin, BUN and triglyceride levels were measured on the 8<sup>th</sup> day. Results showed significant increase in the levels of above parameters in GEN group, where as treatment with Piperine, Metformin and combination of both resulted in decrease in levels of creatinine, albumin, BUN and triglyceride showing that the given treatments have activity against kidney toxicity.

Also studies associated with gentamicin causes hepatotoxicity and hence serum ALT, AST, Total bilirubin and LDH levels measured at the end of the study. Results suggest significant increase in ALT, AST, Total bilirubin and LDH levels in GEN group. Whereas the above parameters were decreased significantly in treatment groups (Piperine, Metformin and Combination).<sup>8,9</sup>

Selective accumulation of Gentamicin in kidney cortex and liver can induce oxidative stress and cause lipid peroxidation.<sup>6</sup>

Gentamicin have higher iron chelating property, Metformin has almost similar iron chelating property as that of Gentamicin where as Piperine have less iron chelating property. As potent iron chelation may lead to kidney and liver damage Piperine shows better therapeutic results compared with Metformin.<sup>22</sup>

Gentamicin damages liver and kidney tissues, it is clear from histopathological results that the architecture of liver and kidney tissues was improved in treatment groups compared to GEN group.

## CONCLUSION

The results of the present investigation indicated that Piperine can be beneficial in both liver and kidney toxicity. Metformin also showed beneficial effects but it is less effective compared to Piperine.

Combination of Piperine and Metformin at a dose of 50mg/kg each showed better results compared with Piperine alone in both kidney and liver toxicity.

Further studies are essential to find out exact mechanism underlying its action.

## REFERENCES

1. Parlakpınar H, Tasdemir S, Polat A. Protective role of caffeic acid phenethyl ester (CAPE) on gentamicin-induced acute renal toxicity in rats. *Toxicology*, 207, 2004, 169-77.
2. Reiter RJ, Tan DX, Sainz RM, Mayo JC, Lopez-Burillo S. Melatonin: reducing the toxicity and increasing the efficacy of drugs. *J Pharm Pharmacol*, 54, 2002, 1299-321.





3. Erdem A, Gundogan NU, Usbutun A, Kilinc K, Erdem SR, Kara A. The protective effect of taurine against gentamicin-induced acute tubular necrosis in rats. *Nephrol Dial Transplant*, 15, 2000, 1175–82.
4. Al-Majed AA, Mostafa AM, Al-Rikabi AC, Al-Shabanah OA. Protective effects of oral arabic gum administration on gentamicin-induced nephrotoxicity in rats. *Pharmacol Res*, 46, 2002, 445–51.
5. Mizrak B, Parlakpınar H, Acet A, Turkoz Y. Effects of pinealectomy and exogenous melatonin on rat hearts. *Acta Histochem*, 106, 2004, 29–36.
6. Cuzzocrea S, Mazzon E, Dugo L, Serraino I, Paola RD, Britti D, Sarro DeA, Pierpaoli S, Caputi AP, Masini E, Salvemini D: A role for superoxide in gentamicin-mediated nephropathy in rats. *Eur J Pharmacol*, 450, 2002, 67-76.
7. Sahna E, Parlakpınar H, Ozturk F, Cigremis Y, Acet A. The protective effects of physiological and pharmacological concentrations of melatonin on renal ischemiareperfusion injury in rats. *Urol Res*, 31, 2003, 188–93.
8. Masakazu K, Yoshiko E, Masashi E., Acquired resistance of *Listeria monocytogenes* in and escaped from liver parenchymal cells to gentamicin is caused by being coated with their plasma membrane. *Microbes and Infection*, 16(3), 2014, 237-243.
9. Stojiljkovic N, Stojiljkovic M., Micromorphological and histochemical characteristics of a rat's liver treated with gentamicin. *Acta medica Medianae*, 45(3), 2006, 24-28.
10. Srinivasan K: Black pepper and its pungent principle-piperine: a review of diverse physiological effects. *Crit Rev Food Sci Nutr*, 47, 200, 735-748.
11. Mujumdar AM, Dhuley JN, Deshmukh VK, Raman PH, Naik SR: Anti-inflammatory activity of piperine. *Jpn J Med Sci Biol*, 43, 1990, 95-100.
12. Stohr JR, Xiao PG, Bauer R: Constituents of Chinese Piper species and their inhibitory activity on prostaglandin and leukotriene biosynthesis *in vitro*. *J Ethnopharmacol*, 75, 2001, 133-139.
13. Kirpichnikov D, McFarlane SI, Sowers JR. Metformin: An update. *Ann Intern Med*, 137, 2002, 25-33.
14. El-Kaissi S, Sherbeeni S. Pharmacological management of type 2 diabetes mellitus: An update. *Curr Diabetes Rev* 7, 2011, 392-405.
15. Owen MR, Doran E, Halestrap AP. Evidence that metformin exerts its anti-diabetic effects through inhibition of complex 1 of the mitochondrial respiratory chain. *Biochem J*, 348, 2000, 607-14.
16. E.O.Farombi, M.Ekor. Curcumin attenuates gentamicin-induced renal oxidative damage in rats. *Food and Chemical Toxicology*. Volume 44, Issue 9, 2006, 1443-1448.
17. Lowry O.H, Rosenbrough N.J, Farr A.L, Randall R.J. Protein measurement with folin phenol reagent. *The Journal of Biological Chemistry*, 193, 1951, 265-275.
18. Aebi, H. Catalase: Methods of Enzymatic Analysis. *Academic Press, New York*, 2, 1974, 673-678.
19. Marklund S., Marklund G. Involvement of the superoxide anion radical in the autoxidation of pyrogallol and a convenient assay for superoxide dismutase. *European Journal of Biochemistry*, 47, 1974, 469-74.
20. Wojciech L, Vincent LP. Ternary Complexes of Gentamicin with Iron and Lipid Catalyze Formation of Reactive Oxygen Species. *Chemical Research in Toxicology*, 18(12), 2005, 357-364.
21. Jeffrey WC, Roger GU, Philip GL, Clay TC. Acute Hepatocellular Effects of Erythromycin, Gentamicin, and Trospectomycin in the Perfused Rat Liver: Lack of Correlation between Lamellar Body Induction Potency and Cytotoxicity. *Pharmacology & Toxicology*, 62(5), 1988, 337-343.
22. Priuska EM, Schacht J: Formation of free radicals by gentamicin and iron and evidence for an iron/gentamicin complex. *Biochem Pharmacol*, 50, 1995, 1749-1752.

Source of Support: Nil, Conflict of Interest: None.

