



Optic Disc Boundary Approximation Using Elliptical Template Matching

P. Nagarajan^{a*}, S.S. Vinsley^b

^aResearch Scholar, Anna University, Chennai, Tamil Nadu, India.

^bPrincipal, Lourdes Mount College of Engineering & Technology, Kanyakumari, Tamil Nadu, India.

*Corresponding author's E-mail: mpp.nagarajan@rediffmail.com

Accepted on: 20-06-2016; Finalized on: 31-07-2016.

ABSTRACT

Optic Disc (OD) is considered as one of the main features of a retinal fundus image. Segmenting the OD is a key pre-processing element in many algorithms designed for automatic extraction of anatomical structures. Information about the OD can be used to examine the severity of some diseases such as glaucoma, proliferative diabetic retinopathy, disc edema, etc. An elliptical template based methodology is proposed for the segmentation of optic disc. The detection procedure comprises of two independent methodologies namely optic disc detection and boundary approximation. To improve the accuracy of Optic Disc detection, the candidate regions are first determined by clustering the brightest pixels in red plane of the fundus image. Different image contrast analysis methods are applied within that candidate region to locate the optic disc. Sub image having the optic disc can be separated for boundary detection using histogram. Boundary detection methodology estimates an elliptical approximation of the OD boundary by applying mathematical morphology, edge detection techniques and circular Hough transform along with circular template. Due to the exceptional ellipticity degree of the optic disc, elliptical template is proposed to increase the overlapping rate from 86% achieved with a circular template matching to 95%.

Keywords: Fundus image, Optic Disc, Segmentation, boundary detection, Hough transforms, Template Matching.

INTRODUCTION

Eye is an organ associated with vision that sends a huge amount of information to the brain. The eye is shaped like a ball, with a slight bulge at the front. Eye has three layers namely sclera, choroid and retina. The retina is the innermost layer of the eyeball. It is a soft, transparent layer of nervous tissue made up of millions of light receptors. This is the place where the image created by the lens is focused and transformed in nerve impulses which are then sent to the brain via the optic nerve. The optic disc or optic nerve head is the location where ganglion cell axons exit the eye to form the optic nerve¹. There are no light sensitive rods or cones to respond to a light stimulus at this point. This causes a break in the visual field called "the blind spot". There are many diseases that can affect this part of the eye. The patterns of disease that affect the fundus of the eye provide vital information about the health of the sensory part of the visual system. Optic disc detection is an important step in developing systems for automated diagnosis of various serious ophthalmic pathologies.

Reliable and efficient optic disc localization and segmentation are important tasks in automated retinal screening because of the following reasons. Information about the OD can be used to examine the severity of some diseases such as glaucoma, proliferative diabetic retinopathy, disc edema etc. It is often needed to mask the OD out for bright lesion detection because of its similarity in brightness and color in a diseased retina. This improves the classification of exudates regions. The identification of the position and the shape of the optic

disc in the retinal image are very important for the diagnosis of the eyeball's diseases like optic atrophy, optic neuritis, papilledema, ischemic optic neuropathy, glaucoma and for more general diseases of the human body (diabetes, arterial hypertension, etc.). Over and above that the optic disc and the vessels can be considered as landmarks of the fundus images, which may be used afterwards for image registration of images.

The traditional method of optic disc boundary detection method includes detection of optic disc based on vessel tracking, highest gray level of pixel value and the area with highest variance and boundary detection of optic disc based on contour method and circular template method.

This method presents a new elliptical template based methodology for OD segmentation. First, an optic disc localization methodology is proposed to locate the optic disc. Then OD segmentation is carried out by using edge detection technique followed by using circular Hough transform and circular template matching and finally followed by using circular Hough transform and elliptical template matching. The results show that the elliptical template matching provide better overlapping rate.

Literature Survey

Akita² proposed a computer method of understanding ocular fundus images. Since a retinal blood vessel comes from the disc, they define the parent-child relationship between line segments at branch points. Tolia³ proposed an unsupervised fuzzy vessel tracking algorithm for retinal images. They presented an algorithm for vessel tracking.



The OD location is based on the hypothesis that the OD is a bright region located either in the left center or right center of the fundus image. Fuzzy Convergence is used by Hoover and Goldbaum⁴. They used convergence of blood vessels and voting type method to automatically locate the optic nerve. Sinthanayothin⁵ located optic disc by considering that it has higher intensity variation of adjacent pixels. Mendels⁶ identified the boundary of the optic disc using active contours. Gagnon⁷ found methods to detect anatomical structures in the fundus image. Here optic disc localization is done using pyramidal decomposition. Detection of the optic disc and the vascular tree is done by Walter⁸ using morphological techniques. To locate the optic disc Li and Chutatape⁹ used clustering and PCA to locate the optic disc exactly. Osareh¹⁰ proposed a method to locate the optic disc using gray level morphology followed by snake fitting. But this method fails if the retina has high severity of retinal exudates. Li and chutatape¹¹ proposed a method to detect the boundary of the optic disc using parametric deformable model. All retinal vessels originate from the OD and their path follows a similar pattern. So Foracchia¹² detected optic disc by means of geometrical model of vessel structure. Optic disc segmentation was done by Lowell¹³ using deformable contour model. But this method is sensitive to poor initialization. Youssif¹⁴ proposed a method to locate the optic disc. The OD detection algorithm is based on matching the expected directional pattern of the retinal blood vessels. To segment the optic disc and cup from the optic disc Wong¹⁵ used variable level set approach to segment the optic disc. To detect the disc location, histogram of the fundus image is obtained and higher intensity disc regions are selected. This method is complicated and computationally expensive. Alina Lupascu¹⁶ proposed texture descriptors and a regression based method to determine the best circle that fits the optic disc. By using convergence of thicker blood vessels Ravishankar¹⁷ located the optic disc. This approach is combined with the high intensity property of disc regions as a cost function to improve the robustness of optic disc detection. Aquino¹⁹ proposed a method to detect the boundary of the optic disc using morphological and edge detection technique. Circular Hough Transform along with edge detection technique is used to detect the boundary of the optic disc.

Elliptical Approximation

Image segmentation is one of the most important concerns in digital image processing. Image segmentation is a process of partitioning image pixels based on one or more selected image features. Optic disc is one of the main components on retinal fundus. It is an indicator of various ophthalmic pathologies. Therefore a reliable and efficient localization and boundary detection of the optic disc is necessary.

Optic Disc Localization

In order to find the boundary of optic disc, it should be located first. The following steps are used to locate the optic disc.

1. Clustering is done in the red plane and the brighter cluster is selected for image contrast analysis.
2. Green plane of the fundus image is chosen to apply image contrast analysis.
3. Three image contrast analyses namely Maximum Difference, Maximum Variance, and Gaussian Low Pass filtering methods are applied to the brightest cluster of the green plane to locate the optic disc and the three corresponding pixels are denoted as Optic disc candidate pixels.
4. With center as three candidate pixels, three sub images are selected.
5. Sub image having the optic disc is finally selected with the help of histogram.
6. Final sub image selected is the sub image having larger number of brighter pixels in the blue plane of the retinal fundus image since the blue plane is affected less by the ophthalmic pathologies and capturing effect.

Optic Disc Segmentation

Segmenting the OD is a key preprocessing element in many algorithms designed for automatic anatomical structures extraction and retinal lesions detection.

The OD boundary segmentation methodology is performed on a red component of the sub-image of the original retinography extracted using a pixel located within the OD as the central point.

The coordinates of this pixel have to be provided, by means of any OD location methodology. Optic disc boundary detection is performed by three methods.

The first method is boundary detection using edge detection technique.

This method works well and has higher overlapping rate. Overlapping rate or overlapping score is defined to measure the common area between a true Optic disc region T and a detected optic disc region D.

$$S = \frac{Area(T \cap D)}{Area(T \cup D)} \quad (1)$$

But if there are exudates near to the optic disc, it will consider that too as optic disc boundary. To overcome this disadvantage circular Hough transform along with circular template matching is used. This method considers only the optic disc and all the exudates are discarded, but it has lower overlapping area. Optic disc may be circular or vertically ellipse [5]. So to increase the overlapping rate elliptical template matching is used.

Boundary Detection using Edge Detection Techniques

The following operations are applied in sequential order on the red field of the sub-image to detect the boundary using edge detection technique.

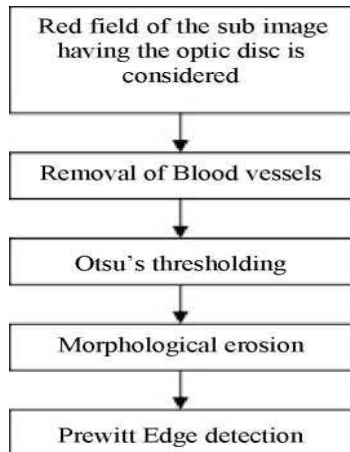


Figure 1: Overview of Optic Disc Boundary Detection

Removal of Blood Vessels

Blood vessels act as a major distracter for optic disc boundary detection.

Hence blood vessels have to be removed before detecting its boundaries. Classical morphological dilation operation and a mean filter for smoothing are employed to eliminate blood vessels.

The dilation operation uses a structuring element for probing and expanding the shapes contained in the sub image.

$$A \oplus B = \{Z | ((\hat{B})_z \cap A \neq \phi)\} \tag{2}$$

Where, A is the input image, B is the structuring element.

The mean filter is a simple sliding-window spatial filter that replaces the center value in the window with the average of all the pixel values in the window.

$$I[i, j] = \frac{1}{M} \sum_{(k,l) \in N} f(k, l) \tag{3}$$

Where, $f(k, l)$ is the window from the input image.

M is the no. of pixels present in the window.

The mean filter smoothes the image, thus the noise is eliminated.

This filter performs spatial filtering on each individual pixel in an image using the gray level values in a square or rectangular window surrounding each pixel.

Obtaining OD Boundary Candidate

Thresholding is the simplest method of image segmentation. From a grayscale image, thresholding can be used to create binary images. Automatic Otsu's thresholding method is performed. The resultant image is

the binary image. If the pixel value is greater than the threshold value, it will be considered as white pixel in the binary image. Otherwise the value is declared as black in the binary image.

$$I_b(i, j) = \begin{cases} 0, & \text{if } I(i, j) \geq T \\ 1, & \text{if } I(i, j) < T \end{cases} \tag{4}$$

Where,

$I_b(i, j)$ is the resultant binary image.

$I(i, j)$ is the blood vessel removed image.

T is the threshold level

Then, morphological erosion is applied. In erosion, every object pixel touching a background pixel is changed into a background pixel. Erosion makes the objects smaller and thus it removes small bright lesions surrounding the optic disc in case of affected retinal fundus images.

$$A \ominus B = \{Z | ((\hat{B})_z \subseteq A)\} \tag{5}$$

Final OD Boundary Detection using Edge Detection

Edge detection is a fundamental tool in image processing in the areas of feature detection and feature extraction. The Prewitt operator is used to obtain a gradient magnitude image. This operator estimates image edge and orientation by convolving two 3x3 kernels which approximate derivatives for horizontal and vertical changes. This method increases the overlapping rate of detecting the boundary of optic disc, but it will consider the boundaries of exudates also as optic disc boundary.

Boundary Detection using circular Hough transform and circular template matching

The Hough transform is a feature extraction technique used in image analysis, computer vision, and digital image processing. The purpose of the technique is to find imperfect instances of objects within a certain class of shapes by a voting procedure. This voting procedure is carried out in a parameter space. Circular Hough Transform aims to find circular patterns within the binary image and each pixel in the image space corresponds to a circle in Hough space. A circumference pattern is defined by the parametric equation of the circumference.

$$(x - a)^2 + (y - b)^2 = r^2 \tag{6}$$

where (a, b) are the coordinates of the circle center.

r is the radius.

The circular shapes present in the sub image can be written as

$$(P_c, r) = CHT(I_E, r_{min}, r_{max}) \tag{7}$$

where CHT denotes Circular Hough Transform.

r is the radius restricted between r_{\min} and r_{\max} .

I_{ε} is the edge detected binary image.

The following steps are used to fit circle around the optic disc

1. Removal of blood vessel is done by using morphological dilation and median filtering.
2. Otsu's thresholding is applied to the median filtered image.
3. Morphological erosion is then applied.
4. Create an accumulator array with the first two dimensions representing the coordinates of the circle origin and the third dimension represents the radii.
5. Detect edges of morphologically eroded image using the Prewitt edge detector.
6. For each edge pixel, increment the corresponding elements in the accumulator array.
7. Convert the gray scale accumulator array into binary image
8. Construct circles with various radiuses and match it against the binary accumulator array image.
9. The circle which correctly matches is considered as the circular boundary of the optic disc.

Boundary Detection using circular Hough transform and elliptical template matching

Optic disc may be circular or vertically ellipse. If optic disc is circular, circular template matching provides better result. But in some cases optic disc may be elliptical, so elliptical template is used instead of circular template to increase the overlapping area.

To find the better ellipse fit into the optic disc, first the circle that fit into the optic disc has to be found out. Circle can be changed to vertical ellipse by extending the circle height in y direction or decreasing the circle width in x direction. This made to match against the binary accumulator array and finally the ellipse which correctly fits into the accumulator array is selected as the elliptical boundary of the optic disc.

RESULTS AND DISCUSSION

The proposed method is tested by using the MESSIDOR database¹⁸.

This database is publicly available kindly provided by the Messidor program partners.

Totally there are 1200 images of color eye fundus. 800 of them are captured with pupil dilation and 400 without dilation using Topcon TRC NW6 nonmyriadic retinograph with a 45° FOV. The images are 1440 X 960, 2240 X 1488, or 2304 X 1536 pixels in size and 8 bits per color plane and are provided in TIFF format. The

proposed algorithm was simulated in a MATLAB environment.

Fig. 2 shows the retinal fundus image which is affected by exudates. In this image the exudates are brighter than optic disc.

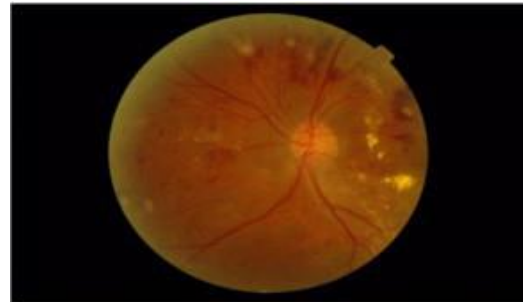


Figure 2: Affected Retinal Fundus Image

Fig.3 shows the location of optic disc based on three methods. Red dot, green dot and blue dot denotes the location based on maximum difference method, maximum variance method, and low pass filtering method respectively.

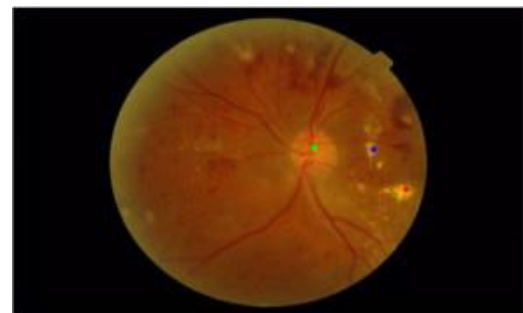


Figure 3: Optic Disc located by three methods

These red, green and blue dots are optic disc candidate pixels. With center as optic disc candidate pixel, three sub images are separated. The size of each sub image is 501 X 501. The sub image having the optic disc is selected by considering the larger number of brighter pixels. Selected sub image is further used for optic disc boundary detection as shown in Fig.4.

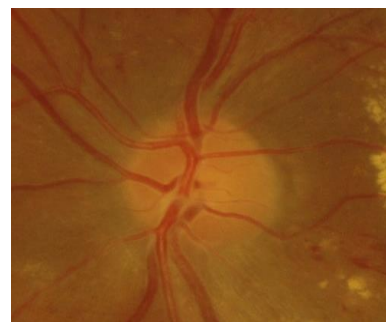

Figure 4: Sub image selected for OD Boundary Detection

Fig.5. show the boundary detection using edge detection technique. Here the boundary is distracted by optic nerve and it also considers the boundary of exudates too.

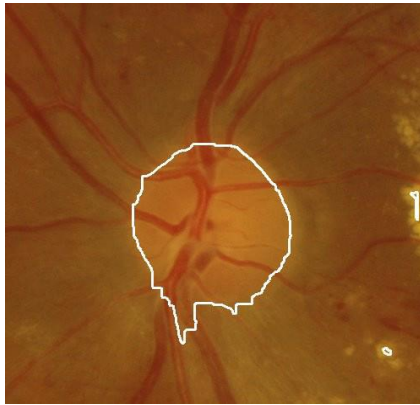

Figure 5: OD Boundary Detection using Edge Detection Technique

Fig.6. show the boundary detection of optic disc using circular template. Here the optic disc is considered as circular. This method discard exudates boundary but overlapping rate is less. To increase it, an elliptical template is used.

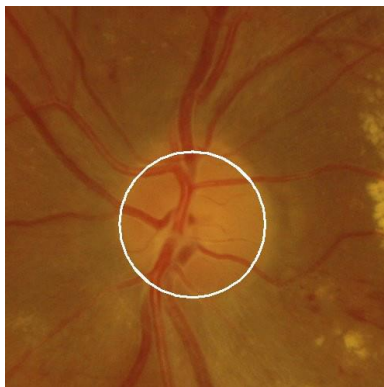

Figure 6: Optic Boundary detection using circular template matching

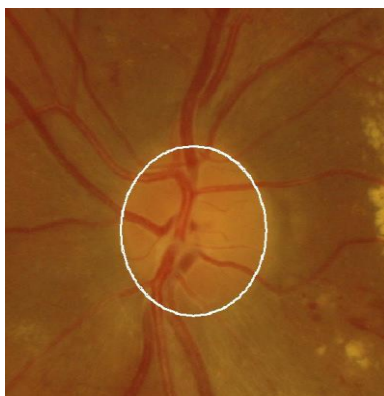

Figure 7: Optic Boundary detection using Elliptical Template Matching

Fig.7. show the boundary detection of optic disc using elliptical template. This method increases the overlapping rate. The size and shape of the optic disc varies from one person to another. It may be circular or vertically ellipse. Here circular template matching is followed by an

elliptical template matching i.e. if the optic disc is circular, then circular boundary will be detected and if the optic disc is elliptical, then elliptical boundary will be drawn around the optic disc.

Table 1: Comparison of Overlapping Rate

Models	Overlapping rate
Circular template model	86 %
Elliptical template model	95%

CONCLUSION

Localization and boundary detection of optic disc in the retinal fundus images have been presented in this paper. For optic disc localization clustering is done first in the red plane of fundus image. Because of higher contrast available in green plane, maximum difference, maximum variance, and Gaussian low pass filtering methods are applied in the green plane of the candidate region to find out the position of the optic disc.

Blue plane is affected less by the ophthalmic pathologies and capturing defect, hence histogram is taken in the blue plane for each sub image separated from the original image. To locate the optic disc accurately at the center, smaller window is chosen within the sub image. After optic disc localization, boundary detection of optic disc is done using circular and elliptical template matching.

This template matching method provides efficient optic disc localization and increases overlapping area for boundary detection (TABLE I). This work can be further extended with glaucoma and exudates detection.

Acknowledgement: The authors would like to thank the MESSIDOR program partners for granting permission to use their database.

REFERENCES

1. Duane’s Ophthalmology Ch. 4 Anatomy of the Visual Sensory System, 2006.
2. Akita K, Kuga H. A computer method of understanding ocular fundus images, Pattern recognition, 15, 1982, 431-443. DOI: 10.1016/0031-3203(82)90022-x.
3. Tolia YA, Panas SM. An unsupervised fuzzy vessel tracking algorithm for retinal images, Proceedings of the Sixth IEEE International Conference on Fuzzy Systems, 1, 1997, 325-329. DOI:10.1109/FUZZY.1997.616389.
4. Hoover A, Goldbaum M. Fuzzy convergence, Japanese Journal of Ophthalmology, 1998, 716-721. DOI: 10.1109/CVPR.1998.698682.
5. Sinthanayothin C, Boyce JF, Cook HL, Williamson TH. Automated localisation of the optic disc, fovea, and retinal blood vessels from digital colour fundus images, British Journal of Ophthalmology, 83, 1999, 902-910. DOI:10.1136/bjo.83.8.902.
6. Mendels F, Heneghan, C, Thiran, J. Identification of the optic disk boundary in retinal images using active contours, In Proceedings of Irish Machine Vision and Image Processing Conference, 1999, 103-115.

7. Gagnon L, Lalonde M, Beaulieu M, Boucher MC. Procedure to Detect Anatomical Structures in Optical Fundus Images, International Society for Optics and Photonics in Medical Imaging, 2001, 1218-1225. DOI:10.1117/12.430999.
8. Walter T, Klein JC. Segmentation of color fundus images of the human retina: Detection of the optic disc and the vascular tree using morphological techniques, In International Symposium on Medical Data Analysis, 2001, 282-287. DOI: 10.1007/3-540-45497-7_43.
9. Li H, Chutatape O. Automatic location of optic disk in retinal images, IEEE International Conference on Image Processing, 2, 837-840. DOI:10.1109/ICIP.2001.958624.
10. Osareh A, Mirmehdi M, Thomas B, Markham R. Comparison of colour spaces for optic disc localisation in retinal images, Proceedings 16th International Conference on Pattern Recognition, 1, 2002, 743-746. DOI: 10.1109/ICPR.2002.1044865.
11. Li H, Chutatape O. A model-based approach for automated feature extraction in fundus images, Ninth IEEE International Conference on Computer Vision, 2003, 394-399. DOI:10.1109/ICCV.2003.1238371.
12. Foracchia M, Grisan E, Ruggeri A. Detection of optic disc in retinal images by means of a geometrical model of vessel structure, IEEE transactions on medical imaging, 23, 2004, 1189-1195. DOI: 10.1109/TMI.2004.829331.
13. Lowell J, Hunter A, Steel D, Basu A, Ryder R, Fletcher E, Kennedy L. Optic nerve head segmentation, IEEE Transactions on medical Imaging, 23, 2004, 256-264. DOI:10.1109/TMI.2003.823261.
14. Mallat SG, A theory for multiresolution signal decomposition: the wavelet representation, IEEE transactions on pattern analysis and machine intelligence, 11, 1989, 674-693. DOI:10.1109/34.192463.
15. Wong DWK, Liu J, Lim JH, Jia X, Yin F, Li H, Wong TY. Level-set based automatic cup-to-disc ratio determination using retinal fundus images in ARGALI, Annual International Conference of IEEE Engineering in Medicine and Biology Society, 2008, 2266-2269. DOI: 10.1109/IEMBS.2008.4649648.
16. Lupascu CA, Tegolo D, Di Rosa L. Automated detection of optic disc location in retinal images, IEEE International Symposium on Computer-Based Medical Systems, 2008, 17-22. DOI: 10.1109/CBMS.2008.15.
17. Ravishankar S, Jain A, Mittal A. Automated feature extraction for early detection of diabetic retinopathy in fundus images, IEEE Conference on Computer Vision and Pattern Recognition, 2009, 210-217. DOI: 10.1109/CVPR.2009.5206763.
18. Download Images Section, M ESSIDOR: Digital Retinal Images, MESSIDOR TECHNO-VISION Project, France, [Online]. Available: <http://messidor.crihan.fr/download-en.php>.
19. Aquino A, Gegúndez-Arias ME, Marín D, Detecting the optic disc boundary in digital fundus images using morphological, edge detection, and feature extraction techniques, IEEE transactions on medical imaging, 29, 2010, 1860-1869. DOI: 10.1109/TMI.2010.2053042.
20. Otsu N. A threshold selection method from gray-scale histogram, IEEE Transactions on Systems, Man, and Cybernetics Systems, 8, 1978, 62-66. DOI: 10.1109/TSMC.1979.4310076.
21. Gonzalez RC, Woods RE. Image Segmentation in Digital Image Processing, 2002, 577-581.
22. Duda RO, Hart PE. Use of the Hough transformation to detect lines and curves in pictures, Communications of the ACM, 15, 1972, 11-15. DOI: 10.1145/361237.361242.
23. Kimme C, Ballard D, Sklansky J. Finding circles by an array of accumulators, Communications of the ACM, 18, 1975, 120-122. DOI:10.1145/360666.360677.
24. Gander W, Golub GH, Strebler R. Least square fitting of circles and ellipses, 43, 1994, 558-578.
25. Fitzgibbon A, Pilu M, Fisher RB. Direct least square fitting of ellipses, IEEE Transactions on Pattern Analysis and Machine Intelligence, 21, 1999, 476-480. DOI: 10.1109/34.765658.

Source of Support: Nil, Conflict of Interest: None.

